

## Guidelines

# Perioperative Management Of Antiplatelet And Anticoagulant Therapy In Patients Undergoing Interventional Techniques: 2024 Updated Guidelines From The American Society Of Interventional Pain Physicians (ASIPP)

Laxmaiah Manchikanti, MD, Mahendra Sanapati, MD, Devi Nampiaparampil, MD, Byron J. Schneider, MD, Alexander Bautista, MD, Alan D. Kaye, MD, PhD, Nebojsa Nick Knezevic, MD, PhD, Alaa Abd-Elsayed, MD, Annu Navani, MD, Paul J. Christo, MD, Standiford Helm II, MD, Adam M. Kaye, PharmD, Jay Karri, MD, Vidyasagar Pampati, MSc, Sanjeeva Gupta, MD, Vivekanand A. Manocha, MD, Amol Soin, MD, Mayank Gupta, MD, Sanjay Bakshi, MD, Christopher G. Gharibo, MD, Kenneth D. Candido, MD, Anjum Bux, MD, Anilkumar Vinayakan, MD, Vinayak Belamkar, MD, Scott Stayner, MD, PhD, Sairam Atluri, MD, Sara E. Nashi, MD, Megan K. Applewhite, MD, Chelsi J. Flanagan, DO, Emiliya Rakhmimova, BA, Gerard Limerick, MD, PhD, Kunj G. Patel, MD, Sierra Willeford, DO, and Joshua A. Hirsch, MD

From: American Society of Interventional Pain Physicians

Author Affiliations and any conflicts of interest can be found on pp. S79-S81.

Address Correspondence:  
Laxmaiah Manchikanti, MD  
2831 Lone Oak Road  
Paducah, Kentucky 42003  
E-mail: [drim@thepainmd.com](mailto:drim@thepainmd.com)

Disclaimer: These guidelines are crafted from the most up-to-date evidence and are not intended as rigid treatment mandates. Given the evolving nature of scientific evidence, this document does not aim to establish a definitive “standard of care.” There was no external funding in the preparation of this article.

Free full article:  
[www.painphysicianjournal.com](http://www.painphysicianjournal.com)

**Background:** The frequency of performance of interventional techniques in chronic pain patients receiving anticoagulant and antiplatelet therapy continues to increase. Understanding the importance of continuing chronic anticoagulant therapy, the need for interventional techniques, and determining the duration and discontinuation or temporary suspension of anticoagulation is crucial to avoiding devastating complications, primarily when neuraxial procedures are performed. Anticoagulants and antiplatelets target the clotting system, increasing the bleeding risk. However, discontinuation of anticoagulant or antiplatelet drugs exposes patients to thrombosis risk, which can lead to significant morbidity and mortality, especially in those with coronary artery or cerebrovascular disease. These guidelines summarize the current peer reviewed literature and develop consensus-based guidelines based on the best evidence synthesis for patients receiving anticoagulant and antiplatelet therapy during interventional procedures.

**Study Design:** Review of the literature and development of guidelines based on best evidence synthesis.

**Objectives:** To provide a current and concise appraisal of the literature regarding the assessment of bleeding and thrombosis risk during interventional techniques for patients taking anticoagulant and/or antiplatelet medications.

**Methods:** Development of consensus guidelines based on best evidence synthesis included review of the literature on bleeding risks during interventional pain procedures, practice patterns, and perioperative management of anticoagulant and antiplatelet therapy. A multidisciplinary panel of experts developed methodology, risk stratification based on best evidence synthesis, and management of anticoagulant and antiplatelet therapy. It also included risk of cessation of anticoagulant and antiplatelet therapy based on a multitude of factors. Multiple data sources on bleeding risk, practice patterns, risk of thrombosis, and perioperative management of anticoagulant and antiplatelet therapy were identified. The relevant literature was identified through searches of multiple databases from 1966 through 2023.

In the development of consensus statements and guidelines, we used a modified Delphi technique, which has been described to minimize bias related to group interactions. Panelists without a primary conflict of interest voted on approving specific guideline statements. Each panelist could suggest

edits to the guideline statement wording and could suggest additional qualifying remarks or comments as to the implementation of the guideline in clinical practice to achieve consensus and for inclusion in the final guidelines, each guideline statement required at least 80% agreement among eligible panel members without primary conflict of interest.

**Results:** A total of 34 authors participated in the development of these guidelines. Of these, 29 participated in the voting process. A total of 20 recommendations were developed. Overall, 100% acceptance was obtained for 16 of 20 items. Total items were reduced to 18 with second and third round voting. The final results were 100% acceptance for 16 items (89%). There was disagreement for 2 statements (statements 6 and 7) and recommendations by 3 authors. These remaining 2 items had an acceptance of 94% and 89%. The disagreement and dissent were by Byron J. Schneider, MD, with recommendation that all transforaminals be classified into low risk, whereas Sanjeeva Gupta, MD, desired all transforaminals to be in intermediate risk. The second disagreement was related to Vivekanand A. Manocha, MD, recommending that cervical and thoracic transforaminal to be high risk procedures.

Thus, with appropriate literature review, consensus-based statements were developed for the perioperative management of patients receiving anticoagulants and antiplatelets. These included the following: estimation of the thromboembolic risk, estimation of bleeding risk, and determination of the timing of restarting of anticoagulant or antiplatelet therapy.

Risk stratification was provided classifying the interventional techniques into three categories of low risk, moderate or intermediate risk, and high risk. Further, on multiple occasions in low risk and moderate or intermediate risk categories, recommendations were provided against cessation of anticoagulant or antiplatelet therapy.

**Limitations:** The continued paucity of literature with discordant recommendations.

**Conclusion:** Based on the review of available literature, published clinical guidelines, and recommendations, a multidisciplinary panel of experts presented guidelines in managing interventional techniques in patients on anticoagulant or antiplatelet therapy in the perioperative period. These guidelines provide a comprehensive assessment of classification of risk, appropriate recommendations, and recommendations based on the best available evidence.

**Key words:** Perioperative bleeding, bleeding risk, practice patterns, anticoagulant therapy, antiplatelet therapy, interventional techniques, safety precautions, pain

*Disclaimer: These guidelines are crafted from the most up-to-date evidence and are not intended as rigid treatment mandates. Given the evolving nature of scientific evidence, this document does not aim to establish a definitive "standard of care."*

**Pain Physician 2024; 27:S1-S94**

**SUMMARY OF RECOMMENDATIONS:**

1. The risk of thromboembolic events and associated morbidity and mortality is higher than that of epidural hematoma formation and associated morbidity and mortality with critical management, with the interruption of antiplatelet and anticoagulant therapy preceding interventional techniques, though both risks are significant.

**Evidence Level: Moderate; Strength of Recommendation: Moderate**

2. Risk stratification categorized multiple interventional techniques into low-risk, moderate or intermediate risk, and high-risk.

**Evidence Level: Low to moderate; Strength of Recommendation: Moderate to strong**

3. Risk stratification of patients undergoing interventional techniques on antiplatelet or anticoagulant therapy based on anatomical risk factors, procedural risk factors, bleeding risk factors, anticoagulant risk factors, and medical or physiological status provide a physiologic and clinically appropriate basis in developing the developing the guidelines.

**Evidence Level: Moderate; Strength of Recommendation: Moderate**

4. Risk factors with severe degenerative arthritis with or without spinal stenosis, ankylosing spondylitis, osteoporosis, older age, frailty, previous stroke, intracranial bleed, hypertension, diabetes, thrombocytopenia, chronic renal failure, chronic NSAID or steroid therapy, multiple attempts, epidural fibrosis, and previous surgery may increase bleeding observed during the procedure and risk of epidural hematoma.

**Evidence Level: Moderate; Strength of Recommendation: Moderate**

5. Risk stratification should be upgraded to low to moderate or intermediate and moderate or intermediate to high based on other risk factors.

**Evidence Level: Low; Strength of Recommendation: Low to Moderate**

6. All procedures categorized as high-risk include:

- a. Cervical, thoracic, and lumbar (above L5) interlaminar epidurals
- b. Trigeminal ganglion, ophthalmic division, and sphenopalatine ganglion blocks
- c. Peripheral nerve stimulation trial and implantation of throacic and cervical medial branches.
- d. Discography and intradiscal procedures (lumbosacral, cervical, and thoracic)
- e. Dorsal column and dorsal root ganglion stimulator trial and implantation
- f. Intrathecal catheter and pump implant
- g. Vertebral augmentation (sacral, lumbar, thoracic, and cervical)
- h. Percutaneous and endoscopic disc decompression procedures
- i. Minimally invasive lumbar decompression (MILD)
- j. Trigeminal and cranial nerve blocks and stimulation
- k. Sympathetic blocks (stellate ganglion, thoracic sympathetic, splanchnic, celiac plexus, lumbar sympathetic, hypogastric plexus)
- l. Percutaneous adhesiolysis with interlaminar or transforaminal approach (cervical, thoracic, and lumbar)
- m. Intervertebral spinous prosthesis including lateral fusion
- n. Sacroiliac joint fusion
- o. Intracept procedure

**Evidence Level: Moderate; Strength of Recommendation: Moderate**

7. Procedures categorized as moderate or intermediate-risk include:
- a. Caudal epidural injections\*
  - b. Caudal epidural adhesiolysis\*
  - c. Lumbar interlaminar epidural injection at L5, S1
  - d. Cervical, thoracic, and lumbar transforaminal at L1 and L2
  - e. Peripheral nerve stimulation trial and implantation of lumbar medial branches

**Evidence Level: Moderate; Strength of Recommendation: Moderate**

8. Procedures categorized as low-risk include:
- a. Trigger point and intramuscular injections (including piriformis injection)
  - b. Peripheral nerve blocks including mandibular and maxillary nerve blocks
  - c. Sacroiliac joint and ligament injections and nerve blocks
  - d. Facet joint interventions (intra-articular injections, medial branch and L5 dorsal ramus nerve blocks and radiofrequency neurotomy)
  - e. Intraarticular injections of extremity joints
  - f. Pocket revision and implantable pulse generator/intrathecal pump replacement
  - g. Peripheral nerve stimulation trial and implantation
  - h. Lumbar transforaminal epidural injections at L3, L4, L5, and S1
  - i. Ganglion impar blocks
  - j. Sacroiliac joint nerve radiofrequency
  - k. Trigeminal branch nerve blocks (mandibular, maxillary, and other branches)

**Evidence Level: Moderate; Strength of Recommendation: Moderate**

9. Discontinuation of aspirin (81 or 325 mg) for 6 days for high-risk procedures. The clinician may choose to continue aspirin (81 or 325 mg) without interruption for low and moderate or intermediate risk procedures or discontinue (81 or 325 mg) for 3 days. Similarly, additional factors may increase the risk and necessitate change in the guidance for low and moderate or intermediate risk patients.

**Evidence Level: Moderate; Strength of Recommendation: Moderate**

10. Discontinuation of most NSAIDs, excluding aspirin, for 1 to 2 days and some 4 to 10 days may be considered of moderate and high-risk procedures.

**Evidence Level: Low; Strength of Recommendation: Weak**

11. In patients on anticoagulant therapy with Warfarin, low risk procedures may be performed with INR of  $\leq 3.0$  with 1 to 2 days of cessation if warranted, for moderate or intermediate risk procedures an INR of  $\leq 2.0$  is recommended with 2 to 3 days of cessation of Warfarin therapy if warranted, and for high-risk procedures an INR of  $< 1.5$  is recommended with cessation of Warfarin therapy for 3 to 5 days if warranted.

**Evidence Level: Moderate; Strength of Recommendation: Moderate**

12. Anticoagulant therapy with direct acting anticoagulants dabigatran (Pradaxa), apixaban (Eliquis), rivaroxaban (Xarelto), and Edoxaban (Savaysa, Lixiana) is discontinued for 2 days for high-risk procedures and one day for moderate or intermediate risk procedures. Discontinuation is adjusted to 2 days and 3-4 days for dabigatran (Pradaxa) with creatinine clearance below 50 mL/minute. For low-risk procedures; direct acting oral coagulants may be continued. Based on clinical condition and importance, a shared decision may be made to continue for moderate or intermediate risk procedures with normal renal function.

---

\* Change from 2019 guidelines

**Evidence Level: Moderate; Strength of Recommendation: Moderate**

13. Antiplatelet agents such as dipyridamole, cilostazol, and Aggrenox (dipyridamole plus aspirin) may be continued for low and moderate or intermediate risk procedures. For high-risk procedures dipyridamole and cilostazol may be continued or stopped for 2 days with Aggrenox (dipyridamole plus aspirin) to be stopped for 6 days.

**Evidence Level: Low; Strength of Recommendation: Moderate**

14. Antiplatelet therapy with clopidogrel (Plavix) and prasugrel (Effient) are discontinued for 6 days for high-risk procedures and intermediate or moderate risk procedures. They are continued in low-risk procedures. Ticagrelor (Brilinta) is discontinued for 5 days in high risk. Ticlopidine (Ticlid) (discontinued in the U.S.) is discontinued for 7 days for high and moderate or intermediate risk procedures and 3 days in moderate risk procedures and may be continued in low-risk procedures.

**Evidence Level: Moderate; Strength of Recommendation: Moderate**

15. Timing of therapy of restoration or restarting is recommended during 12 to 24-hour period for moderate or intermediate risk procedures, and low risk procedures if the decision was made to hold based on risk factors, and 24-48 hours for major risk procedures, based on postoperative bleeding status. If thromboembolic risk is high, antithrombotic therapy may be resumed 12 hours after the interventional procedure is performed, with appropriate assessment and monitoring for clinically significant bleeding.

**Evidence Level: Low; Strength of Recommendation: Moderate**

16. Diagnosis of epidural hematoma is clinically based on unexpected pain at the site of the injection with rapid neurological deterioration and MRI confirmation. Neurosurgical consult is necessary to avoid neurological sequelae.

**Evidence Level: Moderate; Strength of Recommendation: Moderate**

17. If thromboembolic risk is high, low molecular weight heparin bridge therapy can be instituted during cessation of the anticoagulant, and the low molecular weight heparin can be discontinued 24 hours before the pain procedure.

**Evidence Level: Low; Strength of Recommendation: Weak**

18. Shared decision making between the patient, the pain specialist, and the treating physicians if cessation is contemplated is recommended for consideration of all the appropriate risks associated with continuation or discontinuation of antiplatelet or anticoagulant therapy.

**Evidence Level: Moderate; Strength of Recommendation: High**

◆	<b>1.0 Introduction</b>	<b>S8</b>
◆	<b>2.0 Methods</b>	<b>S11</b>
	2.1 Rationale	
	2.2 Objectives	
	2.2.1 Application	
	2.3 Recommendations of Perioperative Anticoagulant and Antiplatelet Therapy	
	2.4 Adherence to Trustworthy Standards	
	2.5 Disclosure of Guideline Funding Source	
	2.6 Disclosure and Management of Financial Conflicts of Interests	
	2.7 Composition of Guideline Development Group	
	2.8 Evidence Review	
	2.9 Grading or Rating the Quality or Strength of Evidence	
	2.10 Assessment and Recommendations of Benefits and Harms	
	2.11 Evidence Summary of Recommendations	
	2.12 Rating or Grading the Strength of Recommendations	
	2.13 Specificity of Recommendations	
	2.14 External Review	
	2.15 Updating Anticoagulant and Antiplatelet Therapy Guidelines	
	2.16 Consensus Development of Recommendations	
◆	<b>3.0 Results</b>	<b>S15</b>
	3.1 Prevalence and Risk Assessment Studies of Thrombosis and Bleeding	
◆	<b>4.0 Pharmacologic Aspects and Hemostasis Monitoring</b>	<b>S31</b>
	4.1 Antithrombotics	
	4.1.1 NSAIDs and Aspirin	
	4.1.2 Adenosine diphosphate (ADP) Receptor Inhibitors	
	4.1.3 Phosphodiesterase Inhibitors	
	4.1.4 Glycoprotein GPIIb/IIIa Inhibitors	
	4.2 Direct Oral Anticoagulants (DOACs)	
	4.3 Warfarin	
	4.4 Low-Molecular Weight Heparin	
	4.5 Herbal/Alternative Therapies	
	4.5.1 Herbal Products	
	4.5.2 Fish Oil	
	4.5.3 Vitamins	
	4.5.4 Selective Serotonin Reuptake Inhibitors (SSRIs)	
	4.6 Hemostasis Monitoring	
	4.7 Reversal of Antiplatelet and Anticoagulant Agents	
	4.7.1 Specific Reversal Agents	
	4.7.2 Nonspecific Reversal Agents	
◆	<b>5.0 Guidelines and Recommendations</b>	<b>S39</b>
	5.1 Risks of Continuation and Cessation in Perioperative Period	
	5.2 Risk Factors	
	5.2.1 Patient Factors	
	5.2.1.1 Anatomical Considerations	
	5.2.1.2 Age	
	5.2.1.3 Obesity	
	5.2.1.4 Hypertension	
	5.2.1.5 Diabetes	
	5.2.1.6 Risk of Thromboembolism	
	5.2.2 Drug-Related Factors	
	5.3 Antithrombotics	
	5.3.1 NSAIDs and Aspirin	
	5.3.2 ADP Receptor Inhibitors	
	5.3.3 Phosphodiesterase Inhibitors	
	5.3.4 Direct Oral Anticoagulants (DOACs)	
	5.3.5 Warfarin	
	5.3.6 Low-Molecular Weight Heparin	
	5.3.7 Selective Serotonin Reuptake Inhibitors (SSRIs)	
	5.4 Procedural Factors	
	5.4.1 Epidural Interventions	
	5.4.1.1 Cervical Epidural Injections	
	5.4.1.2 Thoracic Epidural Injections	
	5.4.1.3 Lumbar Epidural Injections	

5.4.2	Percutaneous Adhesiolysis	
5.4.3	Spinal Cord Stimulation Interventions	
5.4.4	Non-Epidural Spinal and Other Interventions	
5.5	Risk Stratification of Interventional Techniques	
5.6	Perioperative Management	
5.6.1	Estimation of Thromboembolic and Bleeding Risk	
5.6.2	Determination of Timing of Anticoagulant Interruption	
5.6.2.1	Bridge Therapy	
5.6.3	Post-Procedure Resumption of Antiplatelet and Anticoagulant Therapy	
◆	<b>6.0 Guidelines for Managing Anticoagulant and Antiplatelet Therapy During Interventional Techniques</b>	<b>S71</b>
◆	<b>7.0 Recommendations and Statements</b>	<b>S76</b>
◆	<b>8.0 Conclusion</b>	<b>S78</b>

## 1.0 INTRODUCTION

Chronic pain management using interventional techniques in patients receiving anticoagulant and antiplatelet therapy is increasingly common (1-9). The frequency of these combinations continues to rise, necessitating a multidisciplinary approach to understand the importance of anticoagulant therapy and the need for interventional techniques and to determine the duration and discontinuation or temporary interruption of anticoagulation (1-41). Anticoagulants and antiplatelets are commonly prescribed to reduce the risk of thromboembolism in patients with a history of angina, atherosclerosis, atrial fibrillation, cerebrovascular accidents, ischemic heart disease (IHD), myocardial infarction, pulmonary embolism, and peripheral vascular disease, thereby preventing the incidence of life-threatening events (15-39). While the growth of some interventional techniques continues to show reversal of escalating growth patterns (3-9), major procedures such as spinal cord stimulator implants, and insertion of intrathecal implantables continue to increase (8). Interventional pain physicians are also performing multiple other procedures with increasing frequency, including endoscopic disc decompression, spinal canal decompressions with minimally invasive approaches, and vertebral augmentation procedures. The importance of anticoagulant and antiplatelet therapy has been demonstrated overwhelmingly (10-13,15-19,22-39,42-48). Thus, the long-term oral anticoagulation therapy represents an effective treatment for preventing myocardial infarction and stroke despite reports of stroke in some anticoagulated patients (19,46-48).

Among the multiple therapeutic options reported, continuation of oral anticoagulant therapy, switching to another oral anticoagulant, adding antiplatelet therapy, performing left atrial appendage closure or a combination of the above strategies have been recommended (49). Thus, the best option an interventional pain physician may provide to their patients is continuation of oral anticoagulant therapy and performing safer procedures without entering closed spaces, resulting in serious complications and surgical interventions.

Discontinuation of antiplatelet therapy and anticoagulant therapy is common in patients undergoing interventional techniques, based on a survey of common practices by a majority of interventional pain physicians (50). The results of this survey showed discontinuation rate of warfarin (Coumadin®) therapy 100%, clopidogrel (Plavix®) 97%, ticlopidine (Ticlid®) 96%, tirofiban (Aggrastat®) 95%, cilostazol (Pletal®)

93%, dipyridamole (Persantine®) 85%, aspirin 350 mg 60%, aspirin 81 mg 39%, and other nonsteroidal anti-inflammatory drugs (NSAIDs) 39% prior to performing interventional pain management. An international normalized ratio (INR) of 1.5 or less was accepted by the majority of physicians before performing neuraxial procedures. Another study was performed in 2012 by the American Society of Regional Anesthesia and Pain Medicine (ASRA), the results showing 55% stopped aspirin before spinal cord stimulation trials and implants, and 32% stopped before epidural steroid injections (14). Additionally, only 36% of physicians were found to be aware that selective serotonin reuptake inhibitors (SSRIs) may contribute to bleeding in the perioperative period. Furthermore, 17% of physicians utilized different protocols when performing cervical spine injections as compared with performing lumbar spine injections, whereas 88% of physicians also expressed the need for pain physicians to communicate with other physicians (14).

An updated evaluation of use of antiplatelet and anticoagulant therapy in interventional pain management techniques in 2021 showed that 23% changed their practice patterns (51). The results were somewhat similar to the previous study in that all physicians discontinued warfarin (Coumadin) therapy with the majority of physicians accepting an INR of 1.5 as a safe level. Low dose aspirin (81 mg) was discontinued for 3-7 days by 76% of physicians for high-risk procedures with discontinuation of high doses aspirin (325 mg) at a higher rate. Platelet aggregation inhibitors clopidogrel (Plavix), prasugrel (Effient®), ticlopidine (Ticlid) and ticagrelor (Brilinta®) were discontinued for 3-5 days by 97% for high-risk procedures (51). The thrombin inhibitor dabigatran (Pradaxa®) was discontinued by 92% for moderate or intermediate-risk procedures and 99% for high-risk procedures. Anti Xa agents, apixaban (Eliquis®), rivaroxaban (Xarelto®), and Edoxaban (Savaysa®, Lixiana®) were discontinued in 99% for high-risk procedures and 90% for moderate risk procedures, but 25% for low-risk procedures.

Further complicated issues are related to a known possible development of spontaneous spinal hematoma in patients using antiplatelets and anticoagulants (40). In a systematic review, Kumar et al (40) showed that the prevalence of idiopathic, non-traumatic spontaneous spinal hematoma with concomitant anticoagulation treatment was higher with 74% compared to antiplatelet therapy (27%). The lumbar spine was the most common site of hematoma formation (41.7%),



followed by the cervical spine (21.01%), and thoracic spine (8.49%). Most patients (70%) had surgery and 30% had conservative management. In contrast, hematoma formation secondary to epidural procedures, occurs more commonly in the lumbar spine instead of the cervical spine (1,14,20,52-85).

Lagerkranser et al (81,82) published reports on neural blocks and spinal hematoma with review of 166 case reports. They identified 21 cases of hematoma from epidural injections with 17 after steroid injections, 5 in the cervical, 4 in the thoracic, and 8 in the lumbar spine. They also identified 4 cases of epidural hematoma formation after percutaneous application of spinal cord stimulator leads. They showed that the prevalence of hematoma in patients not on antithrombotic therapy was 37%.

Manchikanti et al (52) in a comprehensive assessment of the prevalence of hematomas in patients undergoing interventional techniques on anticoagulant and antiplatelet therapy showed the incidence of epidural hematoma to be the highest in the cervical spine with 24, followed by 18 in the lumbar spine and 15 in the thoracic spine. However, 30 of these patients were not on antiplatelet therapy, 15 patients had their antithrombotic therapy discontinued, and 12 continued antithrombotic therapy. It is interesting to note that the majority of the epidural procedures are performed in the lumbar spine, followed by the cervical spine, which is only one-third of the lumbar spine, and minimally in the thoracic spine. Consequently, the ratios shown here do not represent the actual prevalence.

Douketis et al (10,11) have concluded that substantial new evidence has emerged since the 2012 iteration of perioperative management of antithrombotic therapy guidelines developed by the American College of Chest Physicians (CHEST). They concluded that the new evidence is crucial in informing best practices for the perioperative management of patients who are receiving a vitamin K antagonist and may require heparin bridging, for the perioperative management of patients who are receiving a direct oral anticoagulant (DOAC), and for patients who are receiving one or more antiplatelet drugs. However, despite this new knowledge, uncertainty remains as to best practices for the majority of perioperative management questions. The CHEST clinical practice guideline (10) provided 44 guideline recommendations for the perioperative management of vitamin K antagonists, heparin bridging, DOACs, and antiplatelet drugs, of which 2 were strong recommendations. The strong recommendations were

against the use of heparin bridging in patients with atrial fibrillation and continuation of vitamin K antagonist therapy in patients having a pacemaker or internal cardiac defibrillator implantation. They also provided separate recommendations on the perioperative management of patients who are undergoing minor procedures, comprising dental, dermatologic, ophthalmic, pacemaker/internal cardiac defibrillator implantation, and gastrointestinal endoscopic procedures.

Bailey et al (12) published the 2024 Canadian Cardiovascular Society/Canadian Association of Interventional Cardiology Focused Update of the Guidelines for the Use of Antiplatelet Therapy. They updated the guidelines in reference to the use of acetylsalicylic acid (ASA or aspirin) in primary prevention of atherosclerotic cardiovascular disease, dual antiplatelet therapy (DAPT), duration after percutaneous coronary interventions in patients at high bleeding risk, potent DAPT (P2Y2 inhibitor) choice in patients who present with an acute coronary syndrome and possible DAPT de-escalation strategies after percutaneous coronary intervention; and use of antiplatelet therapy in patients with atrial fibrillation who require anticoagulation after percutaneous coronary intervention or medically managed acute coronary syndrome.

Valgimigli et al (13) from the Task Force for Dual Antiplatelet Therapy in Coronary Artery Disease of the European Society of Cardiology (ESC) and of the European Association for Cardio-Thoracic Surgery (EACTS), provided the 2017 ESC focused update on antiplatelet therapy in coronary artery disease. The estimated number of patients requiring DAPT consisting of the combination of aspirin and an oral inhibitor of the platelet P2Y12 receptor for adenosine-5'-diphosphate (ADP), is considerable and has increased over time across the globe.

In reference to interventional pain management techniques, the anticoagulant and antiplatelet guidelines, 2nd edition, were published by ASRA and other societies in interventional spine and pain procedures in 2018 (14). Subsequently, the American Society of Interventional Pain Physicians (ASIPP) published the guidelines in 2019 (1). ASIPP guidelines were also updated for interventional techniques with the development of epidural procedure guidelines published in 2021 (52), interventional techniques guidance in 2024 (53), and facet joint interventions guidelines published in 2020 (54). These guidelines are principally derived from clinical case reports and by consensus. These guidelines provided options to continue or stop based on proce-

dural risk. As an example, the latest ASIPP guidelines changed the risk classification and also provided opportunity to perform caudal epidural injections, facet joint interventions, and transforaminal epidural injections with continuation of antiplatelet and anticoagulant therapy and a higher INR of less than 3 for low-risk procedures and less than 2 for moderate or intermediate risk procedures (52-54). Multiple prevalence and risk assessment studies have been published over the years (55-61).

Despite the available evidence of the safety, a large subset of clinicians report stopping antiplatelet therapy based on these guidelines and consider this concept as a standard of care (1,14,50,51). Although the overall incidence of bleeding complications and epidural hematoma in the non-obstetric epidural literature has been reduced, the incidence has been higher with procedures involving the cervical and thoracic spine with continuation, discontinuation, or lack of use of anticoagulant or antiplatelet therapy (1,2,50,52-57,65-98). Consequently, withholding antiplatelet or anticoagulant therapy is associated with significant risks of cardiovascular, cerebrovascular, and peripheral vascular thrombosis. In addition, chronic psychosocial stress causes a hypercoagulable state; therefore, these thrombotic risks are heightened in chronic pain patients, who have anxiety about the cessation of anticoagulant and antiplatelet therapy, as well as other associated stress and anxiety. The hypercoagulable state induced by chronic psychosocial stress is reflected by increased procoagulant molecular fibrinogen (or coagulation factor 7), reduced fibrinolytic capacity and increased platelet activity

(14,99-102). Stress affects coagulation activity through influence on the regulation of genes coding for coagulation and fibrinolysis molecules (1,2,14,102-105) with increase in hormonal levels.

In fact, the available evidence in reference to thromboembolic and cardiovascular complications related to discontinuation of antiplatelet or anticoagulant therapy (50,55,56,58,62,68) is very concerning. Manchikanti et al (50), based on a mail in survey, reported 162 thromboembolic complications compared to 55 reports of epidural hematoma. An epidural hematoma with appropriate follow-up and management, including surgical decompression, can be managed with moderate morbidity and mortality. In contrast, cerebrovascular or cardiovascular complications may be devastating and irreversible in the majority of the cases with best of the treatment. Other reports (56,59,62) also reported similar complications including deaths, stroke, pulmonary embolism, myocardial infarction (56), right middle cerebral infarction with persistent left hemiparesis and dysarthria (62), and one report with pulmonary embolism (59).

ASIPP has developed multiple guidelines for both interventional techniques and opioids (1,2,52,54,106). Consequently, the present guideline development serves the purpose of updating antiplatelet and anticoagulant therapy guidelines for patients undergoing interventional techniques.

The aim of this practice guideline is to provide evidence-based, consensus, recommendations for the perioperative management of patients undergoing interventional techniques and receiving antiplatelet and/or anticoagulant therapy.

## 2.0 METHODS

### 2.1 Rationale

Pain is a complex phenomenon influenced by multiple biological, psychological, and social factors (52,54,106-111). There is substantial variability in the effectiveness of different treatments for pain, largely depending on the type of pain and the condition being treated. Chronic pain is often ineffectively managed for a variety of reasons, including clinician training, patient access, and socio-economic and organizational barriers to care (106-110,112).

Interventional pain management techniques have been used to reduce pain and disability. Since anticoagulant and antiplatelet therapy is commonly used in patients who also have chronic pain, it is crucial to understand the importance of each modality and subsequent influence on outcomes with strategies to minimally interrupt anticoagulant and antiplatelet therapy. As illustrated in the Introduction section, bleeding complications, specifically epidural hematoma, can occur spontaneously without concurrent anticoagulant or antiplatelet therapy and with interruption or continuation of anticoagulant and antiplatelet therapy. Thus, our rationale revolves around the fact that interventional techniques, as well as antithrombotic therapy, are highly prevalent in these vulnerable patients suffering with chronic pain and disability. It is essential to recommend safer approaches considering the overall safety and outcomes (112).

The National Uniform Claims Committee (NUCC) defined interventional pain management as, “the discipline of medicine devoted to the diagnosis and treatment of pain related disorders principally with the application of interventional techniques in managing subacute, chronic, persistent, and intractable pain, independently or in conjunction with other modalities of treatment” (113).

The Medicare Payment Advisory Commission (MedPAC) defined interventional pain management techniques as, “minimally invasive procedures including, percutaneous precision needle placement, with placement of drugs in targeted areas or ablation of targeted nerves; and some surgical techniques such as laser or endoscopic discectomy, intrathecal infusion pumps and spinal cord stimulators, for the diagnosis and management of chronic, persistent or intractable pain” (114).

Multiple guidelines have been developed by various organizations to be applied in the perioperative period for patients receiving anticoagulant and anti-

platelet therapy (1,2,14). However, the specific guidance for interventional techniques and anticoagulant therapy is often limited. Since the publication of the ASIPP guidelines for antiplatelets and anticoagulants in patients undergoing interventional techniques in 2019 (1), ASIPP has updated guidelines for epidural interventions in 2021 (52) and facet joint interventions in 2020 (54) with updating of antiplatelet and anticoagulant therapy. However, no other guidance has been published.

### 2.2 Objectives

The objectives of these guidelines are to synthesize available evidence on the effectiveness and safety of continuing or discontinuing antiplatelet and anticoagulant therapy in perioperative period and describe adverse events of anticoagulant therapy and bleeding complications in the perioperative period. Thus, the focus of these practice guidelines is to provide evidence-based consensus recommendations for the perioperative management of patients undergoing interventional techniques and receiving antiplatelet and/or anticoagulant therapy. Consequently, these guidelines are designed to estimate thromboembolic risk, estimate bleeding risk, determine the timing of anticoagulant cessation and whether to use bridging anticoagulation.

#### 2.2.1 Application

While these guidelines may be applied by any specialty, they are specifically intended for use by interventional pain physicians. These guidelines do not constitute inflexible treatment recommendations. It is expected that a clinician will establish a plan of care on a case-by-case basis, considering an individual patient's medical conditions, personal needs, preferences, and the physician's experience. Based on an individual patient's needs, treatment different from that outlined here could be warranted. Consequently, these guidelines do not represent a “standard of care.” It is a well-known fact that all treatments are not supported by existing evidence and grading. However, there may be strong clinical support for some interventions.

### 2.3 Recommendations of Perioperative Anticoagulant and Antiplatelet Therapy

The guidelines committee was tasked with assessment and development of recommendations as follows:

1. The thromboembolic risk of the patient
2. The bleeding risk of the patient

- The bleeding risk related to the interventional procedure (anatomical and technical aspects)
  - The pharmacological profile with consideration of elimination half-life, renal function, liver function, and co-medication
3. Timing of stopping anticoagulant and/or antiplatelet therapy before an interventional procedure
  4. The role of bridging therapy
  5. Resumption of anticoagulant or antiplatelet therapy after an interventional technique or surgery.

#### **2.4 Adherence to Trustworthy Standards**

The Institute of Medicine (IOM) standards (115) and the National Guideline Clearinghouse Extent Adherence to Trustworthy Standards (NEATS) instrument were followed in the preparation of these guidelines (116). The NEATS instrument was developed and tested as a tool to be used by trained staff at the Agency for Healthcare Research and Quality (AHRQ) National Guideline Clearinghouse to provide assessments focused on adherence. The NEATS instrument developed and validated standards containing 15 items which were utilized in the preparation of the present guidelines.

#### **2.5 Disclosure of Guideline Funding Source**

The guidelines for anticoagulant and antiplatelet therapy were commissioned, prepared, edited, and endorsed by ASIPP without external funding sought or obtained. The guideline preparation committee and the writing of the guidelines were financially supported entirely by ASIPP and developed without any industry support.

#### **2.6 Disclosure and Management of Financial Conflicts of Interests**

Potential conflicts of interest for all panel members within the last 5 years were compiled and distributed at the introductory panel meeting. Following review and discussion of these disclosures, the panel concluded that individuals with potential conflicts could remain on the panel. However, the panel members with potential conflicts were instructed by the panel and recused from related discussion or preparation of the guidelines, and these members agreed not to discuss any aspect of the guidelines with industry before data publication. Furthermore, conflicts of interests were included based on interest confluence extending beyond financial relationships, including personal experience, practice patterns, academic interests, and promotions.

All the panel members were connected through emails, and discussions and reviews were also performed through electronic communication. The discussions were carried out at multiple ASIPP related meetings; however, there were no specific travel arrangements made, there was no remuneration provided to the participants.

Disclosures and competing interests are described at the end of the manuscript.

#### **2.7 Composition of Guideline Development Group**

A multidisciplinary panel of experts in various medical and pharmaceutical fields, convened by the ASIPP, reviewed the evidence, considered patient perspectives, and formulated recommendations for anticoagulant and antiplatelet therapy. The panel, consisting of authors and committee members, has been instructed to assess the evidence pertaining to important aspects of anticoagulant and antiplatelet therapy. The panel members convened either in person or through e-seminars and telephone conferences.

The panel provided a broad representation of academic and non-academic clinical practitioners, scientists, and ethicists representing a variety of specialties, disciplines, practices, and geographic areas, all with interest and expertise in anticoagulant and antiplatelet therapy.

The multidisciplinary panel composition included methodologists (e.g., epidemiologists, statisticians, ethicists, and health services researchers) with experience in research and conduct of systematic reviews.

Editorially, appropriate measures were taken to avoid any conflicting opinions from authors receiving funding from the industry. The panel was multidisciplinary with academicians and practitioners, and geographically diverse. Of the 34 members involved in preparing the guidelines, there were the 20 anesthesiologists, 7 physiatrists, 1 radiologist, 1 psychiatrist, 1 general surgeon, 3 scientists/researchers, 2 ethicists, 1 pharmacist, 1 medical student, and 2 statisticians, either in an academic setting or in private practice. All of them were involved in managing or researching chronic non-cancer pain.

#### **2.8 Evidence Review**

These guidelines were updated by using evidence review, incorporating guidelines by other organizations and agencies, and achieving consensus among the panel members. During that process, the panel reviewed published randomized controlled trials which

were not included in systematic reviews, meta-analyses, narrative reviews, and clinical practice guidelines concerning the safety of antiplatelet and anticoagulant therapy in perioperative period.

The panel reviewed all the available literature including recently developed guidelines on the safety and risks of anticoagulant therapy.

Various search strategies were employed, utilizing databases such as PubMed, Cochrane Library, and Google Scholar. These strategies targeted keywords related to antithrombotic medications, anticoagulants, antiplatelet agents, thrombotic events, cardiovascular events, cerebrovascular events, interventional techniques, bleeding complications, and epidural hematoma following interventional procedures. Additionally, relevant articles were identified through a review of the latest guidelines.

Search criteria used for PubMed was spinal AND hematoma AND (NOAC OR ASA OR Aspirin OR rivaroxaban OR warfarin OR apixaban OR ticagrelor OR P2Y12 OR clopidogrel OR Xarelto OR dabigatran OR Pradaxa or Eliquis or Edoxaban or Lixiana OR antiplatelet OR anticoagulant OR steroid injection OR epidural

anesthesia OR spinal cord stimulator OR nerve-root injection OR implant OR sympathetic OR Epidural steroid OR pain procedure) Filters: Humans

### 2.9 Grading or Rating the Quality or Strength of Evidence

The grading of evidence and recommendation were based on qualitative modified approach to grading of evidence described by ASIPP (117), the Grading of Recommendations Assessment, Development, and Evaluation (GRADE) method (118-121), clinical relevance and pragmatism (122), and AHRQ strength of recommendations (116).

Table 1 shows a guide for strength of recommendations as developed by the NEATS instrument (116), and as modified by the guideline panel.

### 2.10 Assessment and Recommendations of Benefits and Harms

The guidelines intend to clearly describe the potential benefits and harms for the interventions and explicitly tie the information to specific recommendations.

Table 1. Guide for strength of recommendations as modified for ASIPP guidelines.

Rating for Strength of Recommendation	
Strong	<p>There is high confidence that the recommendation reflects best practice. This is based on: a) strong evidence for a true net effect (e.g., benefits exceed harms); b) consistent results, with no or minor exceptions; c) minor or no concerns about study quality; and/or d) the extent of the panelists' agreement. Other compelling considerations (discussed in the guideline's literature review and analyses) may also warrant a strong recommendation.</p> <p>ASIPP Adaptation: Consensus was achieved that there is high certainty that the net benefit is substantial providing strong recommendation.</p> <p>Recommendation: Strong</p>
Moderate	<p>There is moderate confidence that the recommendation reflects best practice. This is based on: a) good evidence for a true net effect (e.g., benefits exceed harms); b) consistent results, with minor and/or few exceptions; c) minor and/or few concerns about study quality; and/or d) the extent of panelists' agreement. Other compelling considerations (discussed in the guideline's literature review and analyses) may also warrant a moderate recommendation.</p> <p>ASIPP Adaptation: Consensus was achieved that there is high certainty that the net benefit is moderate or there is moderate certainty that the net benefit is moderate to substantial.</p> <p>Recommendation: Moderate to strong</p>
Weak	<p>There is some confidence that the recommendation offers the best current guidance for practice. This is based on: a) limited evidence for a true net effect (e.g., benefits exceed harms); b) consistent results, but with important exceptions; c) concerns about study quality; and/or d) the extent of panelists' agreement. Other considerations (discussed in the guideline's literature review and analyses) may also warrant a weak recommendation.</p> <p>ASIPP Adaptation: The consensus achieved that there is potential improvement in certain individuals or groups of patients based on individual professional judgment and shared decision making.</p> <p>Recommendation: Weak to moderate</p>

Adapted and modified from: National Guideline Clearinghouse Extent Adherence to Trustworthy Standards (NEATS) instrument (116).

### **2.11 Evidence Summary of Recommendations**

Documents accompanying the guidelines summarize the relevant supporting evidence and explicitly tie this information to recommendations.

### **2.12 Rating or Grading the Strength of Recommendations**

IOM standards demand that for each recommendation, a rating of the strength of the recommendation considering benefits and harms, available evidence, and confidence in the underlying evidence should be provided. In preparation of these guidelines, the rating schemes recommended by NEATS were utilized as modified by the ASIPP panel, as shown in Table 1 (116).

### **2.13 Specificity of Recommendations**

Guideline recommendations are, to the largest extent possible, specific, and unambiguous, providing guidance on what actions should or should not be taken in various situations of anticoagulant and antiplatelet therapy among diverse populations.

### **2.14 External Review**

These guidelines have been subjected to external peer review as per the policies of the publishing journal, *Pain Physician*. In addition, the guidelines have also been published on ASIPP's website and in their newsletter for comments from stakeholders, scientific and clinical

experts, organizations, patients, and representation of the public.

### **2.15 Updating Anticoagulant and Antiplatelet Therapy Guidelines**

Anticoagulant and antiplatelet therapy guidelines will be updated in a window of 5 years, based on significant changes in the evidence, public policy, or adverse events by 2028.

### **2.16 Consensus Development of Recommendations**

We used a modified Delphi technique to achieve consensus on guideline statements (10,123). This method has been described to minimize bias related to group interactions and enable anonymity among panelists. Panelists without a primary conflict of interest voted on approving specific guideline statements using an online survey. Each panelist could also suggest edits to the guideline statement wording and could suggest additional qualifying remarks or comments as to the implementation of the guideline in clinical practice. To achieve consensus and for inclusion in the final guidelines, each guideline statement required at least 80% agreement among eligible panel members without primary conflict of interest. If there were any disagreements, with guideline statements with some members disagreeing with either the strength or direction of the recommendation.

### 3.0 RESULTS

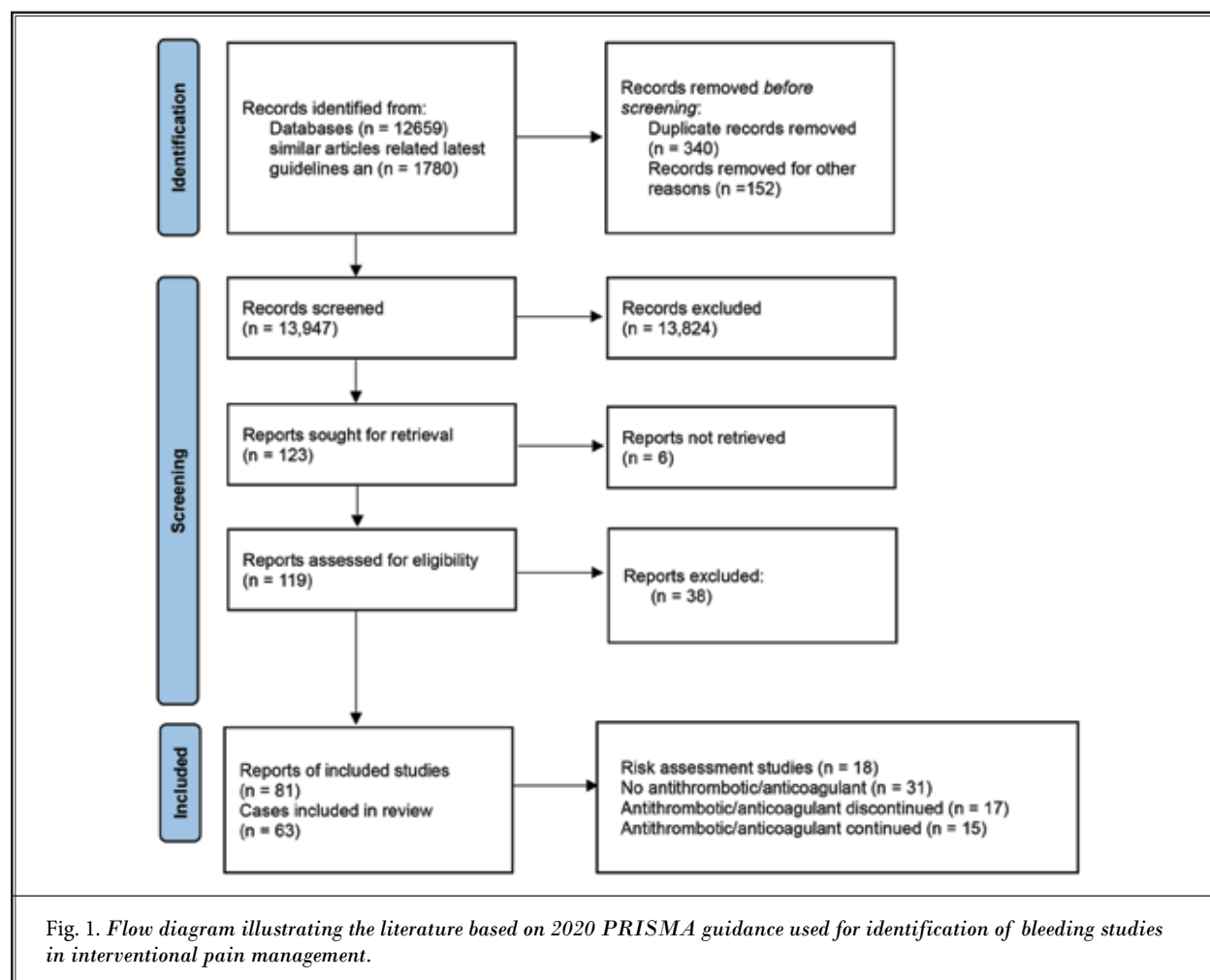
Our search strategy utilizing the Preferred Reporting Items for Systematic Reviews and Meta-Analyses (PRISMA) flow diagram as shown in Fig. 1. illustrated published literature evaluating interventional techniques performed with or without antiplatelet and anticoagulant therapy. We identified 119 relevant publications. Of those, 80 articles of bleeding complications met the criteria for inclusion as shown in Fig. 1. Due to very few studies with persistent high variability, conventional meta-analysis or single-arm meta-analysis was feasible.

A total of 34 authors participated in the development of these guidelines. Of these, 29 participated in the voting process. A total of 20 recommendations were developed. Overall, 100% acceptance was obtained for 16 of 20 items. Total items were reduced to 18 with second and third round voting. The final re-

sults were 100% acceptance for 16 items (89%). There was disagreement for 2 statements (statements 6 and 7) and recommendations by 3 authors. These remaining 2 items had an acceptance of 94% and 89%. The disagreement and dissent were by Byron J. Schneider, MD, with recommendation that all transforaminals be classified into low risk, whereas Sanjeeva Gupta, MD, desired all transforaminals to be in intermediate risk. The second disagreement was related to Vivekanand A. Manocha, MD, recommending that cervical and thoracic transforaminal to be high risk procedures.

### 3.1 Prevalence and Risk Assessment Studies of Thrombosis and Bleeding

Multiple reports have been published assessing the prevalence, as well as the risk of thrombosis and bleeding with interventional techniques (50,55-57,63,74,77-83,86-209). In a survey of practice patterns among



interventional pain physicians in 2012, Manchikanti et al (50) showed that the majority of physicians discontinued antithrombotic agents; however, this study also showed that there were a significantly higher number of complications related to thromboembolic events from a total of 162 compared to hemorrhagic complications from a total of 55 in this population. In an updated assessment of practice patterns of perioperative management of antiplatelet agent and anticoagulant therapy in interventional pain management, Manchikanti et al (51) showed that 23% changed their practice patterns. Discontinuation of antiplatelets and anticoagulants was highest for high-risk procedures. However, a significant proportion of physicians discontinued them for low-risk and moderate-risk procedures also.

In a systematic review, Kumar et al (40) showed that the prevalence of idiopathic, non-traumatic spontaneous spinal hematoma with concomitant anticoagulation treatment was higher with 74% compared to antiplatelet therapy (27%). The lumbar spine was the most common site of hematoma formation with 106 (41.7%), followed by the cervical spine with 57 (21.01%), and thoracic spine with 22 (8.49%). Most patients (70%) required surgery while 30% had conservative management.

In their 2020 survey study, Gupta et al (165) noted that 32%-59% of pain physicians, both in the United States and the United Kingdom, stopped antithrombotic medications before medial branch blocks and radiofrequency denervation across all spinal levels. Pre-procedural antithrombotic therapy discontinuation was most prevalent in anticipation of cervical radiofrequency denervation procedures, with more than 58% physicians discontinuing them in both countries. It should be recognized that these practices may represent more conservative care in the context of negligible or extremely low risk of bleeding complications in the form of epidural or spinal hematoma formation.

In a prospective evaluation of bleeding risks for interventional techniques in chronic pain, Manchikanti et al (55) assessed the rates of adverse events in patients undergoing interventional techniques on antithrombotic therapy with cessation or without cessation and compared them to a group of patients without use of antithrombotic therapy. While the results showed differences in minor complications, there were no reports of hemorrhagic complications requiring any type of treatment. In this assessment, the authors studied all types of procedures with 1,227 of 1,831 continuing

aspirin (81 mg) compared to 604 of 1,831 discontinuing them. Similarly, they also studied 100 patients on clopidogrel with continuation, whereas 226 patients were discontinued. Further, there were 128 patients with aspirin (81 mg) and other agents with continuation and 151 were discontinued. The procedures performed included cervical epidural injections with continued aspirin use (81 mg) in 249 patients, thoracic epidural in 30 patients, lumbar interlaminar epidural in 128 patients, lumbar transforaminal in 144 patients, whereas 528 patients for caudal epidural injections, and 148 for percutaneous adhesiolysis. In reference to clopidogrel, it was continued in 10 patients undergoing cervical epidural, one patient with thoracic epidural, 14 patients with lumbar epidural, 44 patients with caudal epidurals, 10 with lumbar transforaminal epidural, and 21 with percutaneous adhesiolysis. There were a large number of facet joint interventions and other treatments included.

Benzon et al (61) in a literature review of spinal hematoma case reports analyzed causes and outcomes in pediatric, obstetric, neuraxial and pain medicine cases published by searching the literature from 1954 to July 2022. A total of 940 cases were evaluated. The results showed that among 262 adult non-obstetric patients on anticoagulants and antiplatelets, 36 procedures, or 7% of hematomas were related to interventional pain procedures. Recovery after surgery in patients who had focal deficits was 68.5% (125 of 183) with complete recovery, 28.5% (52 of 183) with partial recovery and no recovery in 6 patients (3%). However, recovery after surgery in patients who had paralysis was less favorable with complete recovery in 36% (49 of 135), partial recovery in 51% (68 of 135), and no recovery in 13% (18). They also showed the results of conservative management in 199 patients. Of the 199 patients receiving conservative management, 6 of the 7 patients had full recovery within several hours of initial evaluation, whereas patients who did not show any improvement either died or had several comorbidities.

Schieber et al (41) evaluated the influence of antithrombotic medication on size and neurological outcome of spinal epidural hematoma after neuraxial anesthesia in a systematic review. Their analysis encompassed 345 cases documented across 304 publications. The researchers identified a total of 56 cases of spinal epidural hematoma arising from interventional pain procedures, with 26 occurring in patients without thrombotic medication and 30 in those using antithrombotic medication. The study revealed no sig-



nificant difference in the size of hematomas between groups. However, individuals receiving antithrombotic medications exhibited a higher likelihood of experiencing persistent neurological deficits. Patients deviating from established guidelines faced a 3.4 times greater risk of enduring neurological deficits after spinal epidural hematoma.

Simon et al (86) in a retrospective chart review of 392 injections reported no complications regardless of patients' imaging findings, age, and antithrombotic medication used or the underlying medical condition for which antithrombotic medication was indicated. All the patients continued antithrombotic medication prior to undergoing the epidural including warfarin in 80 patients, and dual agents in 113 patients. They also referred to two case reports in the literature of epidural hematoma and hypothesized that if epidural hematoma develops with caudal epidural injections, they are less likely to be clinically relevant than those in the lumbar spine where epidural injections are typically performed at, or very close to, the site of significant neural compression. They also hypothesized that it is a likely scenario as a theoretically larger vertebral canal would provide greater space for the propagation of hematoma development and for blood run off without creating dual compression.

Endres et al (56) evaluated the risks of continuing or discontinuing anticoagulants for patients undergoing common interventional pain procedures. This was an observational study in a private practice in which some physicians continued anticoagulants while other physicians routinely discontinued anticoagulants. The study results showed that anticoagulants were continued in 4,766 procedures, whereas they were discontinued in 2,296 procedures according to the guidelines. There were multiple fatalities with serious morbidity in 9 patients, including 2 deaths in patients after discontinuation. Among the various drugs, clopidogrel was the most common drug next to warfarin and it was continued again in a smaller proportion of patients with interlaminar epidural injections and radiofrequency neurotomy, whereas it was discontinued in a large proportion of patients with transforaminal epidural injection, medial branch blocks. All other drugs were small numbers. It was surprising that aspirin alone was not included in the study or there were no patients on aspirin. However, they had 97 patients with aspirin and dipyridamole, and it was not continued either in radiofrequency neurotomy or interlaminar epidural injections. Among the complications, discontinuation

of warfarin was involved in all cases. Of the 9 patients, 6 suffered with atrial fibrillation, whereas one suffered with IHD, one with pulmonary embolism, and another one with IHD and atrial fibrillation. Procedures were 3 cervical epidurals, one lumbar radiofrequency neurotomy, one cervical medial branch blocks, 2 lumbar interlaminar epidurals, one lumbar transforaminal epidural, and one lumbar intrathecal injection. Authors postulated that risk of continuation of anticoagulants or antiplatelets was 0% with 95% CI of 0% to 1.5%.

Endres et al (58) in subsequent follow up updated study of not ceasing anticoagulants for patients undergoing injection procedures for spinal pain. They prospectively evaluated 1,936 patients during a total of 12,723 injection procedures. Compared to the previous study (56), the authors felt that the numbers of patients who continued warfarin or clopidogrel were large enough to calculate meaningful prevalence data. Among the spinal procedures, antithrombotics or anticoagulants were discontinued in 3,273 patients compared to 8,165 patients where they were continued. They did not discontinue in radiofrequency neurotomy or interlaminar epidural procedures. Consequently, they showed a zero prevalence of complications when performing transforaminal injections or facet injection with a 95% CI of 0.0% to 0.3% when warfarin was continued and 0.0% to 0.4% when clopidogrel was continued. They also showed that among the patients receiving anticoagulants, none suffered any complications from their injection, but 9 suffered medical complications before their procedure. These consisted of one fatal myocardial infarction, one fatal stroke, 5 non-fatal strokes, one pulmonary embolism, and one nonfatal myocardial infarction. These complications are the same as the previously reported data (56). In this study, they calculated the prevalence of these complications of ceasing warfarin was 9 in 1,886 (0.48%), with a 95% CI of 0.2% to 0.9%. They are felt that the data was sufficiently robust, hence they calculated CI of difference between 2 proportions, the risk rate of ceasing warfarin 0.2% to 0.9% is significantly greater than the risk rate of continuing warfarin 0.0% to 0.3% for transforaminal injections, or facet injections.

Thus, both studies (56,58) have reiterated the safety of non-epidural spinal procedures while epidural procedures continue to be at increased risk.

Furman et al (80) evaluated epidural hematoma risks associated with ceasing maintaining anticoagulant and/or antiplatelet medications (ACAP) for cervical and thoracic interlaminar epidural steroid injections in

591 patients from 2009 to 2017. In this assessment 351 patients ceased their anticoagulant and/or antiplatelet medications ACAP prior to the procedure and 240 maintained ACAP medication. The most common ACAP medication or medication combinations were aspirin (159 total, 110 maintained), clopidogrel and aspirin combination therapy (143 total, 43 maintained), warfarin (142 total, 21 maintained), clopidogrel (90 total, 28 maintained), and warfarin and aspirin combination therapy (54 total, 12 maintained). All other medications were in minority of patients. The majority of the procedures were in cervical spine performed at C7-T1, except 4 patients where it was performed at C6-C7. All thoracic patients were 26 of 591. Of the total 591 patients, 351 patients ceased their ACAP medication prior to the procedure and 240 maintained ACAP medication. Of those that ceased ACAP medications, 195 were on antiplatelet medication, 103 were on anticoagulant medication, and 53 were on both antiplatelet and anticoagulant medications, 190 patients maintained antiplatelet medication, 36 maintained anticoagulant medication, and 14 maintained anticoagulant and antiplatelet medications. It is important to note that patients maintaining the anticoagulant or antiplatelet therapy were very few and were low in warfarin group with 33 maintaining and 143 ceasing. In addition, of the 124 patients instructed to cease warfarin therapy, 45 patients had missing INR data. Of the 79 patients with available INR data, the mean INR was 1.28, with 7 patients with an INR between 2 and 3, 11 patients with an INR between 1.4 and less than 2, and the remaining 61 had an INR of 1.3 or less. Overall, the results showed there were no incidences of clinically relevant epidural hematoma reports. In contrast to previously reported risk non-zero risk, this report showed zero risk, both in patients continuing therapy and those discontinuing the therapy. However, they also warned that this cannot be construed to say the risk of epidural hematoma following cervical interlaminar epidural steroid injections is zero percent, but a silver lining is that when considering the relative risks of ceasing or maintaining ACAP medications, the study provides the data which can guide the further discussion. Interestingly enough, they have not reported any cardiovascular or cerebrovascular events in this study.

Warner et al (83) in a publication describing bleeding and neurological complications in 58,000 interventional pain procedures showed that preprocedural aspirin or NSAID therapy was prevalent in 17,825 procedures or 30.7% of the procedures without identifying

clinically significant bleeding complications. Out of a total of 58,066 procedures performed in the study, 22.4% of the procedures were performed with perioperative administration of aspirin within 7 days, 12.1% of the patients had administration of NSAIDs within 7 days, and 1.6% had clopidogrel within 7 days. The study also included 3,880 lumbar epidural injections, 304 thoracic interlaminar injections with a large number of epidural injections with over 50% of the epidural injections not assigned to a region. They concluded that bleeding complications were rare in patients undergoing low or intermediate risk pain procedures even in the presence of antiplatelet medications.

Lagerkranser and Lindquist (82) have published an extensive review of neuraxial blocks and spinal hematoma in 2 parts from 1994 to 2015 covering demographics, risk factors, diagnosis, treatment, and outcome. They also considered previous reviews published in 1992, 1994, and 1996 case reviews, analyzing 29, 61, and 51 cases of spinal hematoma after neuraxial blocks, respectively, between 1906 and 1996, in 147 publications (82). In managing chronic pain with epidural injections, they identified 21 hematomas, 17 (5 cervical, 4 thoracic, and 8 lumbar) after epidural injections, and 4 after percutaneous application of spinal cord stimulator leads. However, they did not identify the number of patients developing hematoma with appropriate cessation of antithrombotic therapy based on recommended guidelines. Overall, they showed that 37% of the patients were not on antihemostatic drugs, whereas 63% were on antihemostatic drugs with 47 of the cases receiving more than one antihemostatic drug, and 12 receiving 3 such drugs. Further, they also had 6 reports which were indeterminate. Consequently, the number of patients without antithrombotic therapy, but with hematoma formation seems to be almost 40%.

Lagerkranser (81) showed an annual average of 7.5 published cases of spinal hematoma in the years 1994 to 2015, compared to an average of 2.5 case reports per year from 1976 to 1993. They also identified that there has been a transition from a male to female dominance among patients suffering from post-neuraxial blockade and spinal hematoma particularly among the elderly women. They identified bloody tap at the introduction of a neuraxial needle or catheter as a major risk factor, but multiple attempts to reach the spinal canal do not seem to increase the risk of spinal hematoma. Their results also showed that 80% of the patients developing spinal hematoma had severe neurological symptoms with paresis or paralysis. When compared over time,

outcomes have improved significantly (81). The results showed that among patients subjected to surgical evacuation of spinal epidural hematoma, outcomes were best if surgery was performed within 12 hours from the first sign of motor dysfunction. However, even patients operated on after more than 24 hours had relatively favorable outcomes. Further, outcomes after surgical evacuation of the epidural hematoma were satisfactory, compared to subdural hematoma, which had poor outcomes. They recommended that suspicion of spinal hematoma calls for the consultation of a surgeon without delay. Magnetic resonance imaging (MRI) was the recommended diagnostic tool. Surgical evacuation within 12 hours from the sign of motor dysfunction seems to lead to the best outcome, even though many patients operated on as late as after more than 24 hours did regain full motor function (81).

Table 2 describes the studies assessing the risk of thrombosis and bleeding with interventional pain

management procedures (41,50,51,55-57,61,63,74,77-84,86). Among all the available reports, several of them were literature reviews (41,57,61,81,82), 2 surveys conducted by mail (50,51), and multiple observational studies (55,56,63,74,77-80,83,84,86). Only 5 studies (50,56,59,62,68) reported thromboembolic risk (Table 3). Overall, epidural injections, specifically those in the cervical spine were reported frequently which constituted a minor proportion of all interventional techniques. In contrast, the majority of interventional techniques constituted low risk or moderate or intermediate risks, including transforaminal epidural injections. Overall, the importance of the incidence of epidural hematomas in patients without antithrombotic therapy has been underestimated. Similarly, the risk of thromboembolic phenomenon also has been underestimated.

A systematic review of risks and benefits of ceasing or continuing anticoagulant medication for image-guided procedures for spine pain by Smith et

Table 2. Studies assessing the risk of thrombosis and bleeding with interventional pain management procedures.

Study/Year	Methods	Results	Thromboembolic Risk	Conclusions by the Study Authors	Author Conclusions of the Review
Benzon et al, 2024 (61) Literature Review	<p>A literature review of spinal hematoma case reports, along with causes and outcomes in pediatric, obstetric, neuraxial, and pain medicine cases was performed. Utilizing a flow chart, they identified 940 articles which were included in the systematic review from the search from 1954 with the first list of spinal hematomas until July 31, 2022.</p> <p>In this evaluation, the pain procedures included epidural steroid injection, spinal cord stimulation, or intrathecal pump placement, vertebroplasty or kyphoplasty.</p>	<p>The patients were treated with either aspirin, aspirin plus NSAID, clopidogrel, warfarin, ultra fractionated heparin, or the discontinuation was shorter than recommended by ASRA guidelines. A total of 940 cases were evaluated. Of these, 260 cases were in non-obstetric patients, on anticoagulants and antiplatelet. Of these, 36 or 7% of the hematomas were related to interventional pain procedures, whereas 12% or 62 were related to neuraxial procedures.</p> <p>The patient treatment was divided into patients with focal and patients with paralysis. Of the 183 patients with focal deficits, complete recovery was observed in 125 patients (68.5%), partial recovery in 52 (28.5%) and no recovery in 63%. In patients who had paralysis, of 135, 49 (36%) had complete recovery, 68 (51%) had partial recovery and 18 (13%) had no recovery.</p>	No description of thromboembolic phenomenon was available	<p>The data show a preponderance of spontaneous SEH in all patient populations. SEH developed even though the ASRA guidelines were followed, especially in patients on multiple anticoagulants. Patients with less impairment prior to surgery had a higher likelihood of complete recovery, regardless of the interval between surgery and onset of symptoms.</p> <p>Neurological recovery in patients who were treated conservatively was poor with 199 patients. Patients who did not show any improvement either died of MI stroke, pneumonia, kidney failure or had several comorbidities.</p>	<p>The results of this extensive literature review are similar to other reviews presenting spinal hematoma in 36 cases, or 7% of spinal hematoma cases in relation to anticoagulant use related to interventional pain procedures.</p> <p>The review also emphasizes on surgical management with full recovery in the majority of the patients; whereas conservative management does not lead to appropriate recovery unless there was spontaneous improvement early.</p>

Table 2 cont. *Studies assessing the risk of thrombosis and bleeding with interventional pain management procedures.*

Study/Year	Methods	Results	Thromboembolic Risk	Conclusions by the Study Authors	Author Conclusions of the Review
<p>Schieber et al, 2023 (41)</p> <p>Systematic Review</p>	<p>The authors in this article sought to analyze if there is a correlation between antithrombotic medication administration and on the size of spinal epidural hematoma and neurological outcome.</p> <p>The authors utilized an extensive search strategy and identified a total of 304 studies. Of these, they identified spinal epidural hematoma in 56 patients with 26 without antithrombotic medication and 30 with thrombotic medication.</p>	<p>A total of 345 cases reported in 304 publications were included. Of these, there were 56 cases of epidural hematoma related to pain procedures. Of these, 26 received no antithrombotic medication and 30 received thrombotic medication.</p> <p>Size of the hematoma was not significantly different. Patients receiving antithrombotic medication were more likely to have persistent neurological deficits. Patients with non-guideline adherence had a 3.42 higher chance of persistent neurological deficit.</p>	<p>No description of thromboembolic phenomenon was available</p>	<p>Patients receiving antithrombotic medication have similar hematoma size, measured in segments, as their counterparts not receiving medication. Persistent neurological deficit was more likely in patients on antithrombotic medication or having not adhered to guidelines.</p>	<p>This systematic review reports numbers similar to other studies and similar to other systematic reviews and guidelines. The systematic review shows that epidural hematoma can develop without antithrombotic medication. Overall, there does not appear to be the difference in incidence of epidural hematoma during pain procedures whether the patient was receiving antithrombotic medication or not.</p>
<p>Manchikanti et al, 2024 (51)</p> <p>Mail-in Survey</p>	<p>The survey was conducted based on online responses of the members of the American Society of Interventional Pain Physicians (ASIPP). The survey was designed similar to the 2012 survey to assess updated practice patterns.</p>	<p>The results showed that 23% (changed their practice patterns during the past year). The results showed that all physicians discontinued warfarin therapy with the majority of physicians accepting an INR of 1.5 as a safe level. Low dose aspirin was discontinued for 3 to 7 days for low-risk procedures by 8% of the physicians, 34% of the physicians for intermediate risk procedures, whereas they were discontinued by 76% of the physicians for high-risk procedures. Antiplatelet agents, including dipyridamole, cilostazol, and Aggrenox (aspirin, extended-release dipyridamole) were discontinued from 3 to 5 days by 18%-23% of the physicians for low-risk procedures, approximately 60% of the physicians for intermediate-risk procedures, and over 90% of the physicians for high-risk procedures. Platelet aggregation inhibitors clopidogrel, Prasugrel, ticlopidine, and ticagrelor were discontinued for 3 to 5 days by approximately 26% to 41% for low-risk procedures, almost 90% for intermediate-risk procedures, and over 97% for high-risk procedures. Anti-Xa agents, apixaban, rivaroxaban, and Edoxaban were discontinued in over 25% of the physicians for low-risk procedures, approximately 90% for intermediate-risk procedures, and 99% for high-risk procedures.</p>	<p>No description of thromboembolic phenomenon was available</p>	<p>The results illustrate the continued pattern of discontinuing antiplatelet and anticoagulant therapy in the perioperative period. Majority of discontinuation patterns appear to fall within guidelines.</p>	<p>The study results are similar to the previous study conducted in 2012. However, in this study, risks of thromboembolism were not assessed.</p>

## Antiplatelet and Anticoagulant Therapy in Patients Undergoing Interventional Techniques

Table 2 cont. *Studies assessing the risk of thrombosis and bleeding with interventional pain management procedures.*

Study/Year	Methods	Results	Thromboembolic Risk	Conclusions by the Study Authors	Author Conclusions of the Review
Manchikanti et al, 2012 (50)  Mail-in Survey	A mail-in survey of physicians' use of antithrombotics with complications with or without discontinuation of various antiplatelet and anticoagulants.	The results illustrated an overwhelming pattern of discontinuing antiplatelet and warfarin therapy as well as aspirin and other NSAIDs prior to performing interventional pain management techniques. However, thromboembolic complications were 3 times more prevalent than epidural hematomas (162 versus 55 events).	Thromboembolic risk was evaluated with significant occurrence	The authors concluded that clinicians must balance the risks of thromboembolism and bleeding in each patient prior to the routine discontinuation of antiplatelet therapy.	This study essentially shows that even though there is no evidence of increased risk of epidural hematoma, the majority of physicians discontinue antiplatelet therapy despite increased risk of thromboembolic complications.
Smith et al, 2018 (57)  Systematic Review	Systematic review of the literature with comprehensive analysis of the published data of studies pertaining to spine pain interventions on anticoagulant medication.  They reviewed 14 studies with applicable evidence. Procedures involving interlaminar access included medial branch blocks, transforaminal epidural steroid injections, and interlaminar epidural steroid injections.  The authors sought the risks associated with either continuing or ceasing anticoagulant and antiplatelet medication in patients having image guided interventional spine procedures.	The results showed that procedures involving interlaminar access carried a non-zero risk of hemorrhagic complications, regardless of whether anticoagulant ceased or continued. For other procedures, hemorrhagic complications have not been reported and case series indicated that they are safe when performed in patients who continue anticoagulants. The results also showed that 3 articles reported the adverse effects of ceasing anticoagulants, with serious consequences, including death.	Thromboembolic risk was evaluated with 3 out of 14 studies reporting the adverse effects of seizing anticoagulation with serious consequences, including death.	Authors concluded that other than for interlaminar procedures, the evidence does not support the view that anticoagulant and antiplatelet medication must be ceased before image-guided spine pain procedures. Further, they also showed that ceasing anticoagulant carries a risk of serious consequences, including death.	This systematic review shows significance of systematic assessment showing only procedures with interlaminar access required cessation of anticoagulant or antiplatelet therapy.  In addition, cessation of therapy also was associated with adverse cardiovascular and cerebral complications.
Manchikanti et al, 2011 (55)  Prospective Evaluation	The prospective evaluation of measurable outcomes of intravascular entry of the needle, bruising, local bleeding, profuse bleeding, local hematoma, oozing, and postoperative soreness.	In this study, one-quarter (3,087) of patient encounters undergoing interventional pain management procedures were on antithrombotic therapy. Antithrombotic therapy was continued in 55% of the patients or 1,711 encounters, whereas it was discontinued in 45% of the patients or 1,376 encounters.  There was no difference in significant side effect rate with or without continuation of antithrombotic therapy.	None reported	Of the 1,831 patients receiving aspirin 604 discontinued and 1,227 continued and all of them received epidural injections including cervical, thoracic, lumbar interlaminar, and caudal epidural injections. Of the total 326 patients undergoing epidural injections on clopidogrel 226 discontinued and 100 continued with patients undergoing all types of epidural injections including cervical, thoracic, and lumbar interlaminar epidural injections. However, for cervical epidural injections a large proportion discontinued (67) versus continued (10). There was no clinical or statistical difference in any of the major aspects of bleeding.	This study essentially showed that there is no significant difference in bleeding patterns whether antithrombotic agents are continued or discontinued except for warfarin with no fatal incidents in a large proportion of patients.

Table 2 cont. *Studies assessing the risk of thrombosis and bleeding with interventional pain management procedures.*

Study/Year	Methods	Results	Thromboembolic Risk	Conclusions by the Study Authors	Author Conclusions of the Review
<p>Furman et al, 2023 (80)</p> <p>Observational study</p>	<p>This observational study was performed in a private practice on patients receiving cervical and thoracic interlaminar epidural injections from September 2009 to July 2017. They studied a total of 591 patients taking anticoagulant and antiplatelet medication. In total, 351 patients ceased their anticoagulant and/or antiplatelet (ACAP) medications prior to the procedure and 200 maintained ACAP medication.</p>	<p>A total of 591 interlaminar cervical or thoracic epidural steroid injections were performed on patients taking ACAP medications. In total 351 patients stopped their ACAP medication prior to the procedure and 240 maintained ACAP medication.</p> <p>Of those that ceased ACAP medication, 195 were on antiplatelet medications, 103 were on anticoagulant medications, and 53 were on both antiplatelet and anticoagulant medications, 190 patients maintained antiplatelet medication, 36 maintained anticoagulant medications, and 14 maintained anticoagulant and antiplatelet medications.</p> <p>The most common ACAP medication of medication combinations encountered were aspirin (159 total, 110 maintained), clopidogrel and aspirin combination therapy (143 total, 43 maintained), warfarin (142 total, 21 maintained), clopidogrel (90 total, 28 maintained), and warfarin and aspirin combination therapy (54 total, 12 maintained).</p> <p>All cervical epidural procedures were performed at C7-T1 except 4 patients where it was performed between C6 and C7. A small proportion of patients received thoracic interlaminar epidural injections. The results showed no clinically relevant epidural hematomas in the patient cohort.</p>	<p>Not assessed</p>	<p>The data gives critical insight into the post procedural hematoma risk for patients who had continued or stopped taking their ACAP medications prior to their interlaminar cervical or thoracic epidural steroid injections. They further concluded that the results of this study suggested re-evaluating the potential post procedure epidural hematoma risks associated with continuing verses ceasing these medications.</p>	<p>This is an important study with a large number of patients. Unfortunately, the number of patients continuing strong anticoagulant therapy were small compared to those ceasing the therapy.</p> <p>These results are similar to multiple previously published results; however, it is essential to consider that all of the epidural hematoma reports are from case reports rather than prospective or retrospective studies. Retrospective studies is the appropriate manner to identify and estimate the prevalence and risk of epidural hematoma.</p> <p>However, for a complication which develops rarely, this is a difficult venture. This study proves the same.</p>

## Antiplatelet and Anticoagulant Therapy in Patients Undergoing Interventional Techniques

Table 2 cont. *Studies assessing the risk of thrombosis and bleeding with interventional pain management procedures.*

Study/Year	Methods	Results	Thromboembolic Risk	Conclusions by the Study Authors	Author Conclusions of the Review
Ehsanian et al, 2020 (84)  Retrospective Cohort Study	<p>The authors sought to identify bleeding complications following spinal interventions in patients taking medications with antiplatelet or anticoagulation effects. In this review, they included cervical and lumbar epidurals and facet joint interventions.</p> <p>They continued antiplatelet and anticoagulant medications for all interventional spine procedures, except for interlaminar epidural steroid injections. If warfarin was continued, they looked at their INR in the therapeutic range (INR &lt; 3).</p>	<p>In this cohort of 275 consecutive encounters with available records in which patients underwent a spinal injection while continuing medications with antiplatelet or anticoagulant effect, zero of the 275 clinical encounters (0%, 95% confidence interval = 0–1.4%) resulted in epidural hematoma or other serious bleeding. For antiplatelet medication, NSAIDs were continued in 102 procedures, aspirin in 142, clopidogrel in 21, and meloxicam and/or Celebrex in 81; for anticoagulation medication, warfarin was continued in four procedures, apixaban in six, dabigatran in one, and fondaparinux in two. Of note, one patient suffered a deep vein thrombosis, which was identified at two-week follow-up despite continuing aspirin therapy.</p>	<p>One case of deep vein thrombosis was reported after 2 weeks</p>	<p>The risk of serious bleeding complications from select spine interventions while continuing medications with antiplatelet or anticoagulant effect appears low.</p> <p>One patient suffered a deep vein thrombosis, which was identified at 2-week follow despite continuing aspirin therapy.</p>	<p>The results are similar to other evaluations with lack of significant risk of hematoma formation in patients undergoing interventional techniques other than interlaminar epidural injections.</p> <p>The study also shows incidence of one deep vein thrombosis, which was identified at 2-week follow-up despite continuing aspirin therapy.</p> <p>Overall, even though the study presents as continuation of anticoagulants, the majority were related to aspirin with remaining drugs, including clopidogrel, apixaban, and warfarin was in a very small proportion of patients.</p> <p>It may not be feasible to draw any conclusions from this study.</p>
Endres et al, 2017 (56)  Observational Study	<p>The study was performed as an observational study in a private practice in which some partners continued anticoagulants while other partners routinely discontinued anticoagulants. They studied 4,766 procedures in which anticoagulants were continued and 2,296 procedures in which anticoagulants were discontinued.</p>	<p>No complications attributable to anticoagulants were encountered in 4,766 procedures in which anticoagulants or antiplatelet therapy were continued; however, in 2,296 procedures in which anticoagulants (Warfarin) was discontinued, according to the guidelines, 9 patients suffered serious morbidity, including 2 deaths.</p>	<p>Thromboembolic risk was assessed, and serious complications were observed in 0.2% of the patients.</p> <p>The complications included one fatal myocardial infarction, one fatal stroke, 5 nonfatal strokes, one pulmonary embolism, and one nonfatal myocardial infarction. All of the patients in this group were on warfarin. The majority of them suffering with atrial fibrillation.</p>	<p>Lumbar transforaminal epidural injections, lumbar facet joint nerve blocks, trigger point injections, and sacroiliac joint blocks appear to be safe in patients who continue anticoagulants. In patients discontinuing anticoagulants, serious complications are observed in a low proportion of patients with 0.2%.</p>	<p>This is an observational study in a large number of patients. The author's conclusions are appropriate correlating with other conclusions that risk serious complications of discontinuing anticoagulant therapy, even though this risk is low at 0.2%.</p> <p>This study is limited to spinal procedures excluding interlaminar epidural injections and radiofrequency neurotomy procedures. Thus, the data can be only applied to transforaminal epidural injections, as well as facet joint injections. Further, the data is limited to lumbar transforaminal only, making it difficult to extrapolate to thoracic and cervical transforaminal epidural injections.</p>

Table 2 cont. *Studies assessing the risk of thrombosis and bleeding with interventional pain management procedures.*

Study/Year	Methods	Results	Thromboembolic Risk	Conclusions by the Study Authors	Author Conclusions of the Review
Endres et al, 2020 (58)  Prospective, observational study	The study was performed as a prospective evaluation monitoring a total of 12,723 injection procedures in 1,936 consecutive patients  Among the spinal procedures, antithrombotics or anticoagulants were discontinued in 3,273 patients compared to 8,165 patients where they were continued. They did not discontinue radiofrequency neurotomy or interlaminar epidural procedures.	Among the patients who ceased anticoagulants, none suffered any complications from their injection, but 9 suffered myocardial complications before their procedure as described in previous publications (56). They calculated the prevalence of complications when warfarin ceased as 0.48% with 9 out of 1,886, with a 95% CI of 0.2% to 0.9%.  Using the CIs of the difference between 2 proportions, the risk rate of ceasing warfarin 0.2% to 0.9% was significantly greater than the risk rate of continuing warfarin 0.0% to 0.3% for transforaminal injections or facet injections.	Thromboembolic risk was assessed as in the above publication with a 0.48% with the enlarged sample, whereas it was 0.48% with 95% CI of 0.2% to 0.9%.	The authors concluded that lumbar transforaminal injections and lumbar facet injections have a very low rate of hemorrhagic complications when patients continue to take anticoagulants.	This is an extension of the above study with the updated data; however, once again, the study was limited to nonepidural procedures. This study was specifically limited to lumbar transforaminal and facet joint injections excluding radiofrequency neurotomy.  This study is limited to spinal procedures excluding interlaminar epidural injections and radiofrequency neurotomy procedures. Thus, the data can be only applied to transforaminal epidural injections, as well as facet joint injections. Further, the data is limited to lumbar transforaminal only, making it difficult to extrapolate to thoracic and cervical transforaminal epidural injections.
Warner et al, 2017 (83)  Retrospective Study	Retrospective cohort of adult patients undergoing low and intermediate risk pain procedures were assessed from 2005 through 2014 at a single academic tertiary care center.  A total of 58,066 procedures were performed on 24,590 patients. Antiplatelet therapy included preprocedural aspirin or nonsteroidal anti-inflammatory drug therapy in 17,825 procedures comprising 30.7%.	The study included 3,880 lumbar epidural injections, 304 thoracic interlaminar injections with a large number of epidural injections with over 50% unassigned to a region.  22% of the patients received aspirin within 7 days, 12% of the patients received nonsteroidal anti-inflammatory drugs within 7 days, 2% clopidogrel within 7 days, and Coumadin within 7 days in 3% of the patients. They also maintained an INR of 1.0.	No description of thromboembolic phenomenon was available	Authors concluded that bleeding complications are rare in patients undergoing low or intermediate pain procedures, even in the presence of antiplatelet medications.	Authors studied low and intermediate risk procedures in patients on NSAIDs including aspirin. Of these, 22% of the patients received aspirin within 7 days.  The study also included 3,880 lumbar epidural injections, 304 thoracic interlaminar injections with a large number of epidural injections with over 50% of the epidural injections not assigned to a region.
Goodman et al, 2017 (78)  Prospective Study	A prospective descriptive evaluation of patients undergoing interventional pain procedures on various antiplatelet and anticoagulant agents at a single interventional physiatry practice.	Overall incidence of spinal epidural hematoma for all procedures studied was one in 4,047 procedures (0.02%, 95% CI ¼ 0.00–0.15%). No thromboembolic events (myocardial infarction, cerebrovascular accident, or critical limb ischemia) were observed within 24–48 hours after spinal injection for all patients in the study.	No description of thromboembolic phenomenon was available	Continuation of clopidogrel or warfarin for lumbar transforaminal epidural and posterior approach facet joint injections may be reasonable. Interlaminar injections carry greater bleeding risk and merit consideration of holding anticoagulant/antiplatelet agents.	Authors have not provided any conclusive evidence if one procedure is safer to perform than the other while the patient continues the anti-thrombotic agents.



## Antiplatelet and Anticoagulant Therapy in Patients Undergoing Interventional Techniques

Table 2 cont. *Studies assessing the risk of thrombosis and bleeding with interventional pain management procedures.*

Study/Year	Methods	Results	Thromboembolic Risk	Conclusions by the Study Authors	Author Conclusions of the Review
van Helmond et al, 2017 (79) Retrospective Study	Retrospective review of the safety of low to intermediate risk spine procedures in patients with continued antithrombotic therapy.	Authors identified 490 patients out of total of 2,204 patients on antithrombotic medications which included aspirin, P2Y12 inhibitors, warfarin, heparin, factor Xa inhibitors, and dipyridamole. The procedures included facet joint nerve blocks and facet joint radiofrequency in all spine regions and sacroiliac joint injections.	No description of thromboembolic phenomenon was available	Authors concluded that there were no hemorrhagic complications in performing these procedures and they were safe.	The results are in a small number of patients with low risk and intermediate risk procedures of facet joint interventions and sacroiliac joint interventions without inclusion of high-risk procedures of interlaminar epidural injections.
Simon et al, 2021 (86) Retrospective Study	This study evaluated the complication rate of caudal epidural steroid injections in patients who remain on antithrombotic medications.  A retrospective chart review was performed identifying patients (n = 335) who received a caudal epidural steroid injection (n = 673) from June 2015 through April 2020. Patients were included if they had received the injection while taking an antithrombotic medication. Patients were excluded if they were not taking an antithrombotic. The patient's age, indication for the injection including MRI or computed tomography findings, antithrombotic medication, the medical condition requiring an antithrombotic, and any complications following the injection were collected via chart review.	Of the 443 injections included in the study, 51 encounters were lost to follow-up. Of the other 392 injections, there were no reported complications, regardless of the patient's imaging findings, age, the antithrombotic medication used, or the underlying medical condition for which an antithrombotic medication was indicated.	No description of thromboembolic phenomenon was available	We conclude that caudal epidural steroid injections can be performed safely in patients while taking antithrombotic medications. Catastrophic events have been observed in patients who have discontinued antithrombotic agents preceding procedures. Thus, discontinuing antithrombotic medications may pose a greater risk than benefit for patients on an antithrombotic medication who have painful lumbar radiculopathy.	This evaluation shows lack of risk of spinal epidural hematoma in patients receiving caudal epidural injections and also on antiplatelet and anticoagulants without discontinuation.
Horlocker et al, 2002 (74) Prospective Study	A prospective study of 1,214 epidural steroid injections in ambulatory pain centers. 32% of the patients were receiving NSAIDs, including 34 patients on multiple medications. Aspirin was the most common NSAID and was noted by 158 patients including 140 patients on 325 mg or less per day.	There were no major hemorrhage complications with spinal hematomas. NSAIDs did not increase the frequency of minor hemorrhagic complications. Increased age, needle gauge, needle approach, needle insertion at multiple interspaces, number of needle passes, volume of injectate, and accidental dural puncture were all significant risk factors for minor hemorrhagic complications.	No description of thromboembolic phenomenon was available	Authors concluded that epidural steroid injection is safe in patients receiving aspirin-like antiplatelet medications. Minor worsening of neurologic function may occur after epidural steroid injection and must be differentiated from etiologies requiring interventions.	The results of this study strongly show that discontinuation of antiplatelet therapy and continued therapy with Aspirin was not essential and is not associated with major hemorrhagic complications.

Table 2 cont. *Studies assessing the risk of thrombosis and bleeding with interventional pain management procedures.*

Study/Year	Methods	Results	Thromboembolic Risk	Conclusions by the Study Authors	Author Conclusions of the Review
Lagerkranser et al, 2017 (81,82)  Literature Review	<p>Authors studied neuraxial blocks and spinal hematoma with review of 166 case reports published from 1994 to 2015 with descriptions of demographics, risk factors, diagnosis, treatment, and outcomes.</p> <p>They utilized extensive search criteria in various languages across the globe. They also compared the previous reports published in 1992, 1994, and 1996.</p> <p>37% of patients with hematoma were not receiving antithrombotic therapy.</p>	<p>They identified 166 case reports on spinal hematoma after central neuraxial blockade during the years between 1994 and 2015. The annual number of case reports published during this period almost tripled compared with the 2 preceding decades.</p> <p>Authors identified 21 cases of hematoma from epidural injections with 17 after steroid injections, 5 in cervical, 4 in thoracic, and 8 in lumbar regions. They also identified 4 after percutaneous application of spinal cord stimulation.</p> <p>The authors identified spinal stenosis as the most common spinal disease, which was identified as the most common of all spinal diseases in 14 cases with spinal disease reported in 37 of 166 cases.</p>	No description of thromboembolic phenomenon was available	<p>Authors concluded that anti-hemostatic drugs, heparins in particular, are still major risk factors for developing spinal bleeding. Other risk factors were hemostatic and spinal disorders and complicated blocks, especially bloody taps, whereas multiple attempts did not seem to increase the risk of bleeding.</p> <p>They recommended that suspicion of spinal hematoma calls for the consultation of a surgeon without delay. MRI was the recommended diagnostic tool. Surgical evacuation within 12 hours from the sign of motor dysfunction seems to lead to the best outcome, even though many patients operated as late as after more than 24 hours did regain full motor function.</p>	<p>This report is an extensive review of epidural hematoma of all origins, specifically of epidural injections for chronic pain with a prevalence of 21 cases of hematoma after spinal cord stimulation.</p> <p>Hematomas were identified in 37% of patients without antithrombotic therapy.</p> <p>Significant information is provided in this review indicating the risk of bloody taps, and prompt surgical intervention to improve outcomes.</p> <p>Limitations include lack of assessment after appropriate cessation of antithrombotic therapy.</p>
Moeschler et al, 2016 (63)  Observational Study	<p>A total of 642 percutaneous spinal cord stimulation procedures were performed on 421 unique patients, including 346 spinal cord stimulation trials, 255 spinal cord stimulation implantations, and 41 revision surgeries. Patients had received aspirin or NSAIDs within 7 days of needle placement for 101 procedures (15.7%).</p>	<p>They performed 642 percutaneous spinal cord stimulation procedures, trial, revision, or implantation in 421 patients. No major bleeding complications. They have performed 101 procedures on patients who had taken aspirin or NSAIDs within 7 days of the procedure.</p> <p>There were no bleeding or neurological complications identified in this cohort.</p>	No description of thromboembolic phenomenon was available	<p>Although the incidence of epidural hematoma is low, the development of bleeding complications following spinal cord stimulation lead placement can be devastating. In the present investigation, we identified no cases of epidural hematoma following percutaneous spinal cord stimulation lead placement, including more than 100 patients receiving aspirin or NSAIDs. Future investigations with larger numbers are needed to better define the relationships between periprocedural aspirin and NSAID utilization and bleeding complications.</p>	<p>Even though authors have shown no complications with continuation of NSAIDs or aspirin within 7 days in approximately 16% of the patients, the study consists of a small number of patients.</p> <p>Further, this agrees with older guidance of continuation of NSAIDs and aspirin in the perioperative period, even though it is contradictory to more recent guidelines.</p>

Table 2 cont. *Studies assessing the risk of thrombosis and bleeding with interventional pain management procedures.*

Study/Year	Methods	Results	Thromboembolic Risk	Conclusions by the Study Authors	Author Conclusions of the Review
Petraglia et al, 2016 (77)  Observational Study	Of the 8,326 patients meeting inclusion criteria receiving spinal cord stimulation, 5,458 were percutaneous and 2,868 were paddle leads. The overall incidence of spinal cord injury was 177 or 2.13% with percutaneous lead placement attributing to 128 or 2.35% incidences versus paddle leads contributing to 49 or 1.71% incidence.	Overall incidence of spinal hematoma was 59 or 0.71% with percutaneous contributing to 41 or 0.75% incidence versus paddle lead contributing to 18 or 0.63% incidence.  There was no significant difference between the groups with patients in the percutaneous group and in the paddle group experiencing spinal hematoma.	No description of thromboembolic phenomenon was available	Authors concluded that this study showed overall a low incidence supporting that spinal cord stimulation is a safe procedure.	This is a large database in the United States; however, the study was up from 2000 to 2009. There seems to be an exponential increase of spinal cord stimulation placements since 2009; consequently, this data may not reflect present literature.

NSAIDs: nonsteroidal anti-inflammatory drugs; MRI: magnetic resonance imaging; SEH: spinal epidural hematoma; INR: international normalized ratio; ASIPP: American Society of Interventional Pain Physicians; ASRA: American Society of Regional Anesthesia

Table 3. *Thromboembolic and cardiovascular complications related to discontinuation of antiplatelet or anticoagulation therapy.*

Study	Type of Study	Complications
Endres et al (56)	Observational report of interventional techniques	<ul style="list-style-type: none"> <li>• 2 patients died (one from fatal myocardial infarction and one with fatal stroke) with discontinuation of Warfarin</li> <li>• 5 suffered strokes</li> <li>• 1 suffered pulmonary embolism</li> <li>• 1 suffered myocardial infarction</li> </ul>
Kumar et al (59)	Case report of dorsal column stimulator trial	<ul style="list-style-type: none"> <li>• Pulmonary embolism without lasting complications</li> </ul>
Linn et al (62)	Case report of L5/S1 epidural steroid injection	<ul style="list-style-type: none"> <li>• Right middle cerebral artery infarction with persistent left hemiparesis, neglect, and dysarthria</li> </ul>
Manchikanti et al (50)	Mail in survey	<ul style="list-style-type: none"> <li>• Reports of epidural hematoma: 55</li> <li>• Reports of thromboembolic complications: 162</li> </ul>
Manchikanti et al (68)	Case report and literature review of interventional techniques	<ul style="list-style-type: none"> <li>• 2 cases of thromboembolic complications with cessation of antithrombotic therapy.</li> </ul>

al (57), including 14 publications assessed the role of antithrombotics in interventional pain management. They showed that procedures involving interlaminar access carry a nonzero risk of hemorrhagic complications, regardless of whether anticoagulants are seized or continued. For other procedures, hemorrhagic complications have not been reported, and case series indicate that they are safe when performed in patients who continue anticoagulants. Among the reports they reviewed, 3 of them reported the adverse effects of ceasing anticoagulants, with serious consequences, including death being possible. They concluded that other than for interlaminar procedures, the evidence does not support the view that anticoagulant and antiplatelet medication must be ceased before image-guided spine pain procedures.

Bleeding complications and epidural hematomas have been reported with epidural injections, acupuncture, dry needling, spinal cord stimulation lead placement, percutaneous kyphoplasty, epiduroscopic laser decompression, and pulsed radiofrequency, in patients without antithrombotic therapy, with antithrombotic therapy withheld for appropriate duration, and with antithrombotic therapy continued.

Appendix Table 1 shows reports of bleeding complications and epidural hematoma associated without antithrombotic therapy with interventional procedures. There were a total of 31 epidural hematomas identified in patients who have not received any antithrombotic therapy (66,68,70,94,132,135,137,142,144-147,149,153,155,156,158,160,161,170,172-174,176,177,187,188,198,203,205). Of these, there

were 11 cervical epidural hematomas (66,68,70,135,137,147,155,170,173,187,188), 10 resulting from cervical interlaminar epidurals (66,68,70,135,137,155,170,173,188,189), and one from cervical transforaminal epidurals (147). Among the lumbar, there were 2 lumbar epidural hematomas with lumbar interlaminar epidural injections (145,177), 3 lumbar epidural hematomas related to lumbar transforaminal epidurals (132,174,205), and one cyst hematoma related to a lumbar transforaminal (175). There was a lumbar epidural hematoma secondary to percutaneous epidural neuroplasty (198). There were 3 epidural hematomas secondary to spinal cord stimulation lead placement (156,158,203) and one due to kyphoplasty (176). Further, due to acupuncture, there were 7 epidural hematomas (144,146,149,153,160,161,172). Of these, 3 were in the cervical region (146,149,172), one was in the thoracic region (153), and 3 were in the lumbar region (144,160,161). Similarly, chiropractic care also contributed to a total of 2 epidural hematomas in the cervical region (94,142). Overall, of the 30 epidural hematomas, 17 were related to epidural injections (66,68,70,132,135,137,145,147,155,170,173-175,177,187,188,205), one related to kyphoplasty (176), one related to percutaneous epidural neuroplasty (198), and 3 were related to spinal cord stimulation (156,158,203), totaling 22 of 30 for interventional techniques including spinal cord stimulation.

Appendix Table 2 shows reports of bleeding complications and epidural hematoma in patients after discontinuation of antiplatelet/anticoagulant therapy during interventional procedures. There was a total of 17 epidural hematomas after discontinuation of anticoagulant and/or antiplatelet therapy (65,68,69,71,88,91,92,98,133,139-141,143,179,180,195), of which the highest number was following lumbar interlaminar epidurals of 7 (69,71,92,98,133,140,141), followed by cervical interlaminar epidurals with 4 (68,88,143,179), followed by lumbar transforaminal of 2 (180), and thoracic interlaminar of one (65). The results also showed 3 epidural hematomas due to spinal cord stimulator lead placement (91,139,195). The discontinuation of antithrombotics included aspirin alone in 5 cases, with other antithrombotics in 2 cases, and with other NSAIDs in one case; clopidogrel (Plavix) alone in 2 cases and in combination with other antithrombotics in one case; warfarin (Coumadin) alone in 2 cases, and in combination with other drugs or

bridge therapy, in 3 cases; NSAIDs with omega-3 fatty acids in one case; enoxaparin (Lovenox®) in combination with other antithrombotics in 2 cases; dabigatran (Pradaxa) in one case; and Ginko in one case. Appendix Table 3 shows reports assessing bleeding complication and epidural hematomas in patients with continuation of antiplatelet/anticoagulant therapy or drugs that potentially increase bleeding with interventional procedures. There was a total of 15 epidural hematomas and one gluteus maximus hematoma following a sacroiliac joint injection in patients with continuation of antiplatelet or anticoagulant therapy (66,67,89-91,93,134,152,154,179,181,183,184,190,191,204). An overwhelming number of complications were related to cervical interlaminar epidurals with 7 developing epidural hematoma (66,67,90,134,152,179,191) and one developing subdural hematoma (183) and one epidural hematoma following cervical transforaminal injection (181).

There were 2 lumbar epidural injections developing lumbar epidural hematomas (93,190), one caudal epidural injection developing lumbar epidural hematoma (154), 2 spinal cord stimulators (89,91), one sacroiliac joint injection (204), and one kyphoplasty (184). In this category, aspirin alone was used in 5 cases and in combination of the other drugs in 5 cases; clopidogrel (Plavix) alone was used in one case, whereas it was in combination with other drugs in 2 cases; warfarin (Coumadin) was used in one case in combination with aspirin; indomethacin (Indocin®, Tivorbex®), NSAIDs, cilostazol (Pletal), and ketorolac (Toradol®) were all used in one patient; and fish oil was used in 3 cases. Table 4 shows reports of bleeding complications and incidence of epidural hematoma in patients undergoing epidural injections, spinal cord stimulation lead placement, and kyphoplasty, chiropractic management, and acupuncture. Overall, the number of epidural hematomas reported was the highest in light of absence of anticoagulant therapy (30), followed by appropriate discontinued category (17), and the least in patients with continuation of anticoagulant or antiplatelet therapy (15) with a total of 62.

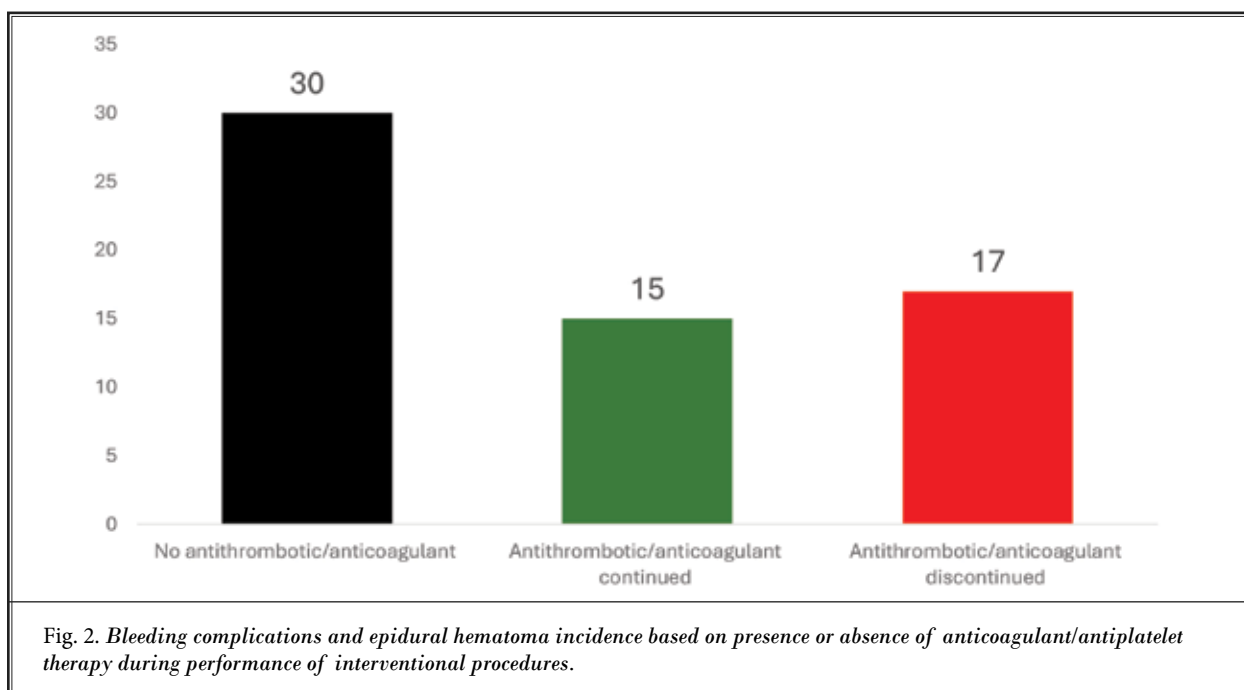
Figure 2 shows reports of epidural hematoma based on no antithrombotic therapy, antithrombotic therapy continued, and antithrombotic therapy discontinued.

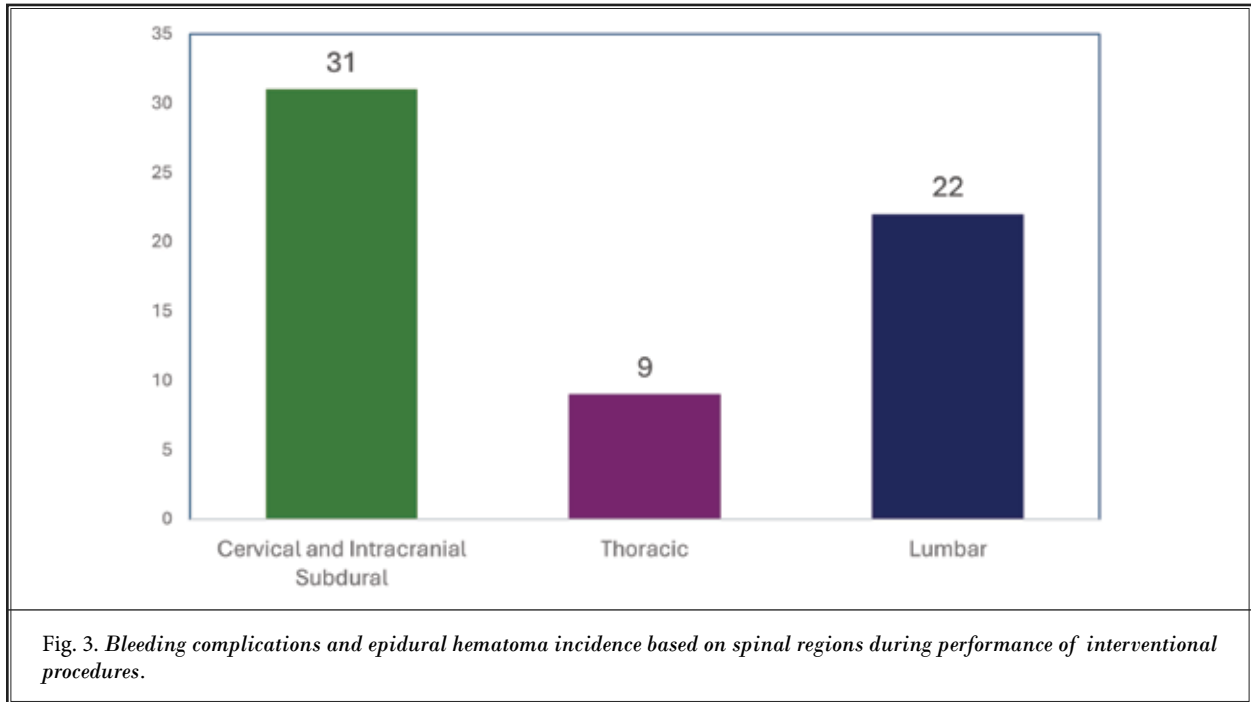
Figure 3 shows reports of epidural hematoma stratified by spinal region.

## Antiplatelet and Anticoagulant Therapy in Patients Undergoing Interventional Techniques

Table 4. Reports of bleeding complications with epidural hematoma in patients undergoing epidural injections, spinal cord stimulation, and kyphoplasty.

	No Anticoagulant Therapy	Anticoagulant Discontinued	Anticoagulant Continued	Total
<b>CERVICAL AND INTRACRANIAL COMPLICATIONS</b>				
Cervical interlaminar injections	10	5	8	23
Cervical transforaminal injections	1	0	1	2
Acupuncture	3	0	0	3
Spinal cord stimulation	1	0	0	1
Chiropractic/Dry needling	2	0	0	2
TOTAL	17	5	9	31
<b>THORACIC COMPLICATIONS</b>				
Thoracic interlaminar injections	0	1	0	1
Acupuncture	1	0	0	1
Spinal cord stimulation	1	2	2	5
Percutaneous kyphoplasty	1	0	1	2
TOTAL	3	3	3	9
<b>LUMBAR COMPLICATIONS</b>				
Lumbar interlaminar injections	2	7	2	11
Lumbar transforaminal injections	3	2	0	5
Caudal epidural injections	0	0	1	1
Acupuncture	3	0	0	3
Spinal cord stimulation	1	0	0	1
Percutaneous epidural neuroplasty	1	0	0	1
TOTAL	10	9	3	22
<b>COMBINED TOTALS</b>	<b>30</b>	<b>17</b>	<b>15</b>	<b>62</b>





## 4.0 PHARMACOLOGIC ASPECTS AND HEMOSTASIS MONITORING

The main categories of antiplatelet and anticoagulants are described as: platelet inhibitors that interfere with platelet aggregation (clumping) and thrombus formation, anticoagulants interfering with formation of clotting, thereby reducing fibrin formation, and preventing clots from forming and expanding and fibrinolytics which interfere with the fully formed clot.

### 4.1 Antithrombotics

#### 4.1.1 NSAIDs and Aspirin

NSAIDs exert analgesic effects via inhibition of the enzymes Cyclooxygenase-1 (COX-1) and Cyclooxygenase-2 (COX-2), ultimately inhibiting prostaglandin production to decrease inflammation. Thromboxane A2 is a potent thrombus activator that is produced via COX-1 enzymatic activity. Aspirin is an irreversible inhibitor of COX-1 and has significant clinical benefits for preventing thrombus formation due to its effects on the production of thromboxane A2. In response to the pharmacologic effects of aspirin, endothelial cells produce more prostacyclin but do not increase production of thromboxane as there are no nuclei in platelets. Thus, there is a greater percent of prostacyclin to thromboxane, leading to thinning of the blood. In a small portion of patients, elevated bleeding risk is a concern, but adverse effects are rare. Prostacyclin synthesis from vascular endothelial cells is dependent on COX-2 and has anti-platelet effects; high doses of aspirin (325 mg) reduce prostacyclin production which diminishes the anti-platelet effect of low dose aspirin (81 mg). The anti-platelet effects of

low-dose aspirin last for 7-10 days, as platelets in the bone marrow must be renewed for clotting to resume. Low-dose aspirin therapy is a well-established method that is used to reduce the risk of cardiovascular events in patients with acute coronary syndrome, cerebral infarct, or occlusive vascular disease (37,209). However, recently published large-scale evidence (37) shows that aspirin therapy (81 mg) for primary prevention of cardiovascular events demonstrates benefits, but with an increased risk of bleeding. The pharmacokinetic and pharmacodynamic characteristics of aspirin and NSAIDs are shown in Table 5.

Aside from aspirin, the platelet effects of other NSAIDs are related to systemic plasma concentrations and are influenced by the clearance of these medications; it takes approximately 5 half-lives for these medications to be eliminated from the body. Recently, recommendations (14) have been revised on continuing or discontinuing aspirin use in the perioperative period for interventional pain procedures. The decision to continue or discontinue is made based on the initial reason for aspirin therapy, various risk factors including vascular anatomy of the procedural area, level of invasiveness of the procedure and potential adverse sequelae associated with the development of perioperative bleeding. The major concern with stopping aspirin prior to these procedures is the risk of thromboembolism. According to the available evidence in the literature, aspirin (81 mg) discontinuation for 4 days prior to a procedure may be sufficient to avoid the development of thromboembolism. Different NSAIDs have different recommended discontinuation periods as determined by ASRA. For diclofenac, ibuprofen and Ketorolac, the

Table 5. Characteristics of aspirin and NSAIDs.

	Aspirin (Oral Low Dose)	NSAIDS
Target	COX-1 irreversible	COX-1 reversible, COX-2
Time to maximum effect	0.5 hours	Variable
Plasma half life	0.5 hours	Ranges from 1 to 72 hours
Renal elimination	+	+
Time to 50% of platelet function recovery	3 days	1 day
Hours to maximum plasma concentration level	0.5 hours	About 0.5 hours
Metabolism location	Liver	Liver
Drug Bioavailability	60%	50-95%
Antihemostatic effect	++	+

NSAID = non-steroidal anti-inflammatory drug; COX = cyclo-oxygenase

Rating of antihemostatic effect and renal elimination: (+) = insignificant; + = low; ++ = moderate; +++ = pronounced; ++++ = high

<https://www.painphysicianjournal.com/current/pdf?article=NjEwMw%3D%3D&journal=118>

recommended discontinuation is one day. For etodolac and indomethacin, the recommended discontinuation time is 2 days. Meloxicam and Naprosyn should be stopped for 4 days, Nabumetone should be stopped for 6 and Piroxicam and Oxaprozin should be stopped for 10 days. Aside from these recommendations, the evidence for stopping non-steroidal anti-inflammatory agents aside from aspirin appears to be very limited. Patients may not be amenable to the discontinuation of these drugs due to increased pain levels. Therefore, clinicians use their judgment to decide whether to continue or discontinue these drugs prior to performing an interventional technique.

#### 4.1.2 Adenosine diphosphate (ADP) Receptor Inhibitors

ADP-receptor inhibitors function by inhibiting platelet aggregation. Clopidogrel (Plavix), Prasugrel (Effient), Ticlopidine (Ticlid) and Ticagrelor (Brilinta) are all drugs in this category. Table 6 shows pharmacokinetics and pharmacodynamics of these ADP-receptor inhibitors.

Clopidogrel (Plavix) is the prototypical thienopyridine drug that inhibits the P2Y<sub>12</sub> receptor. The P2Y<sub>12</sub> receptor is activated by the binding of ADP and this binding promotes platelet aggregation; thus, blockage of this receptor will inhibit platelet aggregation. The maximal aggregation inhibitory effects of clopidogrel

are reached within 3 to 7 days – this is dependent on the dosage schedule. After the drug is discontinued, 50% recovery of platelet inhibition occurs after 3 days, and 100% recovery is achieved after 7 days (210). In a study conducted by Moshfegh et al (210), 80% of subjects demonstrated normal platelet aggregation by the 4th day. Another study evaluated the time to recovery of platelet function after cessation of aspirin in volunteers and in surgical patients (163). Platelet function was recovered in 3 days in volunteers and within 4-6 days in surgical patients. In this particular study, all the subjects had at least 85% of platelet aggregation restored by day 6.

Ticlopidine (Ticlid) is another member of the thienopyridine group and maximal aggregation with the use of this drug is achieved after 8 to 11 days of a 500 mg daily dosage. Because the drug irreversibly inhibits platelet function, there is still a lingering effect after a withdrawal period of 72 hours (211).

Prasugrel (Effient) acts at the platelet's purine receptors and antagonizes ADP. This drug has higher irreversible antiplatelet activity as compared to clopidogrel; peak effect of the drug is reached after one hour. Therefore, half of the platelets will be inhibited within the first hour of taking the first dose of the drug. After 3 to 5 days of therapy, 70% of platelets are inhibited as a steady state of inhibition is reached (212). Because prasugrel is a prodrug, it is rapid to its active and inac-

Table 6. Pharmacokinetic and pharmacodynamic comparison of ADP-receptor inhibitors.

	Clopidogrel (Plavix)	Prasugrel (Effient)	Ticlopidine (Ticlid)	Ticagrelor (Brilinta)
Target	P2Y <sub>12</sub> ADP	P2Y <sub>12</sub> ADP	P2Y <sub>12</sub> ADP, inhibition of liver CYP2C19 and CYP2B6	P2Y <sub>12</sub> ADP
Antithrombotic Activity	++	+++	++	++++
Time to C <sub>max</sub>	3-7 days	3-5 days	8-11 days	2-4 hours
Time to maximum effect	4 hours to 4 days	1 hour	3-5 days	2.5 hours
CYP metabolism	CYP1A2, CYP2B6, CYP2C9, CYP2C19 and CYP3A4/5	CYP450-mediated (mainly CYP3A4 and CYP2B6)	Cytochromes P450	CYP3A4
Bioavailability	> 50%	≥ 79%	> 80%	36%
Protein binding	94-98%	Active metabolite: ~98%	98%	> 99.7%
Plasma half-life	7-8 hours (inactive metabolite)	~7 hours (ranges from 2 hours to 15 hours)	12 hours for a single dose or 4-5 days for repeated dose	7 hours for ticagrelor, 8.5 hours for active metabolite AR-C124910XX
Drug elimination	50% kidney, 46% biliary	Urine (~68% inactive metabolites); feces (27% inactive metabolites)	Renal and fecal	Biliary
Time to 50% of platelet function recovery	3 days	3 days	6 days	1.5 days

CYP: cytochrome P450; ADP: Adenosine diphosphate; C<sub>max</sub>: maximum concentration



tive metabolites, which have varying elimination rates. The active metabolites specifically have an elimination half-life of 7 hours but can range from 2-15 hours (213).

Ticagrelor (Brilinta) works by directly inhibiting P2Y<sub>12</sub> receptors (214-216). Although Ticagrelor is metabolized to active metabolites, the original compound is the component that is responsible for the majority of the drug's inhibitory effects (215,216). One advantage of Ticagrelor is its rapid effect; peak platelet inhibition is achieved after 2 to 4 hours of administration of the drug. This medication is converted into active metabolites in the liver which are then eliminated by the kidneys (217). This drug also causes decreased activation of glycoprotein IIb/IIIa receptors leading to decreased fibrinogen fixation and platelet crosslinking.

#### **4.1.3 Phosphodiesterase Inhibitors**

Cilostazol (Pletal) and Dipyridamole (Persantine) are two drugs in the phosphodiesterase inhibitor class that work by selectively inhibiting phosphodiesterase. The inhibition of phosphodiesterase leads to an increase in intracellular cyclic adenosine monophosphate (cAMP) and subsequent inhibition of platelet aggregation (218). Dipyridamole also blocks thromboxane synthase and the thromboxane receptor and inhibits the cellular reuptake of adenosine into platelets, red blood cells and endothelial cells. These actions lead to increased adenosine in the extracellular space and decreased formation of cytokines and proliferation of smooth muscle cells. Dipyridamole is absorbed in the gastrointestinal tract and its absorption is pH dependent. Drugs that alter the potential of hydrogen (pH) in the gastrointestinal tract, such as gastric acid suppressions and proton pump inhibitors can diminish the absorption of Dipyridamole. This decrease in absorption can be prevented by buffered additives that are incorporated into the medication (219). In addition to its effects on phosphodiesterase, cilostazol also inhibits PDE3A, which is selective to vascular smooth muscle cells, inhibition results in vasodilation. Cilostazol is administered twice a day at 100 mg and reaches maximum plasma concentration after 3 hours. It is metabolized in the liver and is excreted in the urine; its renal excretory properties make it contraindicated in patients with severe renal insufficiency (220). Currently, phosphodiesterase inhibitors are considered safe to continue during interventional procedures, but risk may increase with concurrent use of aspirin. There is limited data on the risk of perioperative surgical bleeding with cilostazol (14) and there are no standard perioperative guidelines

available on the subject (221). After discontinuation, less than 5% of cilostazol remains in plasma and improvements in platelet aggregation have been seen despite continuous prior dosing (162,222).

#### **4.1.4 Glycoprotein GPIIb/IIIa Inhibitors**

The final component of platelet aggregation is the glycoprotein IIb/IIIa receptor – inhibition of this receptor will lead to reversible platelet aggregation (223). Medications such as abciximab (ReoPro®), tirofiban (Aggrastat) and eptifibatide (Integrilin®) function to inhibit this receptor.

Abciximab is a Fab fragment of a monoclonal antibody directed to destroy the GPIIb receptor. This drug can inhibit over 80% of ADP-induced platelet aggregation. Abciximab when administered intravenously (IV) can bind quickly to platelets with high affinity. Abciximab also inhibits thrombin generation. Eptifibatide is a cyclic peptide inhibitor of the fibrinogen binding site on the GPIIb receptor. Tirofiban is also a glycoprotein IIb/IIIa receptor inhibitor and reaches its maximum efficacy at the 4-hour mark after administration. After 4 hours, tirofiban demonstrates 50-80% inhibition of platelet aggregation (224). After stopping the IV infusion, platelet function will normalize after 8-24 hours.

#### **4.2 Direct Oral Anticoagulants (DOACs)**

Direct oral anticoagulants (DOACs) include Factor IIa, dabigatran (Pradaxa); and factor Xa, apixaban (Eliquis), rivaroxaban (Xarelto), and Edoxaban (Savaysa, Lixiana) inhibitors (114).

Dabigatran (Pradaxa) is the commonly used Factor IIa inhibitor or direct thrombin inhibitor. Dabigatran etexilate is an oral anticoagulant and prodrug that is converted to dabigatran in plasma after administration. After an oral dose, maximal effects are observed within 2 to 4 hours and the plasma half-life is 13 hours on average (225). The dose recommendations of dabigatran are dependent on the renal sufficiency of the patient receiving the medication. In patients with a creatinine clearance of greater than 30mL/minute, 150 mg is given orally twice a day. For patients with a creatinine clearance lower than 30mL/minute, 75 mg given twice daily is recommended. Because dabigatran functions via factor inhibition and not clotting factor depletion, the administration of clotting factors in an effort to reverse the effects of the drug is less effective. Dabigatran is primarily renally excreted and the time to excretion varies depending on the renal sufficiency of the patient. In patients with normal kidney function,

the drug is excreted 1-2 days after discontinuation. However, there exists one case report with epidural hematoma despite its continuation for 7 days prior to interventional techniques (101). Lagerkranser and Lindquist (82) also reported on a case of spinal hematoma out of 160 cases.

Direct factor Xa inhibitors such as Rivaroxaban (Xarelto), Apixaban (Eliquis), Endoxaban (Savaysa, Lixiana), have been frequently used in the United States (Table 7). Apixaban (Eliquis) and rivaroxaban (Xarelto) are the only two drugs in this class that can be reversed by Andexanet alfa (Andexxa®), a recombinant coagulation factor Xa that has been approved by the U.S. Food and Drug Administration (FDA) for urgent reversal of anticoagulant effects in 2018 (226).

Rivaroxaban (Xarelto) is cleared by both the liver and kidney, with around one-third of the drug being active with each route of metabolism. Because the drug has a dual route of clearance, accumulation is less likely

with rivaroxaban than with other medications that have only liver or only kidney clearance properties. Rivaroxaban is orally administered with a half-life of 5.7 to 9.2 hours and plasma protein binding of the drug is 92-95%. After administration, one-third of the dose is excreted in the urine and the remaining two-thirds of the dose is excreted as an inactive metabolite in the feces and the urine. Concomitant use of rivaroxaban with medications that are P-glycoprotein inhibitors or metabolized by CYP3A4 increases the potential for drug interactions (227).

Apixaban (Eliquis) is like rivaroxaban in that it also is a specific factor Xa inhibitor. It has a rapid rate of absorption, and maximal effects are observed in 1-2 hours (228,229). Apixaban has an oral availability of 45% and has a relatively complex elimination pathway involving direct renal and intestinal excretion; however, the drug is primarily excreted through the intestines (229,230). Endoxaban (Savaysa or Lixiana) is a drug that was ap-

Table 7. Pharmacokinetic properties of direct oral anticoagulants (DOACs).

	<b>Dabigatran (Pradaxa)</b>	<b>Rivaroxaban (Xarelto)</b>	<b>Apixaban (Eliquis)</b>	<b>Endoxaban (Savaysa, Lixiana)</b>
Target	Factor IIa	Factor Xa	Factor Xa	Factor Xa
Prodrug	Yes	No	No	No
Tmax (h)	1.0–3.0	2.0–4.0	3.0–4.0	1.0–2.0
Half-life (h)	12-17 h	5–9: healthy individuals 11–13: elderly	8–15: healthy individuals	10–14
Bioavailability	3–7% pH sensitive	For 2.5 mg and 10 mg: 80–100% (fasting or fed) For 15-20 mg: 66%: (fasting) almost 100% (fed)	± 50%	62%
Metabolism	Conjugation	CYP-dependent and independent mechanism	CYP-dependent mechanism (25%)	CYP-dependent (<10%)
Active metabolites	Yes - acylglucuronides	No	No	Yes (< 15%)
Elimination of absorbed dose	80% renal 20% bile (glucuronide conjugation)	33% unchanged via the kidney 66% metabolized in the liver into inactive metabolites then eliminated via the kidney or the colon in an approximate 50% ratio	27% renal 73% through the liver, the residue is excreted by the hepatobiliary route	50% renal 50% metabolism and biliary/intestinal excretion
Reversal Agent	Idarucizumab	Andexanet alfa	Andexanet alfa	Andexanet alfa
CYP substrate	No	CYP3A4, CYP2J2	CYP3A4	CYP3A4 (< 5%)
P-gp substrate	DE: Yes	Yes	Yes	Yes
BRCP substrate	No	Yes	Yes	No

CYP: cytochrome P450; Tmax: time to reach peak concentration; P-gp: P-glycoprotein; BRCP: Breast cancer resistance protein

Adapted and modified from: Dubois V, Dincq AS, Douxfils J, et al. Perioperative management of patients on direct oral anticoagulants. *Thromb J* 2017; 15:14 (124).

proved for prevention of venous thromboembolisms in patients undergoing lower limb orthopedic surgery in 2011. Edoxaban is an oral factor Xa inhibitor that exerts its effects by inhibiting free factor A and prothrombinase activity. In addition to this primary indication, it has also been approved for the prevention of stroke and systemic embolism. Peak plasma concentrations are reached 1.5 hours after oral administration, and it has an elimination half-life of 10-14 hours when taken at 60 mg once a day. Edoxaban is excreted by the liver and the kidney, is orally available and is not removed by dialysis (231).

#### 4.3 Warfarin

Oral anticoagulants function by inhibiting the synthesis of the vitamin K-dependent clotting factors II, VII, IX and X. Warfarin (Coumadin) is an anticoagulant drug that exerts its effects by inhibiting the gamma-carboxylation of glutamate residues in prothrombin and factors VII, IX and X. Consequently, these coagulation factor molecules are rendered biologically inactive. Warfarin also functions by inhibiting epoxide reductase, which is an enzyme that catalyzes the gamma-carboxylation reaction. This inhibition of epoxide reductase prevents the metabolism of the inactive vitamin K epoxide to its active hydroquinone form. The effects of oral anticoagulants are not apparently until previously existing clotting factor turnover has occurred because synthesis of the clotting factors is the primary target of drugs such as warfarin. Factor VII has a half-life of 6-8 hours while Factor II has a half-life of 50-80 hours (232). Warfarin has a slow onset of action because existing functioning clotting factors must be depleted; maximal effects of warfarin are observed at 3-5 days post administration. The serum concentration and potency of warfarin is monitored by PT and INR, which is a normalized ratio of the patient's PT to that of a control sample (232). There are many factors that can modify a patient's response to warfarin, including age, female gender, and preexisting medical conditions such as hepatic, cardiac, and renal disease. For example, Asian patients have a higher sensitivity to warfarin and require lower doses than patients of European descent (232). Dietary changes can also influence a patient's response to warfarin – patients are advised to avoid grapefruit and cranberry products, eat a consistent amount of green leafy vegetables and other vitamin K containing foods so as to not disturb their clotting ability. Patients are also advised to limit their herbal supplement intake of garlic, ginger, ginkgo biloba, gin-

seng, and fish oil. Vitamin K can be used as a reversal agent after administration of warfarin, but its use is accompanied by many side effects.

#### 4.4 Low-Molecular Weight Heparin

Low molecular weight heparins function by inhibiting the coagulation cascade by binding to antithrombin. This binding induces a conformational change in antithrombin, which propagates the inhibition of factor Xa. The advantages of low molecular weight heparins include relatively high bioavailability, longer half-life and once a day dosing. After administration, maximum efficacy levels are seen after about 3-4 hours and the drug is eliminated from the body after 4-6 hours in patients with sufficient renal function (233). High molecular weight heparins (HMWH) function by catalyzing the inhibition of factors IXa, Xa and thrombin. They also significantly enhance antithrombin III activity by inducing a conformational change in antithrombin to expose its reactive binding site. The dosage and concentration of HMWHs is monitored via the partial thromboplastin time (PTT). Because HMWH has a large molecular weight, it is not absorbed in the gastrointestinal tract so it must be administered through IV or subcutaneous injections. The drug also has a relatively short-half life so multiple injections or infusions will be required, and its use is best suited for the inpatient setting. Unfractionated heparin, which is considered a HMWH, is often used in patients with chronic kidney disease and severe renal insufficiency because it has a short half-life, allowing for the anticoagulant effect to wear off within 1-4 hours. This short half-life allows for the drug to be used in patients with renal clearance impairments who have high hemorrhagic risk (234). Another advantage of unfractionated heparin is the fact that it has a reversal agent called protamine sulfate. Protamine sulfate is a specific antagonist that exerts its effect via neutralization of heparin-induced coagulation (235). Unfractionated heparin forms a salt aggregate when exposed to protamine – this salt aggregate is inactive, has no anticoagulant properties and can neutralize unfractionated heparin within 5 minutes (236).

#### 4.5 Herbal/Alternative Therapies

##### 4.5.1 Herbal Products

Two decades ago, a landmark U.S. study determined over one-third of US adults use herbal supplements, yet 70% did not report that use to anesthesia providers preoperatively prior to surgery or interven-

tional pain procedures (237). Many herbal products can alter the coagulation cascade resulting in increased risk of bleeding. In this regard, these products can have varied uptake and duration of action as they are not prepared to the governmental standards of drugs, leading to the American Society of Anesthesiologists (ASA) recommending all herbal products be halted 2-3 weeks prior to elective surgery or pain procedures (238). As an example, garlic possesses a dose-dependent effect on bleeding, as it contains a compound called ajoene. Derived from allicin, the compound that provides garlic's flavor, ajoene inhibits granule release and fibrinogen binding and alters aggregation of platelets. Ginkgo Biloba through its components, including flavonol glycosides and terpene glycosides, antagonize platelet-activating factor (PAF) and collagen resulting in inhibition of platelet aggregation with several reports of spontaneous bleeding. Ginseng, through the major active ingredient ginsenosides, reduces the effects of warfarin, declining peak INR levels induce cytochrome P450 enzymes to increase the metabolism of warfarin and thus reduce its effect (239-241). Ongoing research has also determined many other herbal products can be potentially linked to increased bleeding risks. Some of these include Cordyceps sinensis, echinacea, and aloe vera which have been clearly linked to surgical bleeding. In patients taking anticoagulants, current literature indicates garlic, ginkgo biloba, chondroitin-glucosamine, melatonin, turmeric, bilberry, chamomile, fenugreek, milk thistle, and peppermint can further increase bleeding risk (242).

#### **4.5.2 Fish Oil**

Fish oil possesses omega-3 fatty acids, which can increase bleeding risk; however, a large study compared bleeding risks for patients on fish oil and found no difference in bleeding risks when compared to placebo groups (243). It should also be noted that a 2006 systematic review of 9 studies involving 2,612 patients (including some with patients on aspirin or warfarin) reported either no bleeding or no consistent association between dosage of omega-3 fatty acids and bleeding risk.

In a 2024 publication, Chen et al (244) examined the effects of fish oil supplements on the clinical course of cardiovascular disease from a healthy state to atrial fibrillation, major adverse cardiovascular events, and subsequently death. In this large study, the results showed the regular use of fish oil supplements had different roles in the transition from healthy status

to atrial fibrillation, to major adverse cardiovascular events, and then to death. The study results showed in people with no known cardiovascular disease, regular use of fish oil supplements was associated with an increased relative risk of atrial fibrillation and stroke. In addition, the results also showed that in people with known cardiovascular disease, the beneficial effects of fish oil supplements were seen on transitions from atrial fibrillation to major adverse cardiovascular events, atrial fibrillation to myocardial infarction, and heart failure to death. Thus, evidence continues to be controversial and further studies are needed to determine the precise mechanisms for the development and prognosis of cardiovascular disease events with regular use of fish oil supplements, along with effect of fish oil on bleeding risk alone or in combination with other anticoagulants or antiplatelets.

#### **4.5.3 Vitamins**

Vitamins can also affect bleeding risk by inhibiting platelet aggregation. Vitamin E, through tocopherol quinone, is an oxidized form of alpha-tocopherol, which possesses anticoagulant activity by interfering with vitamin K metabolism (245). Extremely high doses of vitamin D3, vitamin A, vitamin B3, vitamin C, Co-Q10, and arginine are associated with increased risk of bleeding and can interact with warfarin resulting in increased bleeding risk.

#### **4.5.4 Selective Serotonin Reuptake Inhibitors (SSRIs)**

Best practice guidance on the use of SSRIs, which inhibit the reuptake of serotonin, is controversial, since SSRIs can increase bleeding risk but can also potentially lead to a relapse of clinical depression if discontinued (246). It should also be noted that SSRIs can interact with anesthetic agents, resulting potentially in hypotension, arrhythmias, altered thermoregulation including postoperative shivering, and postoperative confusion (247).

#### **4.6 Hemostasis Monitoring**

There are multiple standard tests that are used to monitor hemostasis, including platelet count, activated partial thromboplastin time (aPTT) and INR. A normal platelet count ranges from 150,000 to 450,000 platelets per mL of blood. Platelet counts above 450,000 is considered to be thrombocytosis and less than 150,000 is thrombocytopenia. A platelet count below 20,000 is severe thrombocytopenia, potentially causing danger-

ous internal bleeding. Platelet counts of greater than 50,000 are recommended for avoiding life-threatening complications, greater than 80,000 for stronger indications and greater than 100,000 for weaker indications (73). The normal range of INR is considered to be 0.9 to 1.2. However, in practice, in patients on anticoagulant therapy with Warfarin, low risk procedures may be performed with an INR of  $\leq 3.0$  with 1 to 2 days of cessation if warranted, for moderate or intermediate risk procedures an INR of  $\leq 2.0$  is recommended with 2 to 3 days of cessation of Warfarin therapy if warranted, and for high-risk procedures an INR of  $< 1.5$  is recommended with cessation of Warfarin therapy for 3 to 5 days if warranted.

Advanced hemostatic monitoring tests include multiple viscoelastic tests such as thromboelastography or thromboelastometry which are widely used to evaluate liver disease (192). However, when this parameter was studied for safe epidural catheter removal, it was concluded that the tests were not well validated and there were frequent false negative test results (206,207). Even then, a clearly abnormal curve indicates deranged hemostasis and must be taken seriously (207,208).

#### **4.7 Reversal of Antiplatelet and Anticoagulant Agents**

Interventional pain procedures may necessitate reversal of anticoagulation, especially in urgent situations. Reversal agents can be nonspecific or specific depending on the anticoagulation used. Reversal carries the risk of thromboembolic events, commonly due to the patient's underlying disease. Therefore, careful consideration should be given to the risks and benefits of available reversal agents.

##### **4.7.1 Specific Reversal Agents**

Non-vitamin K antagonist oral anticoagulants target specific factors of the coagulation cascade. There are two specific reversal agents that are U.S. FDA-approved and commercially available, both targeting reversal of non-vitamin K antagonist oral anticoagulants.

Idarucizumab (PRAXBIND®) is approved for the reversal of dabigatran, the only such agent for reversal of direct thrombin (factor IIa) inhibitors. While there is no literature to our knowledge on the use of idarucizumab for interventional pain procedures, there is a reported case of successful treatment of a spontaneous cervical epidural hematoma with idarucizumab in a patient taking dabigatran (239). Idarucizumab can effectively reverse dabigatran within minutes and has

no absolute contraindications (248). However, caution should be exercised for patients with hereditary fructose intolerance due to sorbitol use in the formulation (249). Adverse reactions in patients with hereditary fructose intolerance have been reported and may include hypoglycemia, hypophosphatemia, metabolic acidosis, increase in uric acid, acute liver failure, and death. Idarucizumab has been safely used in the geriatric population (65+ years of age), and there is no dose adjustment required for patients with renal impairment. This agent has not been evaluated for use in pregnant or breastfeeding patients. Dabigatran can be resumed 24 hours post-procedure, as long as the patient is medically stable and cleared.

Coagulation factor Xa (recombinant), inactivated-zhzo, or Andexanet alfa (ANDEXXA), is approved for the reversal of apixaban and rivaroxaban, which are direct factor Xa inhibitors. Andexanet may additionally reverse low molecular-weight heparin (e.g., enoxaparin) and unfractionated heparin due to its ability to bind heparin-antithrombin III complex (250). Of note, andexanet alfa is not FDA-approved for reversal of the factor Xa inhibitor edoxaban, although successful edoxaban reversal with andexanet alfa has been reported (251). In a multicenter prospective trial, andexanet alfa administration showed a 92% reduction of factor Xa inhibition by both apixaban and rivaroxaban (252). A single-center retrospective study demonstrated excellent or good 24h hemostatic control in 78.9% of patients who received andexanet alfa peri-procedurally, mostly for emergent operations (253). There are no absolute contraindications to andexanet alfa. However, its use should be avoided prior to heparinization as andexanet alfa may interfere with heparin's anticoagulant effects. This agent has been safely used in the geriatric population (65+ years of age). Andexanet alfa has not been evaluated for use in pregnant or breastfeeding patients. Patients should resume apixaban or rivaroxaban 24 hours after moderate or intermediate to high-risk procedures, as long as medically stable and cleared. Table 8 shows specific reversal agents for non-vitamin K antagonist oral anticoagulants.

##### **4.7.2 Nonspecific Reversal Agents**

Protamine is most commonly used for reversal of unfractionated heparin perioperatively, achieving reversal effect within minutes (254). Protamine may also be used off-label for low molecular weight heparins reversal, although only achieving partial reversal (255). Signs and symptoms of hypersensitivity should

Table 8. *Specific reversal agents for non-vitamin K antagonist oral anticoagulants.*

Anticoagulants	Reversal Agent	Reversal Agent Mechanism of Action	Reversal Agent Recommended Dose	Considerations* Not Comprehensive
Dabigatran (Pradaxa)	Idarucizumab (PRAXBIND)	Monoclonal antibody fragment with high affinity for dabigatran; sequesters dabigatran from binding and inhibiting thrombin	5 g IV	- Adverse events in patients with hereditary fructose intolerance - Not evaluated in pregnant or breastfeeding patients
Apixaban (Eliquis) Rivaroxaban (Xarelto)	Coagulation factor Xa (recombinant), inactivated-zhzo, also known as Andexanet alfa (ANDEXXA)	Synthetic variant of factor Xa without anticoagulant activity; binds and sequesters factor Xa inhibitors	Low dose Initial IV bolus: 400 mg at a target rate of 30 mg/min Follow-on IV infusion: 4 mg/min for up to 120 minutes (480 mg)  High dose Initial IV bolus: 800 mg at a target rate of 30 mg/min Follow-on IV infusion: 8 mg/min for up to 120 minutes (960 mg)	- Monitor for signs and symptoms of arterial and venous thromboembolic, ischemic events, and cardiac arrest - Avoid prior to heparinization due to binding of heparin-antithrombin III complex - May reverse LMWH - Not evaluated in pregnant or breastfeeding patients

LMWH: low molecular weight heparins; IV = intravenous

be monitored closely in patients at risk. Vitamin K, four-factor prothrombin complex concentrate (PCC), and fresh frozen plasma have traditionally been used for vitamin K antagonists. Vitamin K reversal should be based on INR, and intramuscular or subcutaneous administration should be avoided. PCC has been used off-label for non-vitamin K antagonist oral anticoagulants-related bleeding, especially when specific reversal agents are unavailable. Generally, activated-PCC has been used for dabigatran-related

bleeding and 4-factor PCC for direct factor Xa inhibitor-related bleeding (256). Other hemostatic agents include tranexamic acid, which works by preventing clot lysis. Tranexamic acid has been used to control anticoagulant-related bleeding off-label due to its wide availability and relatively few side effects (257).

While various reversal agents are available, their use should generally be limited to life-threatening bleeding, massive hemorrhage, and emergency procedures.

## 5.0 GUIDELINES AND RECOMMENDATIONS

Cardiovascular disease in the United States continues to be associated with the highest level of mortality. A 2022 updated publication of the American Heart Association (AHA) reported high prevalence rates of cardiovascular disease with stroke as a leading cause of death and morbidity (43). Among various causes, atrial fibrillation was responsible for approximately 20% to 30% of ischemic strokes, especially in older patients (44,45). Despite significant advances made in managing anticoagulant therapy, some patients continue to experience strokes (19,46-48). In addition, estimates also suggest that greater than two-thirds of sudden cardiac events (acute coronary syndrome or sudden cardiac death) and half of the postoperative myocardial infarctions follow initiation of an arterial plaque disruption and associated thrombosis and embolization (258-263). Additionally, the evidence shows that acute coronary syndrome is associated with proinflammatory and prothrombotic states, which involve elevated levels of fibrinogen, C-reactive protein, and plasminogen activator inhibitor (264). Further, in the postoperative period, endogenous catecholamines, increased platelet adhesiveness, and decreased fibrinolysis increase the risk of an acute coronary syndrome (258,262,265).

Thus, multiple factors include coronary artery disease, atherosclerosis, atrial fibrillation, IHD; however, the medical literature mainly focused on atrial fibrillation, mechanical heart valves, and thromboembolic phenomenon (10-12). In addition, these guidelines also focus on high-risk patients for non-interventional cardiac and non-cardiac surgical procedures. Nevertheless, a systematic review (266) showed a 3-fold increased risk for major adverse cardiac events and the risk was magnified in patients with coronary stents.

Based on the available literature, as many as 10% of the patients undergo invasive procedures involving interventional techniques (258,267). Thus, as highlighted, significant risks are faced creating a dilemma for patients and clinicians in reference to whether to continue or interrupt anticoagulant and antiplatelet therapy and avoid cardiovascular, cerebrovascular, and peripheral vascular thrombotic effects.

### 5.1 Risks of Continuation and Cessation in Perioperative Period

There is evidence that discontinuation or interruption of antiplatelet therapy may result in hypercoagulability with thrombosis or bleeding (266,268-277). Studies have determined that maintaining antiplatelet therapy

throughout surgery is associated with an increase in blood loss of 2.5% to 20% with aspirin and 30% to 50% with a combined therapy of aspirin and clopidogrel (277,278). Importantly, this increased blood loss has not been shown to correlate with increased mortality, except in intracranial surgery (271,277). Reports indicate an average increase of 30% in the transfusion rate, with a complication rate from red blood cell transfusion of 0.4% (279) and mortality linked directly to massive surgical blood loss in less than 3% of reported clinical data (280). However, an important recognized risk of withdrawing antiplatelet therapy has been described via a rebound effect with increased platelet adhesiveness (281-284). This phenomenon is also a consequence of the systemic inflammatory response and the acute phase reaction to surgery, which also increases platelet adhesiveness and decreases fibrinolysis (259,262,285). It should also be noted that comorbid pathologies, such as carcinoma and diabetes, can also contribute to the prothrombotic state. Death and infarction rates in acute coronary syndrome were doubled in the setting of drug withdrawal (284). Further, during the important period of reendothelialization after coronary stent implantation, myocardial infarction rates up to 85% have been reported (286), along with a 5-10-fold increase in the perioperative mortality. In comparison, existing literature has reported average stent thrombosis of 35% and the average mortality from stent thrombosis of 20% to 40% (259,287) without noncardiac surgery.

The questions have been raised in reference to withholding antithrombotic therapy prior to interventions and associated risks. Chassot et al (259) proposed to modify the practice of withholding patients from all antiplatelet agents 7 to 10 days prior to surgery, except when bleeding might occur in a closed cavity. Chassot et al (259) conducted an extensive review of the literature and reasoned that in the absence of prior clinical data on different antiplatelet regimens during noncardiac surgery, including low coronary risk situations, patients on antiplatelet drugs should continue therapy throughout surgery, except when bleeding might occur in a closed space. Another proposed consideration is the use of a therapeutic bridge utilizing antiplatelet drugs with shorter durations of action. In fact, other comprehensive reviews have offered variable guidance (4,50,55,63,83,86,87,97,99,164,167,288-304) on anticoagulation management. One systematic review (304), which evaluated 31 reports determined that for dental procedures, arthrocentesis, cataract surgery, and diagnostic endoscopy most patients can proceed

without alteration to their anticoagulant therapy. Several publications also delineated a variety of other procedures, including endoscopy (305,306), peripheral vascular surgery (307), and ophthalmic surgery (308) with no evidence of increased bleeding when patients are continued on antiplatelet therapy throughout the perioperative period. Gerstein et al (309) also showed that for many other procedures, minimal perioperative bleeding risk occurred when aspirin was continued, contrasted with concomitant thromboembolic risks associated with aspirin withdrawal.

The risk of thromboembolic events may be a more significant clinical feature, versus the risk of epidural hematoma. A majority of regional anesthesia and interventional pain management literature has focused on the risks of epidural hematoma, paying only scant attention to thromboembolic events. However, wider evidence in the literature defines multiple guidelines from other specialties that described continuation of antiplatelet therapy during surgical interventions, including peripheral vascular surgery, with some high-risk exceptions (271-281,286,304-308,310-321).

A large subset of clinicians report stopping antiplatelet therapy based on various guidelines and personal feelings considering this concept as a standard of care (1,14,50,51). In fact, the available evidence in reference to thromboembolic and cardiovascular complications related to discontinuation of antiplatelet or anticoagulant therapy is very concerning (50,55,56,58,62,68). A previous survey (50) reported a significantly higher prevalence of thromboembolic complications compared to epidural hematoma formations (55 vs. 162). In another study (56), the authors reported 9 devastating complications with 2 deaths as described earlier. Further, with appropriate care, relative morbidity and rare mortality can be controlled with epidural hematoma, whereas with cessation of anticoagulant and antiplatelet therapy cardiac and cerebrovascular morbidity and mortality are significant with devastating and irreversible damage in the majority of the cases.

## 5.2 Risk Factors

Interventional techniques are performed in the spine and other regions for chronic noncancer and cancer pain facing variable risks. To develop risk stratification, analysis and understanding of risk factors is crucial. Various guidelines have elucidated (1,2,14,52,54) these issues in developing guidelines. Raj et al (164) in 2004, stratified specific risk scores based on technique-

related risk and patient-related bleeding risk factors. This risk classification took various factors into consideration including a sharp or a blunt needle and use of fluoroscopy. The literature is extensive in risk stratification for anticoagulant and antiplatelet therapy in cardiology and also in the perioperative management in patients undergoing surgical interventions. Luo et al (168) published risk factors of epidural hematoma in patients undergoing spinal surgery with a meta-analysis of 29 cohort studies. In these studies, overall, 150,252 patients were included in the data synthesis. Studies with high quality evidence showed that older patients (> 60 years) OR, 1.35; 95% CI, 1.03–1.7) were at higher risk for spinal epidural hematoma. Studies with moderate quality evidence suggested that patients with a body mass index (BMI)  $\geq$  25 KG for M2 (OR, 1.39; 95% CI, 1.10–1.76), (OR, 1.67; 95% CI, 1.28–2.17), and diabetes (OR, 1.25; 95% CI, 1.01–1.55), and those undergoing revision surgery (OR, 1.92; 95% CI, 1.15–3.25), and multilevel procedures (OR, 5.20; 95% CI, 2.89–9.37) were at higher risk for spinal epidural hematoma. However, meta-analysis revealed no association between tobacco use, operative time, anticoagulant use or the ASA classification and spinal epidural hematoma. Thus, the authors used risk stratification based on the risk factors identifying them as patient-related risk factors and surgery-related risk factors.

Schieber et al (41) evaluated neurologic outcome of spinal epidural hematoma after neuraxial anesthesia, including epidural injections for pain in a systematic review. Antithrombotic medication was associated with an increased risk of persistent neurological deficit (OR 2.00, 95% CI 1.24 to 3.23),  $P < 0.01$ ). The increased risk for worse outcome did not persist after adjustment for significant confounders, American Spinal Injury Association (ASIA) classification score and age (adjOR 1.78 (95% CI 0.97 to 3.25),  $P = 0.06$ ), but remained increased in propensity score matched groups using age, sex, predisposition, ASIA score, multiple, bloody, unsuccessful or complicated puncture, needle size and catheters (OR 3.37 (95%CI 1.09 to 10.43),  $P = 0.04$ ). This risk increased further when only these patients who explicitly had no antithrombotic medications were compared with patients receiving antithrombotic drugs. (adjOR 2.36, 95% CI (1.21 to 4.58),  $P = 0.01$ ).

This increased risk persisted in multiple logistic progression modeling but could not be confirmed after propensity score matching. Secondary outcomes age, American Spinal Injury Association (ASIA) classification score, and time to intervention were significantly as-



sociated with a persistent neurological deficit in the whole population. However, the size of the hematoma was not significantly associated with persistent neurological deficit.

Breivik et al (73) in 2018, in a comprehensive topical review of reducing risk of spinal hematoma from spinal epidural and pain procedures based their recommendations on an extensive review of 166 case reports published since 1994 through 2015 (81). They described again patient risk factors and procedural risk factors.

Luo et al (168) in describing patient-related risk factors related to age, included 10 studies with demonstration of an association between older age (> 60 years) and postoperative spinal epidural hematoma. In surgical patients, they showed that spinal epidural hematoma occurred between either 1-15 days or 1-6 months. They considered older age as an important risk factor for postoperative spinal epidural hematoma. This evidence may be extrapolated to interventional techniques, specifically as patients of interventional pain management are older, receiving epidural injections.

In the development of this updated version of the Perioperative Management of Antiplatelet and Anticoagulant Therapy in Patients Undergoing Interventional Techniques: 2024 updated guidelines from the American Society of Interventional Pain Physicians (ASIPP), we have first considered the assessment of risk factors.

Risk factors of perioperative bleeding or complications related to thromboembolic phenomenon are categorized as follows with 3 dimensions (322).

- Procedures-specific risk of epidural hematoma or other bleeding
- Thrombotic risk if anticoagulant or antiplatelet therapy is withheld for a given procedure
- Patient-specific risk assessment that accounts for factors influencing the occurrence of a thrombotic event if anticoagulant or antiplatelet therapy is withheld

While the majority of the interventional techniques, except for implantables, are considered minor procedures, they are associated with major risk.

### 5.2.1 Patient Factors

Patient factors include structural anatomy, age, and medical condition.

#### 5.2.1.1 Anatomical Considerations

Spinal and epidural anatomy during preprocedural planning, as well as intraoperatively and postoperative-

ly, is crucial in managing perioperative anticoagulant therapy for epidural procedures. Epidural hematoma is the most common and concerning bleeding complication among all of the interventional techniques. The spine is divided anatomically into 3 compartments. These compartments have been defined as the anterior, neuraxial and posterior, as shown in Fig. 4. The anterior compartment compromises the vertebral body and the intervertebral disc. The neuraxial compartment comprises the epidural space and neural pathways. The posterior compartment comprises the posterior lamina and zygapophysial joints, along with the bony vertebral arch structures. The neuraxial compartment consists of all structures within the osseous and ligamentous boundaries of the spinal canal (Figs. 4 and 5). Within this compartment is the epidural space containing fat, epidural veins, epidural arteries, and lymphatics. A peridural membrane is also present (323). Epidural fat acts as a shock absorber to protect the contents of the epidural space and can also act as a depot for drugs and anesthetics injected into the epidural space (324,325). Epidural fat decreases with age. The spinal cord ends at L1 or L2 in adults; the dural sac contains the spinal cord and conus, running down to the level of S2 (326).

The size of the epidural space varies based on anatomic level with the posterior epidural space measuring approximately 1-2 mm in the cervical spine and 5-6 mm in the lumbar spine (327).

The ligamentum flavum becomes thinner in the thoracic and cervical spine (328-332). A number of investigators have studied the gaps in the ligamentum flavum and their relevance to dural punctures and other complications. Lirk et al (329) concluded that cervical and high thoracic ligamentum flavum frequently fails to fuse in the midline. In a cadaveric study, they showed the incidence of midline gaps at the following levels were: C3-4, 66%; C4-5, 58%; C5-6, 74%; C6-7, 64%; C7-T1, 51%; T1-2, 21%; T2-3, 11%; T3-4, 4%; T4-5, 2%; and T5-6, 2%. Joshi et al (331) studied the cervical spinal ligamentum flavum gaps with MRI and described the implications for interlaminar epidural injection therapy. They reviewed 50 patients retrospectively to evaluate ligamentum flavum integrity at the interlaminar spaces of C5-6, C6-7, and C7-T1. The inferior aspect of C5-C6 demonstrated the lowest observed rates of full ligamentum flavum gaps. Yoon et al (333), in describing anatomic variations of cervical and high thoracic ligamentum flavum, showed the incidence of midline gaps in the ligamentum flavum of 87% to 100% between C3 and T2. They showed the incidence decreased

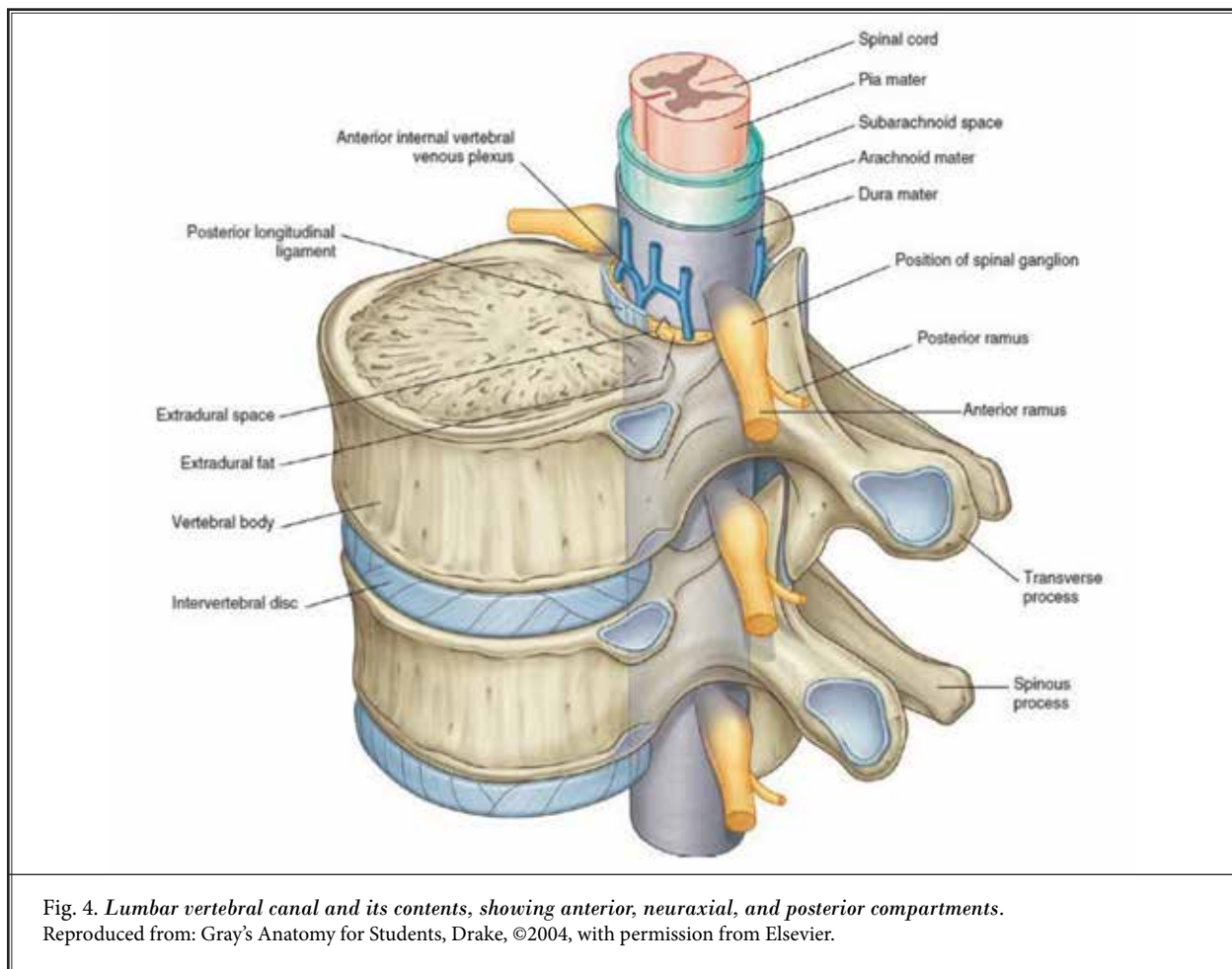


Fig. 4. Lumbar vertebral canal and its contents, showing anterior, neuraxial, and posterior compartments. Reproduced from: Gray's Anatomy for Students, Drake, ©2004, with permission from Elsevier.

below this level and was the lowest at T4-5 at 8% and the location of the gap was more frequently found in the caudal third of the ligamentum flavum than in the middle or cephalic portion of the ligamentum flavum. The authors postulated that it may be more useful to insert the needle into the cephalic portion of the intervertebral space than in the caudal portion.

Overall, the descriptions appear to be variable. The most commonly quoted study by Lirk et al (329) shows the highest rates of gaps at C5-6 of 74% and lowest level C7-T1 with 51%, whereas Joshi et al (331) show highest level 71.4% gaps at C7-T1 with lowest level at C5-6 of 2%. The clinical studies also show a lack of relevance to these gaps and subarachnoid punctures as described in large populations (334,335).

The amount of epidural fat varies according to spinal location with increase observed with caudal progression and basically absent in the cervical spine, and highest in the lumbosacral region (336). Epidural

lipomatosis (i.e., epidural lipomatosis with abnormal accumulation of epidural fat) may also be seen with long-term exogenous steroid use, obesity, and epidural steroid injections.

An epidural hematoma may occur due to bleeding from the venous plexus or arterial system (130). Plexus venosus vertebralis, or Batson's plexus, described by Breschet in 1819 (337), and later by Batson in 1940 (338), is a thin walled, large capacitance, valvulus venous system that extends along the entire length of the vertebral column (339). This plexus has extensive connections with the other venous systems via segmental vessels and frequent flow reversal may occur during normal physiological processes such as straining and coughing (339).

Epidural veins are thin walled, valveless, venous plexi, which are vulnerable to damage during the needle placement and advancement of the spinal cord stimulator leads and epidural and intrathecal catheters.

The epidural veins are mainly found in anterior and lateral aspects of the epidural space (339-342). In addition, fragility of these vessels increases with age. It also has been shown that blood vessel trauma occurs in 28% of patients during an epidural puncture at L2-3 (343), however, the size of the venous plexus changes with the segmental localization of the anastomoses (344). Consequently, large diameter anastomosis has been reported to exist in the lower cervical region, superior thoracic region, and entire lumbar region. The anatomy of these vessels also changes with increasing distention with spinal stenosis post-surgery and distention also dependent on intrathoracic and intraabdominal pressures. More importantly, these vessels are often located at the sites of common interventional pain procedures.

Multiple changes may be observed in the epidural space with spinal stenosis with central and foraminal stenosis, disc herniation compromising the canal diameter, ligamentum flavum hypertrophy, epidural fibrosis, surgical scarring which may increase the procedural difficulty (158). It also has been described that previous surgical and epidural interventions including epidural blood patch at the target level may also alter the epidural space and surrounding tissue. Occasionally repeated epidural injections with previous epidural entry may result in inflammatory changes that cause connective tissue proliferation and adhesions between the dura mater and ligamentum flavum and granulation changes at the ligamentum flavum (345). Of significant importance is the history of previous surgical intervention, resulting in scarring at the targeted site, and may be an independent risk factor for the subsequent development of an epidural hematoma secondary to reduced ability to absorb blood and blood products (346).

Consequently, review of radiologic imaging and understanding various abnormalities with incorporation of these factors into technical considerations is crucial, even in patients without antiplatelet or anticoagulant therapy, even though it is much more important in patients on anticoagulant and antiplatelet therapy. The significant issues related to anatomical considerations also include undesirable vascularity in the target ganglion of the middle cervical, stellate, lumbar sympathetic, and celiac plexus (14). It is well known that multiple vascular structures surround the location for stellate ganglion blockade including the vertebral, ascending cervical, and inferior thyroid artery (347-349). The location of the vertebral artery is of paramount importance as it passes anteriorly at the C7 level and enters the C6 transverse foramen in 93% of

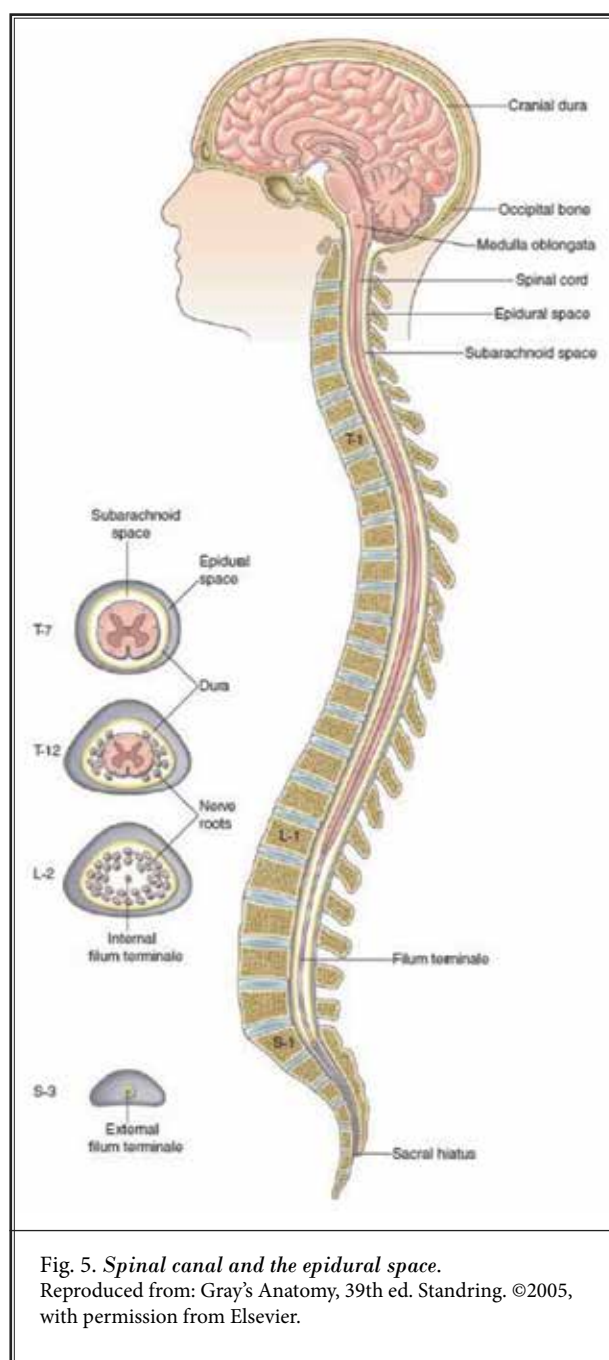


Fig. 5. *Spinal canal and the epidural space.*  
Reproduced from: Gray's Anatomy, 39th ed. Standring. ©2005,  
with permission from Elsevier.

the patients after taking off from the subclavian artery (14). In other cases, the vertebral arteries may enter the transverse foramen at C3, C4, C5, and C7, and most commonly next to C6 being C5 with 5%. Similar to the vertebral artery, the inferior thyroid artery originating from the thyrocervical trunk, branches into the ascending cervical artery, and passes in front of the anterior

tubercles of the cervical vertebral bodies, and causing inadvertent needle damage to these structures has resulted in retropharyngeal hematomas (349,350).

The etiology of spinal hematomas is complex and multifactorial. Etiology is not known in one third of the cases. Anticoagulation therapy and vascular malformations come as second and third causes. The fifth most common cause is spinal and epidural anesthetic procedures in combination with anticoagulant therapy (344).

As shown in Table 9, Lagerkranser (81) has shown patient-related risk factors in their study of 166 case reports of spinal hematoma from 1994 through 2015. Spinal stenosis was the most common diagnosis with ankylosing spondylitis taking the third place in relation to anatomical factors.

The evidence from the present analysis shows risk factors with severe degenerative arthritis with or without spinal stenosis, ankylosing spondylitis, osteoporosis, older age, frailty, previous stroke, intracranial bleed, hypertension, diabetes, thrombocytopenia, chronic re-

nal failure, chronic NSAID or steroid therapy, multiple attempts, epidural fibrosis, and previous surgery may increase bleeding observed during the procedure and risk of epidural hematoma.

### 5.2.1.2 Age

Age is an important factor for predicting the need for interventional pain management procedures. A large proportion of the patients in interventional pain management settings are elderly, constituting 30-40% of the patient population. Thus, the elderly develop a multitude of anatomic and physiologic changes as they get older. Their comorbidities also increase. Luo et al (168) showed that age had a significant association with the development of postoperative spinal hematoma in surgical patients. Guidelines also have described age as a risk factor. Lagerkranser (81) showed multiple factors influencing epidural hematoma and technical factors related to age. Schieber et al (41) in an analysis of neurological outcomes of spinal epidural hematoma after neuraxial anesthesia showed an association between antithrombotic medication and an increased risk of persistent neurological deficit. The increased risk for worse outcome did not persist after adjustment for significant confounders, ASA score and age, but remained increased in propensity score matched groups including the age.

### 5.2.1.3 Obesity

Luo et al (168) showed an association between obesity and postoperative spinal hematoma in surgical patients. Obesity is also an important factor in interventional pain management as many patients are obese and some are morbidly obese.

### 5.2.1.4 Hypertension

Luo et al (168) found in surgical literature that having hypertension was associated with a higher risk for postoperative spinal epidural hematoma. They showed that patients with hypertension had a 1.67-fold higher risk of postoperative hematoma than those without hypertension. These risks are similar for interventional pain management procedures.

### 5.2.1.5 Diabetes

Luo et al (168) also showed that there was an association between diabetes and postoperative spinal epidural hematoma. They considered diabetes as a risk factor for postoperative spinal epidural hematoma.

Table 9. Patient related risk factors as described in review of 166 cases of spinal hematoma.

Disorder	No. of cases
Spinal stenosis	14
Spinal tumour	6
Ankylosing spondylitis	4
Osteoporosis	4
Herniated disc	2
Scoliosis	2
Spondylosis	2
Spina bifida occulta	1
Dural AV-fistula	1
Spinal AVM	1
Spinal disease (total)	37
Thrombocytopenia <sup>a</sup>	13 <sup>b</sup>
Renal insufficiency	10
INR ≥1.5	6 <sup>c</sup>
Liver disease	4

AV: arteriovenous; AVM: arteriovenous malformation; INR: international normalized ratio

<sup>a</sup>Platelet count < 150 × 10<sup>9</sup> /L.

<sup>b</sup>Including 2 obstetric cases, one with HELLP (haemolysis, elevated liver enzymes, and low platelets), and one with eclampsia, and one patient with idiopathic thrombocytopenic purpura, discovered postlaminectomy.

<sup>c</sup>In one case without anti-vitamin K treatment.

Source: Lagerkranser M. Neuraxial blocks and spinal haematoma: Review of 166 case reports published 1994-2015. Part 1: Demographics and risk-factors. *Scand J Pain* 2017; 15:118-129 (81).

**5.2.1.6 Risk of Thromboembolism**

The major risk factors that increase thromboembolism risk are atrial fibrillation, prosthetic heart valves and recent venous arterial embolism within the preceding 3 months. However, these guidelines focused on major non-interventional procedures including cardiac and non-cardiac surgery. Table 10 shows factors associated with increased bleeding risk (351).

Anticoagulant treatment is mainly used chronically in patients with atrial fibrillation, and patients who have undergone heart surgery or have suffered from venous thromboembolism. The risk in atrial fibrillation is established using the CHA2DS2-VASc 5 scale as shown in Table 11.

Currently, these scores are proposed to identify patients with atrial fibrillation at high thromboembolic risk in a perioperative setting when they have more than 4 individual risk factors for stroke (352-355). In addition to the assessment of scores, patients with a recent history of stroke or transient ischemic attack within 3 months are considered as high thromboembolic risk. Existing cardiology guidelines on perioperative management of antithrombotic therapy consider high thromboembolic risk in:

- Patients with atrial fibrillation and a prior stroke or transient ischemic attack occurring > 3 months before the planned surgery.
- Patients with a CHA2DS2-VASc score less than 5 having prior thromboembolism during temporary interruption of oral anticoagulation (353,354).

In addition, the thrombotic risk of patients with cardiac prosthesis depends on the type of prosthesis and the position in which they are found. Overall, the risk is greater in patients with mechanical prosthesis and those located in the mitral position. In reference to venous thromboembolism, the greatest thrombotic risk occurs in the 3 months following the event. Table 12 shows a simplified summary of the stratification of the thromboembolic risk (125). Table 13 shows stratification of thromboembolic risk with a diagnosis of cerebral vascular disease or peripheral artery disease, acute coronary syndrome, or stable coronary artery disease (356), according to the time of evolution since diagnosis.

**5.2.2 Drug-Related Factors**

Benzon et al (61) in a literature review of spinal hematoma case reports concluded that spinal epidural hematoma developed even though the ASRA guide-

Table 10. *Factors associated with increased bleeding risk.*

Need for oral anticoagulation in addition to dual antiplatelet therapy
Advanced age (older than 75 years)
Frailty
Anemia with hemoglobin < 110 g/L
Chronic renal failure (creatinine clearance < 40 mL/min)
Low body weight (<60 kg)
Hospitalization for bleeding within past year
Previous stroke/intracranial bleed
Regular need for NSAIDs or prednisone

NSAIDs: nonsteroidal anti-inflammatory drugs  
 Source: Mehta SR, Bainey KR, Cantor WJ et al; members of the Secondary Panel. 2018 Canadian Cardiovascular Society/Canadian Association of Interventional Cardiology focused update of the guidelines for the use of antiplatelet therapy. *Can J Cardiol* 2018; 34:214-233 (351).

Table 11. *CHA2DS2-VASc scale for the assessment of thromboembolic risk in patients with atrial fibrillation.*

Risk Factor	Points
C - Heart failure	1
H - Arterial hypertension	1
A - Age ≥ 75 years (Age)	2
D - Diabetes mellitus	1
S - TIA/PTE/Stroke	2
V - Vascular disease	1
A - Age 65-74	1
S - Female sex	1

This scale adds up a series of points according to different risk factors of the patient, the higher the score, the greater the thromboembolic risk.

TIA: transient ischemic attack; PTE: pulmonary thromboembolism  
 Source: Herranz-Heras JC, Alcalde-Blanco L, Cañas-Zamarra I, et al. Update on the perioperative management of antiplatelets and anticoagulants in ophthalmic surgery. *Arch Soc Esp Oftalmol (Engl Ed)* 2021; 96:422-429 (125).

lines were followed, especially in patients on multiple anticoagulants. Schieber et al (41) in a systematic review of neurological outcome of spinal epidural hematoma after neuraxial anesthesia showed that the use of antithrombotic medication doubled the risk of persistent neurological deficit after spinal epidural hematoma. They also showed that patients with non-guidance adherence had a 3.42 higher chance of persistent neurological deficit.

Drug-related factors are considered to be the most common risk factors. Continuation or discontinuation of antiplatelets and anticoagulant drugs was reported in the majority of the patients (1,14,50,51). In addition, earlier studies also showed these as the most common

Table 12. Summary of the main indications of anticoagulant drugs and stratification of thromboembolic risk.

	Atrial Fibrillation	Heart valves	Venous Thromboembolism
<b>Low risk</b>	CHA2DS2-VASc 1–4 No previous stroke/TIA	Aortic valve without risk factor	venous thromboembolism > 12 months
<b>Moderate risk</b>	CHA2DS2-VASc 5–6 Stroke/TIA > 3 months	Aortic valve and risk factor 1	venous thromboembolism 3–12 months Non-severe thrombophilia
<b>High risk</b>	CHA2DS2-VASc > 7–9 Stroke/TIA < 3 months	Rest of valves Ictus/ transient ischemic attack < 6 months	venous thromboembolism < 3 months Severe thrombophilia

Source: Herranz-Heras JC, Alcalde-Blanco L, Cañas-Zamarra I, et al. Update on the perioperative management of antiplatelets and anticoagulants in ophthalmic surgery. *Arch Soc Esp Oftalmol (Engl Ed)* 2021; 96:422-429 (125).

Table 13. Periprocedural thrombotic risk stratification.\*

Acute Coronary Syndrome	Stable Coronary Disease	Cerebrovascular Disease	Peripheral Artery Disease	Time Since Intervention (Months)	Thrombotic Risk
Medical treatment PCI + BMS/DES/DEB or CABG PCI + BMS/DES/DEB or CABG with additional patient or stent risk factors, or first-generation DES	PCI + BMS/DES/DEB or CABG* PCI + BMS/DES/DEB or CABG with additional patient or stent risk factors PCI + first-generation DES	Ischemic stroke; carotid stent placement	Acute peripheral vascular event + revascularization with DES; chronic occlusions	< 3	High
				3-6	Moderate
				> 6	Low
				< 6	High
				6-12	Moderate
				> 12	Low
				< 12	High
				> 12	Moderate

\*BMS indicates bare metal stent; CABG: coronary artery bypass graft; DEB: drug-eluting balloon; DES: drug-eluting stent; PCI: percutaneous coronary intervention.

Source: Statman BJ. Perioperative management of oral antithrombotics in dentistry and oral surgery: Part 2. *Anesth Prog* 2023; 70:37-48 (356).

risk factors. Lagerkranser (81) described drug-related factors as the highest with frequencies as shown in Table 14. He reported intake of anti-hemostatic drugs in 63% of the patients, whereas more than one anti-hemostatic drug was implicated in 47 of 166 cases.

The main categories of antiplatelet and anticoagulants are described as platelet inhibitors that interfere with platelet aggregation and thrombus formation, and anticoagulants interfering with formation of clotting, thereby reducing fibrin formation, thus preventing clots from forming and expanding and fibrinolytics which interfere with fully formed clot. These include NSAIDs and aspirin, ADP receptor inhibitors clopidogrel (Plavix), prasugrel (Effient), ticlopidine (Ticlid) and ticagrelor (Brilinta); phosphodiesterase inhibitors cilostazol (Pletal) and dipyridamole (Persantine); glycoprotein GPIIb/IIIa inhibitors abciximab (ReoPro), tirofiban (Aggrastat) and eptifibatide (Integrilin); low molecular weight heparins; warfarin; direct thrombin inhibitors dabigatran (Pradaxa), argatroban (Acova®), bivalirudin (Angiomax®), lepirudin (Refludan®), desirudin (Iprivask®) and Hirudin; direct factor Xa inhibitors

rivaroxaban (Xarelto) and apixaban (Eliquis), and enoxaban (Savaysa, Lixiana); herbal/alternative therapies garlic, Ginkgo biloba, and fish oil.

The data reported by Lagerkranser (81), and the data derived from the present analysis are shown in Table 14. Aspirin was the most common drug of the 19 cases of epidural hematoma reported in this series with 7 patients with the use of aspirin, 4 patients discontinued aspirin use appropriately, and 3 patients continued with the therapy. In the data by Lagerkranser (81), aspirin was utilized in 16% of patients reporting spinal hematoma of 160 cases constituting a total of 18% in the present series. Eight percent of patients continued aspirin therapy and 11% discontinued aspirin therapy. The most common drug reported in Lagerkranser (81) series was low molecular weight heparin in 31% of the cases and warfarin in 11% of the cases. In the present series, warfarin with or without low molecular weight heparin was utilized in 4 patients with 11% utilization.

The literature search performed and analysis of the case reports for the guidelines showed reported drug classes in order of frequency as shown in Table 15, with

exclusion of cases not receiving antiplatelet or anticoagulant therapy.

### 5.3 Antithrombotics

#### 5.3.1 NSAIDs and Aspirin

Among the NSAIDs, aspirin is important as it is used for primary and secondary prevention of vascular ischemic events. Even though evidence is debated, a systematic review and meta-analysis published in 2023 (37) showed aspirin use in primary prevention is associated with a consistent reduction of major adverse cardiovascular events, including death, myocardial infarction, or stroke, but at the expense of major bleeding events. Consequently, physicians and patients continue to recommend aspirin use. Aspirin's effects on platelet function, COX activity and thromboxane production are time and dose dependent (14,357-359). The research shows that a single 20 mg dose of aspirin reduces COX activity by 82% as early as 5 minutes after dosing (357). It has also been shown that a single dose of 100 mg of ASA suppresses COX activity by 95% ± 4% (359). Repeated dosing also results in a significant reduction in a required ASA platelet inhibitory dose, with a 50% inhibitory dose decreasing from 26 mg of a single dose to 3.2 mg after repeated dosing (357). Thus, after daily dosing with 20-40 mg of aspirin, 92% to 95% of COX activity is inhibited over 6-12 days (357). The average lifespan of a platelet is 7-10 days, with 10% of the circulating platelet pool being replaced daily (360,361). However, platelet turnover and aspirin's antiplatelet effects displace significant interindividual variability that is influenced by age, body mass, and specific medical conditions, including diabetes (362). The return of platelet function after discontinuation of aspirin is multifactorial, including prior aspirin dosing, rate of platelet turnover, time interval of discontinuation and platelet-specific response to aspirin therapy. A study examining healthy men demonstrated that complete recovery of platelet aggregation occurred in 50% of the subjects by the third day after discontinuation of taking 325 mg of aspirin every other day for 14 days (363). The results of other studies also showed platelet functional recovery after cessation of aspirin in volunteers and surgical patients at day 3 and within 4-6 days respectively (363), with all of the subjects restoring platelet aggregation at least by 80% of baseline level by day 6 (364).

The time it takes to achieve 50% recovery of platelet function with aspirin use is 3 days (73). Platelet

Table 14. Drug classes reported, in order of frequency, 160 cases of spinal hematoma.

	No. of cases (percentage)
Low molecular weight heparin	50 (31)
Unfractionated heparin	39 (24)
Acetylsalicylic acid	25 (16)
Vitamin-K antagonists	17 (11)
Non-steroidal anti-inflammatory drugs	17 (11)
Dextran	6 (3.8)
Fibrinolytics	4 (2.5)
ADP receptor inhibitors	4 (2.5)
Phosphodiesterase inhibitor (dipyridamole)	2 (1.3)
Direct fXa inhibitor (rivaroxaban)	2 (1.3)
Direct thrombin inhibitor (dabigatran)	1 (0.6)
Fondaparinux	1 (0.6)
Selective serotonin receptor inhibitor	1 (0.6)

ADP: adenosine diphosphate

Source: Lagerkranser M. Neuraxial blocks and spinal haematoma: Review of 166 case reports published 1994-2015. Part 1: Demographics and risk-factors. *Scand J Pain* 2017; 15:118-129 (81).

Table 15. Drug classes reported in order of frequency based on review for guidelines (31 did not receive any anticoagulant or antiplatelet therapy).

	Continued	Discontinued	Total
Aspirin	10	8	18
Warfarin (Coumadin)	1	5	6
Clopidogrel (Plavix)	3	3	6
Fish oil	3	1	4
NSAIDs	1	2	3
Enoxaparin (Lovenox)	0	2	2
Cilostazol (Pletal)	1	0	1
Dabigatran (Pradaxa)	0	1	1
Ketorolac (Toradol)	1	0	1
Indomethacin (Indocin, Tivorbex)	1	0	1
Ginko	0	1	1

\*More than one drug was involved in 9 cases.

regeneration is the main determinant of antiplatelet function of irreversible inhibitors. The majority of the bleeding complications were related to aspirin in 18%, while 11% discontinued and 7% continued; bleeding complications have been reported without any drug therapy. Table 16 shows characteristics of NSAIDs with their antiplatelet function (365).

In a 2022 publication of a multicenter, cross-sectional study, Seo et al (60) determined the necessity of discontinuing aspirin prior to interventional pain pro-

Table 16. Characteristics of nonsteroidal anti-inflammatory drugs.

Generic Name	Trade Name	Cyclooxygenase (COX) Enzyme Affected	Half-life (Hours)	Affects Platelet Function
Aspirin	Aspirin	COX-1, COX-2	0.33 hours (20 minutes)	Yes
Celcoxib	Celebrex	COX-2	11	No
Diclofenac	Catafalm Voltaren Arthrotec (combined with misoprostol)	COX-1, COX-2	1.1	No
Diflunisal	Dolobid	COX-1, COX-2	13	Yes
Etodolac	Lodine, Lodine XL	COX-2	6.5	No
Fenoprofen	Nalfon	COX-2	2.5	No
Flurbiprofen	Ansaid	COX-1	3.5	Yes
Ibuprofen	Advil Motrin Tab-Profen	COX-1, COX-2	2	Yes
Indomethacin	Indocin Indocin SR	COX-1, COX-2	4-5	Yes
Ketoprofen	Orudis KT Oruvail	COX-1, COX-2	1.5	Yes
Ketorolac	Toradol	COX-1, COX-2	5-6	Yes
Meloxicam	Mobic	COX-2	20	No
Nabumetone	Relafen	COX-2	26	No
Naproxen	Aleve, Naprosyn, Anaprox	COX-1, COX-2	14	Yes
Oxaprozin	Daypro	COX-1, COX-2	58	Yes
Piroxicam	Feldene	COX-1, COX-2	57	Yes
Sulindac	Clinoril	COX-1, COX-2	8	No
Tolmetin	Tolectin	COX-1, COX-2	1	Yes

Adapted and modified from: Kim C, Pfeiffer ML, Chang JR, Burnstine MA. Perioperative considerations for antithrombotic therapy in oculo-facial surgery: A review of current evidence and practice guidelines. *Ophthalmic Plast Reconstr Surg* 2022; 38:226-233 (365).

cedures in relation to individual platelet function. The results were surprising with 56.4% of patients showing normal platelet function, whereas 43.6% showing abnormal platelet function. In contrast, patients in non-aspirin taking groups also had abnormal platelet function in 14.2% of the patients. The authors concluded that high prevalence of normal platelet function in patients taking aspirin suggests no necessity of discontinuation before procedures in such patients. Abnormal platelet function can occur even in patients who are not taking aspirin. They have recommended that platelet function should be measured and considered on a case-by-case basis prior to interventional procedures, and discontinuation of aspirin should be decided based on these factors. While these study results are extremely important and shed light on multiple questions raised in bleeding complications, platelet function analysis is not performed routinely, and it appears to be difficult to obtain the platelet function in these at the bedside.

Non-aspirin NSAIDs also have influence with highly variable effect on bleeding. Acetaminophen did

not have any effect on platelet aggregation, whereas non-aspirin NSAIDs were found to abolish the second wave of platelet aggregation for variable time periods based on the pharmacokinetics associated with each drug. Non-aspirin NSAIDs have also been reported with risk of hematoma formation. Spinal hematomas have occurred after cervical epidural steroid injections in individuals taking non-aspirin NSAIDs (90,91,134,179).

### 5.3.2 ADP Receptor Inhibitors

ADP receptor inhibitors clopidogrel (Plavix), prasugrel (Effient), ticlopidine (Ticlid) and ticagrelor (Brilinta) are the drugs in this category and function by inhibiting platelet aggregation. These are commonly utilized drugs. Among these drugs, clopidogrel is more commonly used; however, it has several limitations including a lack of response in 4%-30% of patients and its susceptibility to drug interactions and to genetic polymorphisms (366-368). Ticlopidine is rarely used, and its antiplatelet effect is delayed and may cause hypercholesterolemia, thrombocytopenia, aplastic anemia, and thrombotic



thrombocytopenic purpura. Prasugrel is a prodrug similar to clopidogrel and also causes irreversible inhibition of P2Y<sub>12</sub> receptors. However, unlike clopidogrel, it requires only one metabolic step to form its active drug (369). It causes 90% inhibition of platelet function compared with 60%-70% for clopidogrel (14,370).

ADP inhibitors have been described as responsible for the formation of epidural hematoma in patients who underwent central neuraxial blockade in 2.5% of 160 cases (4 cases). In that assessment, clopidogrel was issued in combination with either aspirin or ticlopidine in 3 cases; 2 of these cases had the therapy discontinued appropriately and the therapy was continued in one case. Overall, ADP inhibitors with reports available for only 1 or 2 drugs showed any relevance in 8% of the cases with only one case or 2.6% of cases where it was continued. These findings are similar to the findings from Lagerkranser (81)

### 5.3.3 Phosphodiesterase Inhibitors

The drugs in this category include cilostazol (Pletal) and dipyridamole (Persantine) with inhibition of phosphodiesterase which leads to an increase in intracellular cAMP and subsequent inhibition of platelet aggregation (218).

There continues to be limited information in the literature relating to the use of cilostazol and the development of adverse bleeding outcomes during interventional techniques. There exists one case report of bleeding complications associated with interventional technique and the concurrent use of cilostazol (154). In this case report, the patient underwent a caudal epidural injection and subsequently developed an epidural hematoma extending from L2 through S1. The patient also had concomitant central canal compromise, most severe at L2-3 and L3-4. Previously, this patient had received lumbar interlaminar epidural injection without any adverse events. The patient underwent emergency decompression laminectomy, and the patient made a full recovery. This is the only case report in interventional techniques, therefore the use of Cilostazol alone without aspirin is recommended to be continued during interventional techniques. Lagerkranser (81) reports 2 cases of bleeding complications with dipyridamole with an incidence rate of 1.3% in 160 cases. Overall, the use of cilostazol is considered to be low risk and continuation is appropriate.

### 5.3.4 Direct Oral Anticoagulants (DOACs)

Direct antifactor IIa such as dabigatran (Pradaxa)

and antifactory Xa including rivaroxaban (Xarelto), apixaban (Eliquis), endoxaban (Savaysa, Lixiana), are frequently used in the United States.

In this present assessment, there was one case report, while Lagerkranser (81) showed 2 cases of spinal hematoma with rivaroxaban yielding 1.3% prevalence among 160 cases developing spinal hematoma.

### 5.3.5 Warfarin

Warfarin is the oldest anticoagulant in current clinical use. Warfarin is one of the most commonly used drugs in patients undergoing interventional techniques and many complications have been reported. There have been reports of epidural hematoma in patients of warfarin, regardless of whether the drug was stopped per the guidelines.

Warfarin was found to contribute to spinal hematoma in 11% of the cases, as reported by Lagerkranser (81). Our report showed a total of cases of warfarin which were stopped appropriately with 2 of them also receiving enoxaparin with a similar incidence of around 10%.

### 5.3.6 Low-Molecular Weight Heparin

Low molecular weight heparin functions by inhibiting the coagulation cascade by binding to antithrombin.

Low molecular weight heparin is a commonly used drug, and its use has been implicated in several cases of epidural hematoma. Low molecular weight heparin was found to be responsible for the highest number of cases of epidural hematoma in 31% of reports by Lagerkranser (81). Our reports also show 2 cases of lumbar spine epidural hematoma in the setting of warfarin bridging with low molecular weight heparins (140,141).

### 5.3.7 Selective Serotonin Reuptake Inhibitors (SSRIs)

In a systematic review and meta-analysis of use of SSRI antidepressants and the risk of bleeding complications in patients on anticoagulant or antiplatelet agents (247), the authors identified 32 nonrandomized studies with over 1.8 million patients. The results showed that among individuals receiving anticoagulants described in 13 studies, SSRI users experience a statistically higher risk of major bleeding compared to non-SSRI users. Among these studies, individuals receiving antiplatelet therapy in 2 studies, SSRI users were associated with an increased risk of major bleeding with pooled OR of 1.45 (95% CI; 1.17-1.80;  $P = .001$ ) with low heterogene-

ity. In addition, for secondary outcomes, the use of SSRI among individuals treated with antithrombotic therapy revealed a higher risk of gastrointestinal bleeding or any bleeding events, whereas only anticoagulant use was illustrated and increased risk of intracranial hemorrhage.

Rahman et al (371) published the results of concomitant use of SSRIs with oral anticoagulants and risk of major bleeding. Their main outcome assessment was incidence rate ratio (IRR) of hospitalization for bleeding or death due to bleeding. In this large study there were 42,190 patients with major bleeding. Concomitant use of SSRIs and oral anticoagulants was associated with an increased risk of major bleeding compared with oral anticoagulants alone. The risk peaked during the initial months of treatment in the first 30 days of use and persisted for up to 6 months; however, the risk did not vary with age, gender, history of bleeding, chronic kidney disease, and potency of SSRIs. An association was present both with concomitant use of SSRIs and DOACs compared with DOAC use alone and concomitant use of SSRIs. The authors concluded that among patients with atrial fibrillation, concomitant use of SSRIs and oral anticoagulants was associated with an increased risk of major bleeding compared with oral anticoagulant use alone, requiring close monitoring and management of risk factors for bleeding, particularly in the first few months of use.

In our analysis for the present guidelines, there was only one patient where multiple drugs were administered, including ketorolac, fluoxetine, fish oil, and vitamin E; consequently, it is not clear the role of SSRI in the causation of epidural hematoma (90). This case is considered as continuation of antiplatelet therapy.

## 5.4 Procedural Factors

Interventional pain management is a growing specialty. There have been significant increases in utilization patterns for all interventional techniques until recent years when deceleration started, except for certain procedures including spinal cord stimulation (3-9). The number of interventional procedures performed per 100,000 Medicare beneficiaries was 3,708 in 2000, which increased to 9,760 in 2010. Since then, it has shown slow declines to 7,616 in 2020 due to a COVID-19 effect in Medicare fee-for-service (FFS) beneficiaries. Of these, epidural and adhesiolysis procedures constituted 2,172 per 100,000 Medicare beneficiaries in 2000, which increased to 4,746 in 2010 and stayed around 3,583 in 2019, subsequently decreasing to 2,902

due to a COVID-19 effect in 2020. Similarly, facet joint interventions were 1,072, increasing to 4,130 in 2010 with a rate of 4,968 in 2019, which decreased to 4,099 in 2020 due to a COVID-19 epidemic. While these two categories are major procedures, disc procedures and other types of nerve blocks were 464 in 2000, increasing to 884 in 2010 and 823 in 2019, and decreasing to 614 in 2020 due to a COVID-19 effect. Figure 6 shows distribution of procedural characteristics rates by type of procedure from 2000 to 2020. There was also a significant decrease in utilization patterns of augmentation procedures. In contrast, spinal cord stimulation procedures increased with utilization patterns, as well as expenditures. Figure 7 shows expenditures for various interventional techniques (4,5,7,8).

### 5.4.1 Epidural Interventions

Multiple reports of bleeding and epidural hematoma associated with interventional techniques in patients without antithrombotic therapy (61,62,66,68,70,71,93-96,98-105,132,135,137,142,144,145,149,153,155-161,173,174,179,183,187,190,191,205,372-380), and several reports of bleeding in patients with discontinued antithrombotic therapy have been published (61,62,65,68,88,91,92,98-105,132,133,139-141,143,373,374). Multiple reports of bleeding complications with continuation of anticoagulant therapy during interventional techniques were identified (66,67,89-91,134,151,154).

Appendix Tables 1-3, Table 4, and Figs. 2 and 3 show summary reports of several epidural hematomas with epidural injections, acupuncture and dry needling, chiropractic, kyphoplasty, and spinal cord stimulation lead placement in patients without antithrombotic therapy, with antithrombotic therapy withheld for an appropriate duration, and with antithrombotic therapy continued. A total of 62 epidural hematomas were described. There were 31 in the cervical spine, 9 in the thoracic spine, and 22 in the lumbar spine. Of these, 30 patients were not on antiplatelet therapy, 17 patients had their antithrombotic therapy discontinued, 15 continued antithrombotic therapy (Figs. 2 and 3).

Benzon et al (61) showed a total of 48 cases of spinal epidural hematoma related to interventional procedures, whereas Shieber et al (41) showed a total of 56 procedures with 26 without antithrombotic medication, and 30 with antithrombotic medication.

#### 5.4.1.1 Cervical Epidural Injections

Ehsanian et al (84) did not report any cases of epi-

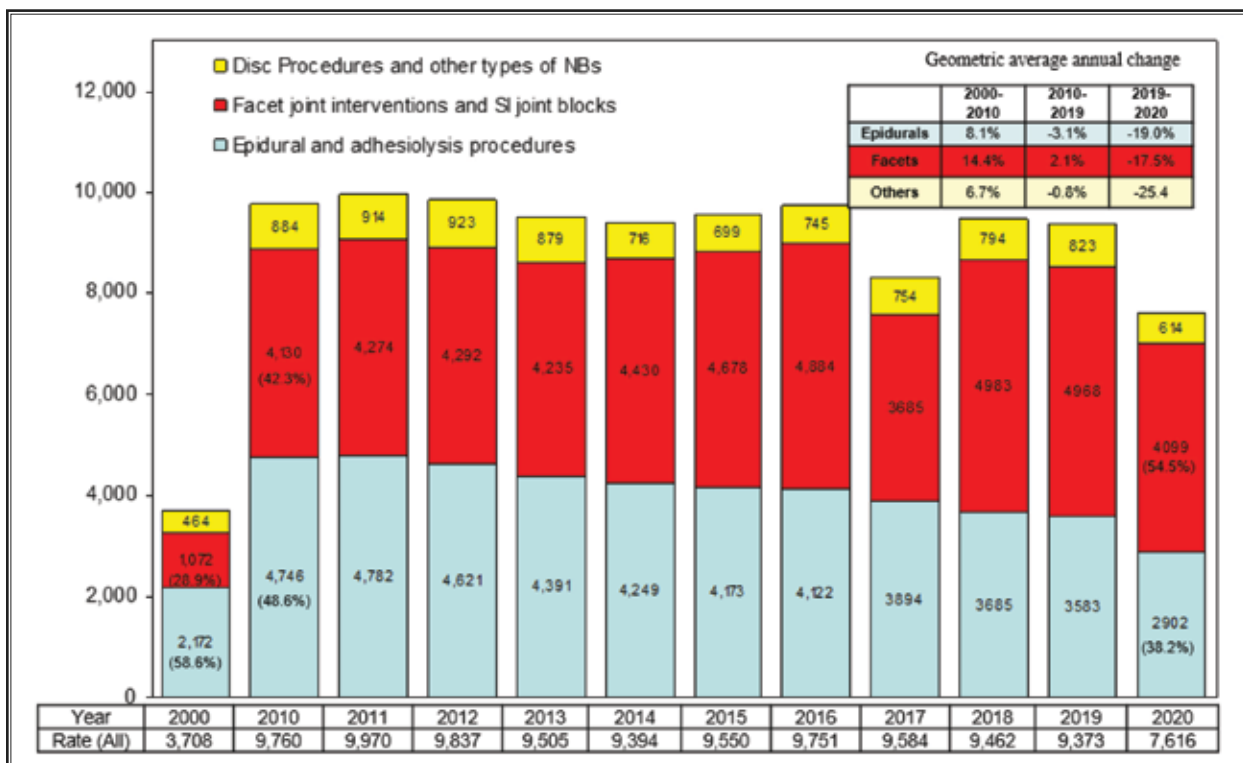


Fig. 6. Distribution of procedural characteristics (rates) by type of procedures from 2000 to 2020. Manchikanti L, Pampati V, Sanapati MR, et al. COVID-19 pandemic reduced utilization of interventional techniques 18.7% in managing chronic pain in the Medicare population in 2020: Analysis of utilization data from 2000 to 2020. *Pain Physician* 2022; 25:223-238. (3)

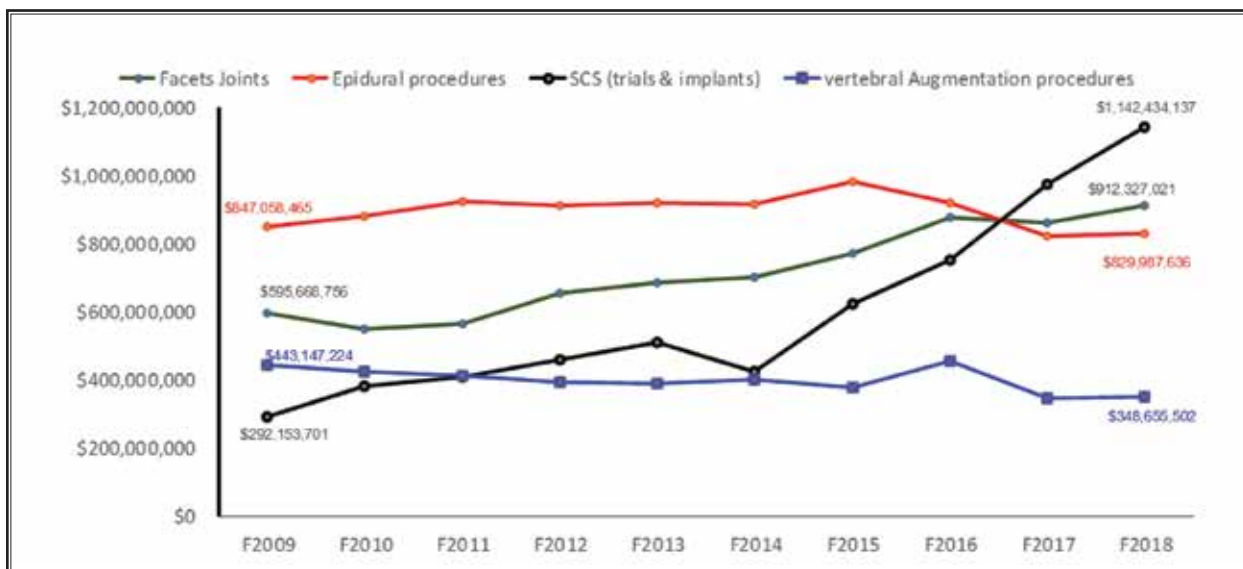


Fig. 7. Total cost for facet joints interventions, epidural services, spinal cord stimulators and vertebral augmentation procedures on Medicare Beneficiaries.

dural hematomas with 14 cervical transforaminal epidural steroid injections performed without antithrombotic therapy discontinuation. There were no patients in their cohort who underwent cervical interlaminar epidural steroid injections.

Manchikanti et al (55) evaluated in a prospective study, bleeding risk of interventional techniques in chronic pain with or without antithrombotics and with or without cessation of antithrombotics. In this evaluation of cervical epidural injections, 410 patients were on aspirin with aspirin continued in 249 patients and discontinued in 161 patients. There were 77 patients on clopidogrel, 67 patients discontinued, and 10 patients continued its use. In addition, there were 52 patients on aspirin and another antithrombotic with 34 discontinued and 18 continued. Local bleeding was observed in a significant proportion of patients; however, with a higher proportion in patients after discontinuation rather than continuation. Local hematoma was observed in 0.2% of patients without antithrombotics, whereas on those with thrombotics, it was 0.0%. Oozing was somewhat higher in the antithrombotic group with 14.8% vs. 13.2% with all epidurals. Bruising was also higher with all epidurals with a total of 0.4% vs. 0.2% with no antithrombotics.

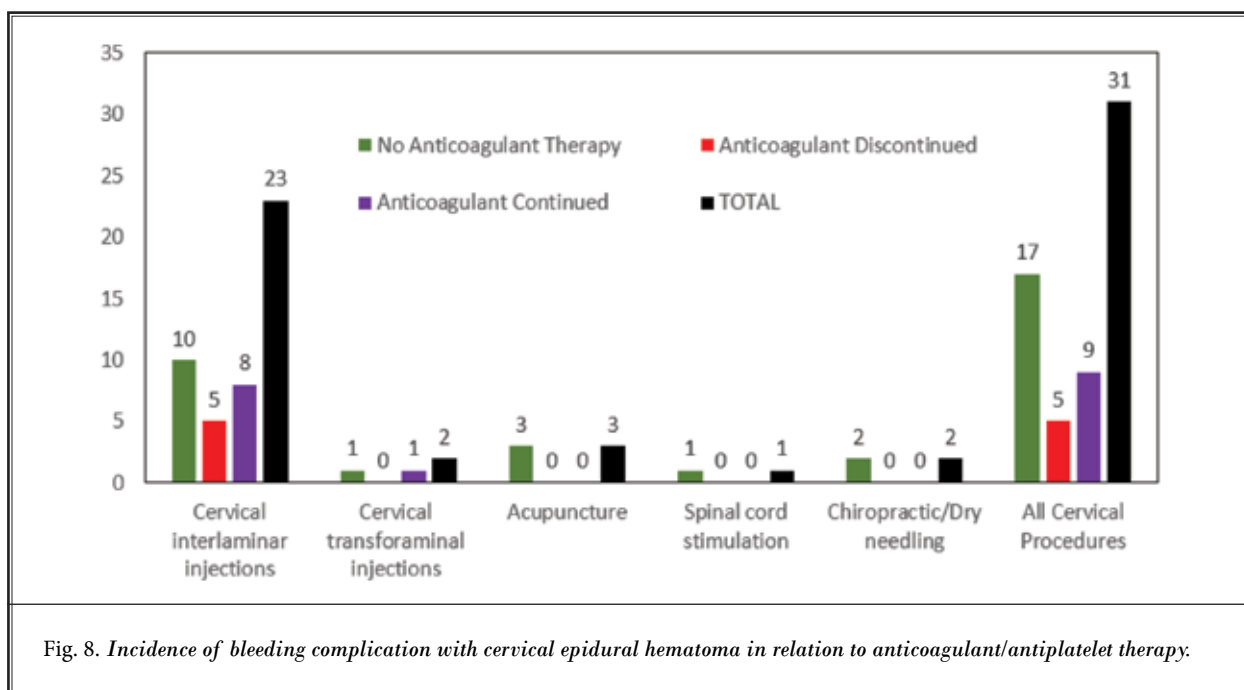
Manchikanti et al (68) reported 2 cases of epidural hematomas following cervical interlaminar epidural steroid injections. Notably, only one of these patients was taking an anti-platelet medication (undisclosed type or dose), but even this was discontinued pre-procedurally. However, Manchikanti et al (68) also described 2 cases of thromboembolic events with antithrombotic therapy cessation.

Furman et al (80) in a retrospective evaluation of 565 cervical epidural injections and 26 thoracic epidural injections performing the procedure at C7-T1 in the majority of the patients except for 4 where it was performed at C6-7. In this study, 351 patients ceased their anticoagulant and antiplatelet therapy prior to the procedure, whereas 240 maintained these medications. The most common medications were aspirin, clopidogrel, and warfarin. The authors reported no clinically relevant incidents of epidural hematoma in either cohort. While the authors were not recommending cessation or the safety of doing interlaminar procedures in the cervical and thoracic spine, with the continuation of antiplatelet/anticoagulant therapy, they postulated that this study suggests reevaluating the potential postprocedural epidural hematoma risks associated with continuing or versus ceasing these medications.

Lee et al (147) presented a case report of a healthy 38-year-old woman undergoing a series of right transforaminal epidural injections at the C7-T1 level. Approximately 4 days after the final injection, she awakened with severe upper thoracic pain and progressive loss of sensation in the lower extremities. MRI of the spine showed a large hematoma extending from T1 to T5. The patient underwent surgical decompression. Within 6 months the patient regained full strength and sensation in both lower extremities. However, it is one of the only case reports in this category. The procedural images were not provided, and it does not appear the authors were proceduralists. One of the guideline authors (BJS) believes that given how extremely rare utilization of C7-T1 transforaminal epidural steroid injection, there is reasonable uncertainty that this was in fact not a transforaminal epidural steroid injection despite what was reported. C7-T1 interlaminar epidural steroid injection would be much more likely; however, it is difficult to confirm the veracity of this case report (Appendix Table 1).

In the present assessment, cervical epidural hematoma or bleeding complications related to cervical epidural injections are the most common occurrence as shown in Fig. 3 and Table 4. Of a total of 62 reports of bleeding complications, 31 were related to the cervical region, with 23 of them secondary to cervical interlaminar epidural injections, and 2 with cervical transforaminal epidural injections with one questionable case report (147). Figure 8 shows reports of cervical epidural hematoma and intracranial complications with cervical interlaminar epidural injections, cervical transforaminal epidural injections, acupuncture, spinal cord stimulation, and chiropractic or dry needling. These results indicate that while cervical interlaminar epidural injections are the most common procedure associated with spinal epidural hematoma, they also have occurred in a high proportion of patients without anticoagulant therapy.

Cervical interlaminar epidural hematoma has been described in 23 patients with one report based on spinal cord stimulation and 2 reports based on cervical transforaminal epidural injections with one questionable report. Consequently, cervical interlaminar epidural injections are considered as high-risk procedures; however, cervical transforaminal epidural injections, with one or 2 case reports with anatomical risk factors with arterial circulation, even development of foraminal hematoma, may be associated with morbidity and mortality, is considered as intermediate or moderate risk. Thus, based



on the present analysis of the evidence and consensus, cervical interlaminar epidural injections are considered as high-risk, whereas cervical transforaminal epidural injections are considered as moderate or intermediate risk.

#### 5.4.1.2 Thoracic Epidural Injections

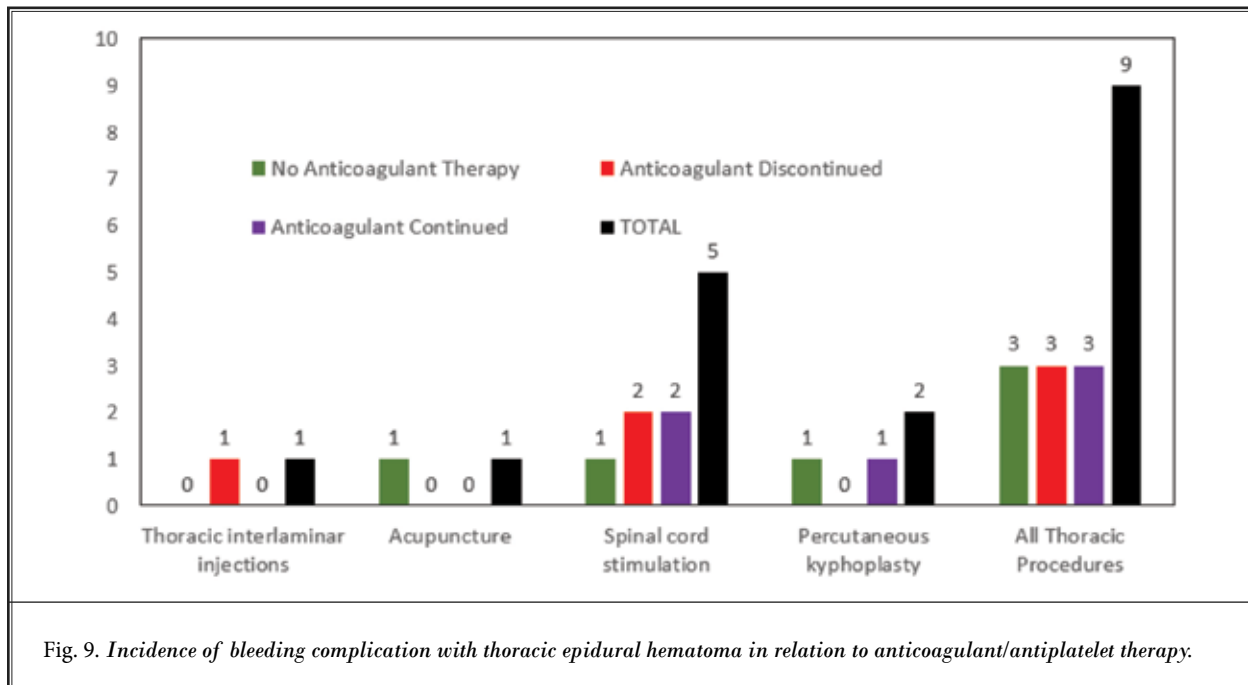
Thoracic epidurals are not commonly performed compared to either cervical or lumbar epidural injections. Manchikanti et al (55) in their prospective evaluation of bleeding risk studied 301 patients with 237 receiving no antiplatelets or anticoagulants. Of these, there were 49 patients receiving in the aspirin group with 30 continuing for the procedure and 19 discontinuing it. Clopidogrel was used in 8 patients, and it was discontinued in 7 and continued in one, whereas 5 patients had aspirin and another drug, of which all of them continued. There were no specific additional complications noted when they were continued or discontinued compared to no antithrombotic therapy. Overall, for epidurals, intravascular entry was noted in a higher proportion of patients with 6.8% compared to 4.5%. Other differences were clinically insignificant.

Furman et al (80) in a retrospective evaluation assessed epidural hematoma risks associated with ceasing versus maintaining anticoagulant and/or antiplatelet medications of thoracic interlaminar epidural injections, along with cervical interlaminar epidural

injections. Overall, they included 26 patients who underwent thoracic epidural injections. The most common medications used were aspirin, clopidogrel, and warfarin. Drugs were maintained in 15 patients and discontinued in 11 patients. There were no reports of clinically relevant epidural hematoma in either group.

Thoracic epidural hematoma reports included a total of 9 reports with 5 of them involving spinal cord stimulator lead placement. Thoracic interlaminar epidural injections were a causative factor in only one case. Percutaneous kyphoplasty was responsible in 2 patients and acupuncture in one patient. As shown in Fig. 9, 3 patients were not on anticoagulant therapy, 3 were discontinued with anticoagulant therapy, and only 3 patients continued anticoagulant therapy.

Thoracic interlaminar epidural hematoma has been described in a total of 9 reports, with 5 of them involving spinal cord stimulator lead placement. Consequently, it is stratified as a high-risk procedure. In reference to thoracic transforaminal epidural injections, there were no case reports of thoracic transforaminal epidural injections causing either foraminal or interlaminar epidural hematomas. However, considering the anatomic risk factors with arterial circulation, even development of foraminal hematoma may be associated with significant morbidity and mortality. Consequently, based on consensus, thoracic transforaminal epidural injections are stratified into moderate-risk.



#### 5.4.1.3 Lumbar Epidural Injections

Manchikanti et al (55) in a prospective evaluation studied the role of antithrombotics with discontinuation or continuation in a total of 1,450 patients with 1,169 not receiving any antithrombotics. Of these, 191 patients were on aspirin with 14 continuing aspirin and 16 discontinuing it. In addition, aspirin plus another drug was administered in 37 patients. Of these, it was discontinued in 28 and continued in 9. For lumbar transforaminal epidural injections, there were a total of 1,310 patients in the study with 1,019 without antithrombotic therapy. Of these, 195 patients were on aspirin, with 144 continued and 51 discontinued, there were 31 patients on clopidogrel with 21 discontinued and 10 continued. There were also 38 patients on aspirin and other drugs. Of these, 24 discontinued and 14 continued.

Manchikanti et al (55) also studied caudal epidural injections, which included a total of 3,985 patients with 2,855 with no antithrombotic therapy. Of these, 770 patients were on aspirin with 242 discontinuing prior to the procedure and 528 continuing it. There were 143 patients on clopidogrel, 44 continuing and 99 discontinuing it. In addition, there were 102 patients with aspirin plus other drugs, of which 50 of them continued and 62 discontinued.

Endres et al (58) did not report any bleeding complications with lumbar interlaminar (n = 30) and

transforaminal (n = 3,159) epidural steroid injection. They further concluded that their sample size was sufficient to suggest that continuing even warfarin and clopidogrel may be safe in patients undergoing lumbar transforaminal epidural steroid injections. These sentiments were also echoed by Ehsanian et al (84) who report no serious bleeding complications including no epidural hematomas in 88 patients following 88 lumbar transforaminal epidural steroid injections. In Letters to the Editor, Furman et al (381) and Miller et al (322) emphasized the importance of reclassifying lumbar transforaminal epidural steroid injections as low-risk procedures, citing the risks of serious thromboembolic events with stopping antithrombotic medications as being present in one in 200 injections relative to the risks of severe bleeding events such as an epidural hematoma as being present in only 0.0038% injections.

It should be noted that bleeding risks may not be fully addressed even with appropriate antithrombotic therapy discontinuation strategies. In their systematic review, Breivik et al (73) reported a case of spinal hematoma after lumbar interlaminar epidural steroid injection despite stopping the dabigatran 7 days prior to the injection.

In their retrospective study, Simon et al (86) report no complications or adverse events for 392 patients who underwent caudal epidural steroid injection procedures without antithrombotic therapy discontinuation.

In the literature review portion of the study, however, they do mention one report of epidural hematoma following a caudal epidural steroid injection in a patient taking cilostazol (154).

Desai & Dua (132) published a case report of a 72-year-old female undergoing right transforaminal epidural injection at L3 and L4. Four days after the injection the patient reported progressive right lower extremity weakness, worsening sensory loss, and ambulatory dysfunction. An MRI with gadolinium enhancement showed a focal abnormal signal with involvement of the right L4-5 neuroforamina that extended slightly far laterally, consistent with a small hematoma, affecting L4 nerve root. There was no history of coagulopathy. This case report shows that though extremely rare, perineural or foraminal hematoma may occur as a serious complication of transforaminal epidural injection, even in the setting of a standardized procedure. This brings attention to a rare, but important complication. Further, this is not truly an epidural hematoma, a foraminal hematoma is a much different risk as it only affects the isolated nerve root and does not result in paraplegia – this difference in anatomy is likely why there are fewer reports of true epidural hematoma following transforaminal epidural steroid injection compared to interlaminar epidural steroid injection

Gungor & Aiyer (205), in a case report, presented the development of epidural hematoma after lumbar transforaminal epidural steroid injection in a patient who had anatomical risk factor of severe lumbar spinal stenosis. The anatomic location of epidural hematoma was at the injected level, but on the contralateral side of the dura at a distance from the needle path. Epidural vascular anatomy and the potential mechanisms of bleeding in the epidural space in the absence of direct needle trauma, including the importance of injection pressures are discussed. It was described as the first reported case of an epidural hematoma on the contralateral side of the dura at a distance from the needle tip location, in the setting of severe central canal stenosis. There was no anticoagulant or antiplatelet therapy involved. There is no reasonable pathophysiologic explanation for this to suspect that the injection was related to the contralateral hematoma – the bleeding would not have crossed the midline and pass through the epidural space and then collect in the contralateral foramen. For this case report of bleed after transforaminal epidural steroid injection the details are open to discussion or controversy.

Lee et al (175) published a case report of a 79-year-

old female who had received 3 trials of transforaminal steroid injection between the right L5 and S1 vertebrae within a one-month period. One day after the last injection, she was suffering from severe pain, paresthesia, and weakness in the right lower extremity. A cyst found in the right epidural area in L5 was discovered to be compressing the thecal sac and L5 nerve root, diagnosed as an iatrogenic hemorrhagic ganglion cyst due to injection with a needle. It was treated surgically. The authors report a rare case where an asymptomatic juxtafacet cyst progressed to an iatrogenic hemorrhagic cyst as a result of an epidural steroid injection, with supplemental neurologic symptoms. This case also questions the medical necessity of the “series of three”. Thus, with a transforaminal epidural steroid injection case report, this is not actually an epidural hematoma (if it was contained in a cyst, it is much more likely they incidentally violated the facet capsule during the procedure), nonetheless this is not the same bleeding complication as a true epidural hematoma. Hence, it was removed from epidural hematoma count.

Kim et al (174) described a case report of an 82-year-old male with spinal stenosis, not taking any anticoagulant or antiplatelet drugs, who was treated with transforaminal epidural steroid injection in the right intervertebral foramen at the L2-L3 level. The next morning, he underwent emergency MRI due to severe right lower back pain and bilateral diffuse lower extremity motor deficit. Surgical evacuation was performed that evening for a rubbery, hard, clotted hematoma over the thecal sac from T12 to L1. Two weeks later, the patient was discharged without any other symptoms. The reason for the epidural hematoma could theoretically be due to increased intra-epidural pressure and can occur without risk factors such as anticoagulant drugs. Age is an unknown co-variable. Direct vascular puncture due to foraminal entry cannot be ruled out. As with other transforaminal epidural steroid injection case reports, this raises multiple issues if the bleeding originated at the L2-3 segment from the injection and the hematoma did not involve that spinal segment, it would be very unlikely for all of the blood to “travel” to T12-L1 and not have any hematoma at L2-3. It is very plausible that in this case the patient simply had an injection then coincidentally had a spontaneous epidural hematoma (or something related to pressure dynamics)

Kim et al (180) reported on 2 cases. The first patient, an 89-year-old female was diagnosed with lumbar spinal stenosis with bulging of the L2-L5 intervertebral discs for which she received transforaminal epidural

steroid injection. 24 hours after the procedure, she complained of severe lower back pain and subjective weakness in the left leg. A lumbar spine MRI showed a 14-centimeter epidural hematoma extending from the T11 to the L5 level with cord compression at T11-12-L1-4. It was treated with epidural blood aspiration. Acute, large amounts of epidural hematoma without neurological deficits developed after a transforaminal epidural steroid injection, in a patient who discontinued aspirin. Acute, large amounts of epidural hematoma without neurological deficits developed after transforaminal epidural steroid injection, in a patient who discontinued ginkgo. The team should be aware of the impacts of nontraditional herbs and medications. Since these agents do not undergo the FDA approval process many potential issues may be unknown at the time of use. The second patient, an 86-year-old female with moderate spinal stenosis in the L2-L5 region received a transforaminal epidural steroid injection. She continuously complained of pain, and an MRI performed within 3 hours revealed a large amount of epidural and subdural hematoma at the lower T-L spines and sacrum with cord compression at the T spine. Non-surgical aspiration was performed 3 hours after the procedure. The guideline author (BJS) reviewed, both of these cases. He commented that these were attempted to be transforaminal epidural steroid injection. However, based on the provided images it is highly unlikely that they were properly performed transforaminal epidural steroid injections. Both contrast patterns show the needle tip being placed too far medially and the contrast pattern in both cases appears to be intrathecal – complications from incorrectly performed procedures are unique from complications that occur when proper technique is used. Nonetheless the injection itself was likely intrathecal. The only feasible explanation is that there was a bleeding complication in the epidural space while entering the intrathecal space; however, it appears that the needle entry site may have been too small to cause the bleeding to spread to the intrathecal space. The overall conclusion is that the transforaminal epidural does not appear to be the culprit in these 2 cases, similar to the other cases described above.

Overall, lumbar epidural injections in this evaluation showed epidural hematoma formation in 22 patients, proportionately much lower than following cervical epidural procedures and a lower risk of bleeding complications considering that lumbar epidural injections are performed at a 3 to 4-fold rate. As shown in Fig. 10, of the 22 total hematoma patients, 10 were

with no anticoagulant therapy, 9 discontinued anticoagulant therapy, and only 3 continued anticoagulant therapy; 11 patients developed hematoma secondary to lumbar interlaminar epidural injections and 5 patients were secondary to lumbar transforaminal epidural injections, with 3 of them with no anticoagulant therapy, and 2 with discontinuation of the anticoagulant therapy.

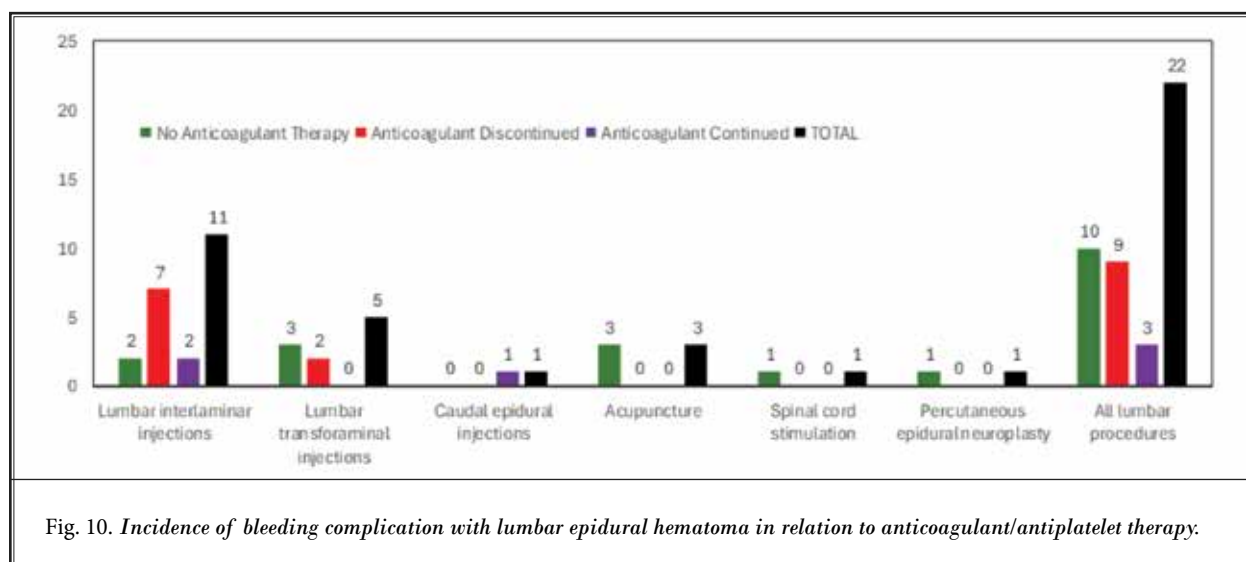
Lumbar interlaminar epidural injections have been stratified as high risk above L5 and intermediate risk below L5. Considering the nature of the reports of lumbar transforaminal epidural injections, either without antithrombotic therapy, non-discernable presentations in case reports, 0% prevalence in studies (55-58,80) or seemingly nonmajor complications related to transforaminal epidural injections, these have been stratified as low-risk procedures (53). However, it is crucial to watch for other patient risk factors when determining suitability for lumbar transforaminal epidural injections.

#### **5.4.2 Percutaneous Adhesiolysis**

Percutaneous adhesiolysis is a procedure performed using a caudal approach utilizing catheterization attempting to reach the lumbar epidural space. Manchikanti et al (55) in a prospective evaluation of antithrombotic usage with interventional techniques in chronic pain, studied 839 patients undergoing percutaneous adhesiolysis of which 493 were not on antithrombotics. Two hundred and sixteen patients were on aspirin with 148 continuing and 68 patients discontinuing aspirin. Thirty-seven patients were on clopidogrel with 21 patients continuing and 16 discontinuing. Aspirin and other drugs were utilized by 69 of the patients with 32 continuing and 37 discontinuing. Overall, when all interventional techniques were combined, there was no difference in patients whether antithrombotics were continued or discontinued with local bleeding and soreness intraoperatively, and profuse bleeding, local bleeding, bruising and soreness postoperatively.

There was only one case report in relation to percutaneous adhesiolysis with a caudal approach (198). No reports were presented in other studies. However, a case report of caudal epidural injection leading to epidural hematoma and surgical decompression is taken into consideration. Further, the majority of the patients undergoing percutaneous adhesiolysis present with multiple additional risk factors with age, spinal stenosis, multiple surgeries, dual anticoagulant therapy,





and other factors. Consequently, caudal percutaneous adhesiolysis is stratified into moderate risk. Further, percutaneous epidural adhesiolysis utilizing either an interlaminar or transforaminal approach (cervical, thoracic, and lumbar) are stratified as high risk.

#### 5.4.3 Spinal Cord Stimulation Interventions

Petraglia et al (77) also studied the incidence of spinal cord injury in the implantation of percutaneous and paddle electrodes for spinal cord stimulation, with analysis of nationwide data, and the inclusion of 8,326 patients. They showed an overall incidence of spinal cord injury of 2.1%, with an incidence of spinal hematoma of 0.71%, which was seen in 59 patients with 41 in the percutaneous group with 0.75% and 18 in the paddle lead group with 0.63%. They concluded that while reversible complications may be more common, spinal cord injury as a result of spinal cord stimulation is uncommon. Even though this was a large database, they recommended more studies to further characterize the mechanisms of injury and outcomes in these patients. They also assessed the odds ratio for using antiplatelet or anticoagulant medications within 30 days prior to spinal cord stimulation procedures. They found that the odds of spinal cord injury increased by 2.4. If the patient took any type of anticoagulant medication within 30 days prior to the procedure they found no significant increase in the odds of spinal cord injury for patients taking aspirin, clopidogrel, or enoxaparin alone.

Compared to many of the standard pain and spine interventions explored by the studies highlighted thus

far, placement of spinal cord stimulator leads confers greater risk for bleeding complications (e.g., epidural hematoma) given the use of much larger introducer needles, epidural entry typically in the T11-T12 to L1-L2 levels, placement of epidural leads in the cervical or thoracic epidural space, etc. They mention reports of spinal hematomas associated with placement and removal of temporary spinal cord stimulator trial leads, and with the permanent implantation of percutaneous and paddle leads in patients taking NSAIDs (including aspirin) (14,91). In one case, an epidural hematoma developed following the removal of a spinal cord stimulator trial lead despite the patient last taking their daily aspirin 81 mg and ibuprofen approximately 11 days prior (89).

Spinal cord stimulation lead placement has resulted in epidural hematomas in 7 patients as shown in Table 4, with 3 that were with no anticoagulant therapy, 2 discontinued anticoagulant therapy, and only 2 continued anticoagulant therapy.

Spinal cord stimulation (dorsal column and dorsal root ganglion procedures) is stratified as a high-risk procedure. Risks may be further increased with multiple comorbidities commonly seen in these patients requiring additional precautions.

#### 5.4.4 Non-epidural Spinal and Other Interventions

As discussed earlier, non-epidural spinal interventions also constitute a significant proportion of interventional techniques as shown in Fig. 6. However, the risk of bleeding with nonspinal interventions does not lead to significant morbidity and mortality. There

are very few case reports of bleeding complications with nonspinal interventions requiring significant interventions.

Among a few studies prospectively evaluating the risk of antithrombotic therapy during interventional techniques, Manchikanti et al (55) prospectively studied 3,179 patients with 12,000 encounters and 18,472 procedures. These results showed one-quarter of the patients (3,087) underwent interventional techniques and were also on antithrombotic therapy. Among these patients, among 1,711 encounters, or 55%, antithrombotic therapy was continued during the interventional techniques, whereas, for 45%, or 1,376 encounters, antithrombotic therapy was discontinued. Overall, these results illustrated that while intravascular penetration and oozing were higher in patients with continued antithrombotic therapy, bruising and local bleeding were higher in patients with discontinued antithrombotic therapy without any difference either statistical or clinical in any of the other aspects, either intraoperative, post procedure in the recovery room, or in the postoperative period. Among the intraoperative complications, intravascular entry was seen in a higher proportion of patients with aspirin with 15% compared to 5.8% for epidurals when aspirin was continued with clopidogrel 29.3% vs. 5.3% when clopidogrel was continued. However, there was no difference between facet joint interventions and epidurals when aspirin was continued. Similar findings were observed with clopidogrel, aspirin and others when antithrombotic was discontinued. Similarly, local bleeding with aspirin was higher when it was continued; 73.1% vs. 61.4% and 79.4% vs. 70.1% when it was discontinued. With clopidogrel also, similar findings were observed. For aspirin and other drugs also, facet joint interventions had a higher proportion of local bleeding. Prevalence of local hematoma was also higher for facet joint interventions, along with oozing, whereas bruising was similar in both groups. When all interventional techniques were combined, there was no difference when they were continued or discontinued. However, both groups exhibited higher levels of local bleeding and oozing, whereas soreness was less in patients on antithrombotics compared to no antithrombotics.

Endres et al (56) reported serious thromboembolic events in 9 patients out of 1,626 spinal procedures in which anticoagulants were discontinued. Anticoagulants were discontinued for the majority of interlaminar injections and radiofrequency neurotomies but continued for a majority of other procedures including

transforaminal epidural steroid injections. Adverse events with discontinuation included five strokes, one pulmonary embolism, and one myocardial infarction. Two fatalities as a consequence of these events were also reported. On the contrary, Endres et al report no bleeding complications when anticoagulants were continued across a host of spinal interventions. They conclude that most non-epidural interventions, including facet blocks, sacroiliac joint injections and trigger point injections, can be performed safely without anticoagulation discontinuation. These results were also reproduced in their follow up study (58).

Given these and additional data, the 2nd edition of the multi-society guidelines for antithrombotic therapy practices with pain procedures now lists thoracic and lumbar facet interventions (prognostic blocks and radiofrequency denervation) as low-risk procedures (14). Manchikanti et al (53) also have changed non-epidural interventions from moderate risk to low risk. This change is further emphasized for patients in whom antithrombotic therapy discontinuation poses a greater risk for thromboembolic events. Thus, all facet joint interventions including medial branch blocks and L5 dorsal ramus blocks, intraarticular injections, and radiofrequency neurotomy procedures are stratified as low-risk procedures.

Despite the demonstrated safety of nonepidural interventions in the spine and other areas, overall patient risk is crucial. In addition, considering the close proximity of spinal cord while performing facet joint intraarticular injections, the penetration of the capsule may enter the epidural space and penetrate the spinal cord. Thus, extensive arthritis, bleeding diathesis, or inexperienced interventional pain physician, the risk may be considered as intermediate to high with individual consideration and shared decision-making.

### **5.5 Risk Stratification of Interventional Techniques**

Interventional techniques performed in the spine and other regions for chronic cancer and noncancer pain patients face variable risks depending on anticoagulant or antiplatelet therapy, age, anatomy, the specific region of interest, obesity, and other comorbidities. Consequently, various authors have described procedural classification according to the potential risk for serious bleeding. Anatomical considerations and risk factors, along with drug considerations and risk factors have been described earlier. It is crucial to consider all these issues in determining the approach of

the interventional technique and the duration of interruption of anticoagulant or antiplatelet therapy.

Raj et al (164) in 2004, stratified risk scores based on technique-related bleeding risk and patient-related bleeding risk factors. This risk classification took various factors into consideration including a sharp or blunt needle, use of fluoroscopy and lack of fluoroscopy.

Breivik et al (73) in 2018, in a comprehensive topical review of reducing risk of spinal hematoma from spinal epidural and pain procedures based their recommendations on extensive review of 166 case reports published since 1994 through 2015 (81), pharmacology of drugs, and available clinical evidence relating to complications whether or not the antithrombotics were continued or discontinued. Based on a 2017 report (81), they concluded that the annual number of published cases of spinal hematoma after central neuraxial blocks increased during 1994 to 2015 compared to previous years. Case reports on elderly women accounted for this increase; however, they also emphasized that anti-hemostatic drugs, heparins in particular, continued to be major risk factors for developing post central neuraxial blockade spinal bleedings. They also described other risk factors related to hemostasis and spinal disorders and complicated blocks, especially spinal stenosis and “bloody taps,” whereas multiple attempts do not seem to increase the risk of bleeding.

Lagerkranser (81) and Lagerkranser and Lindquist (82) in their 2017 publication concluded that complications continued to occur despite following appropriate guidelines and strict adherence to the recommendations.

Douketis et al (11) showed clinical characteristics comprising the HAS-BLED (Table 17) and bleeding risk score as shown in Table 18. This provides clinical risk for hypertension, abnormal renal and liver function, stroke, bleeding tendency or predisposition, labile INRs, elderly, age, and drugs with concomitant therapy or excess alcohol use.

Further, they developed a HAS-BLED score with bleeds per 100 patient years with development of total points. However, the bleeding risk score has only been validated in patients with atrial fibrillation receiving warfarin. Even then, this has been applied across the spectrum. A HAS-BLED score of 0 shows 1.13 bleeds per year.

The second edition of *Interventional Spine and Pain Procedures in Patients On Antiplatelet and Anticoagulant Medications* by Narouze et al (14) provided guidance with significant changes based on the de-

Table 17. *Clinical characteristics comprising the HAS-BLED bleeding risk score.*

Letter	Clinical characteristic*	Points
H	Hypertension (i.e., uncontrolled blood pressure)	1
A	Abnormal renal and liver function (1 point each)	1 or 2
S	Stroke	1
B	Bleeding tendency or predisposition	1
L	Labile INRs (for patients taking warfarin)	1
E	Elderly (age greater than 65 years)	1
D	Drugs (concomitant aspirin or NSAIDs) or excess alcohol use (1 point each)	1 or 2
		Maximum 9 points

The HAS-BLED bleeding risk score has only been validated in patients with atrial fibrillation receiving warfarin. Refer to UpToDate topics on anticoagulation in patients with atrial fibrillation and on specific anticoagulants for further information and other bleeding risk scores and their performance relative to clinical judgment.

INR: international normalized ratio; NSAIDs: nonsteroidal anti-inflammatory drugs.

\* Hypertension is defined as systolic blood pressure >160 mmHg. Abnormal renal function is defined as the presence of chronic dialysis, renal transplantation, or serum creatinine  $\geq$ 200 micromol/L. Abnormal liver function is defined as chronic hepatic disease (eg, cirrhosis) or biochemical evidence of significant hepatic derangement (eg, bilirubin more than 2 times the upper limit of normal, plus 1 or more of aspartate transaminase, alanine transaminase, and/or alkaline phosphatase more than 3 times the upper limit of normal). Bleeding predisposition includes chronic bleeding disorder or previous bleeding requiring hospitalization or transfusion. Labile INRs for a patient on warfarin include unstable INRs, excessively high INRs, or <60% time in therapeutic range.

Source: Douketis JD, Lip GYH. Perioperative management of patients receiving anticoagulants. UpToDate 2023. Accessed 12/6/2023. <https://www.uptodate.com/contents/perioperative-management-of-patients-receiving-anticoagulants/print> (11).

Table 18. *HAS-BLED Bleeding risk score.*

HAS-BLED score (total points)	Bleeds per 100 patient-years †
0	1.13
1	1.02
2	1.88
3	3.74
4	8.70
5 to 9	Insufficient data

† Based on initial validation cohort from Pisters R. A novel-user-friendly score (HAS-BLED) to assess 1- year risk of major bleeding in patients with atrial fibrillation: the Euro Heart Survey. *Chest* 2010; 138:1093. Actual rates of bleeding in contemporary cohorts may vary from these estimates. Source: Douketis JD, Lip GYH. Perioperative management of patients receiving anticoagulants. UpToDate 2023. Accessed 12/6/2023. <https://www.uptodate.com/contents/perioperative-management-of-patients-receiving-anticoagulants/print> (11).

velopment of new anticoagulants and antiplatelet medications, as well as publications evaluating bleeding complications in patients undergoing specific interventional spine and pain procedures including facet procedures, epidural injections, percutaneous spinal cord stimulator trials, and implantations, celiac plexus blocks, and intrathecal drug delivery systems (56,63,97,99).

ASIPP guidelines published in 2019, 2020, and 2021 (1,52,54) were based on extensive analysis of the data with available publications.

Deer et al (76) provided recommendations on bleeding and coagulation management in patients undergoing neurostimulation devices. They also provided bleeding risk stratifications for neuromodulation procedures.

The risk stratification for interventional techniques was developed as before based on the available literature in reference to the adverse consequences of anticoagulant and antiplatelet therapy, thromboembolic risk, and risks related to interventional techniques. Risk stratification of each procedure included for the majority of interventional techniques was based on anatomical risk factors, procedural risk factors, bleeding risk factors, anticoagulant/antiplatelet therapy related risk factors, and medical or physiologic risk factors.

- Anatomical risk factors are related to the location of the needle placement, structural abnormalities, vasculature, and other structures and if the procedure is performed into a closed cavity with risks ranging from 1 to 4.
- Procedural risk factors are based on historical presentation of bleeding and hematoma risk, multiple attempts, traumatic procedure, specifically into closed cavities in conjunction with anatomical factors with risks ranging from 1 to 4.
- Bleeding risk is based on reports of epidural hematoma and other bleedings reports with spontaneous and traumatic occurrence without antithrombotic therapy and after cessation of antithrombotic therapy with the risks ranging from 1 to 4. Further, antiplatelet and anticoagulant risk is based on the pharmacology of the drug, dual antithrombotic therapy, variations in metabolism, dependence on renal and hepatic function.
- Medical or physiological factors include multiple medical disorders including various conditions leading to anticoagulant and antiplatelet therapy, age, diabetes, obesity, hypertension, vascular abnormalities with aneurysms, etc. age, renal and hepatic functional status with risks ranging from 1 to 4.

Table 10 shows factors associated with increased bleeding risk, including advanced age (older than 75 years), frailty, anemia with hemoglobin (< 11.0 g/L), chronic renal failure, low body weight, hospitalization for bleeding within the past year, previous stroke/intracranial bleed, regular need for NSAIDs or prednisone; thus, these risk scores change on an individual basis. Consequently, a clinician may update the risk based on medical and physiological factors.

Further, Table 17 shows HAS-BLED bleeding risk score showing multiple clinical characteristics yielding various points, whereas Table 18 shows HAS-BLED bleeding risk score. It is also important to take into consideration thromboembolic risk in patients with atrial fibrillation as shown in Table 11, which includes multiple risk factors described thus far.

Risk was calculated based on total score. A total score of 8 or less was considered as low risk, a total score of 9-12 was considered as moderate or intermediate risk, and, finally, a total score of 13 or above was considered as high risk. Any of the added factors increase the risk from low risk to moderate or intermediate risk and moderate or intermediate risk to high risk.

Table 19 shows all procedures with their risk stratification with risk scores varying from 5 to 20, with 4 being the lowest score and 20 being the highest score. Nineteen procedures were considered as low risk, 7 procedures were considered as moderate or intermediate risk, and finally 24 procedures were considered as high risk.

Based on the above analysis, the classification for interventional techniques has been developed as shown in Table 20 with incorporation of the present evidence and available guidelines (1,14,52). The classification in this table describes low risk, moderate or intermediate risk and high risk. However, based on comorbid medical conditions and other risk factors of coagulopathies and concurrent use of other anticoagulants and antiplatelets, the procedural risk classification will be changed from low risk to moderate or intermediate, and moderate or intermediate to high risk.

## 5.6 Perioperative Management

Douketis and Lip (11), in developing perioperative management of patients receiving anticoagulants and antiplatelet therapy, developed an approach which included the following:

- Estimation of thromboembolic and bleeding risk
- Determination of the timing of anticoagulant or

Table 19. Risk stratification of interventional techniques based on anatomical risk factors, procedural risk factors, bleeding risk, antiplatelet/anticoagulant risk, and medical or physiological status.

	Anatomical Risk Factors	Procedural Risk Factors	Bleeding Risk	Antiplatelet / Anticoagulant Risk	Medical or Physiologic (Variable) Risk	Total Risk
<b>EPIDURALS</b>						
Caudal epidural injection *	3	2	2	1	2	10
Lumbar interlaminar epidural injection at L5-S1	3	3	1	1	2	10
Lumbar interlaminar epidural injection above L5	4	3	3	3	2	15
Thoracic interlaminar epidural injection	4	4	4	4	2	18
Cervical interlaminar epidural injection	4	4	4	4	2	18
Lumbar transforaminal epidural injection at L3, L4, L5, and S1	2	2	1	1	2	8
Lumbar transforaminal epidural injection at L1 and L2	3	3	2	2	2	12
Thoracic transforaminal epidural injection	3	3	2	2	2	12
Cervical transforaminal epidural injection	3	3	2	2	2	12
Caudal epidural adhesiolysis *	3	3	2	2	2	12
Percutaneous adhesiolysis with transforaminal approach in lumbar, thoracic, and cervical spine	4	4	2	2	2	14
Percutaneous adhesiolysis with interlaminar approach in lumbar, thoracic, and cervical spine	4	4	4	4	2	18
<b>FACET JOINT INTERVENTIONS</b>						
Lumbar medial branch and L5 dorsal ramus blocks	2	2	1	1	1	7
Thoracic medial branch blocks	2	2	1	1	1	7
Cervical medial branch blocks	2	2	1	1	1	7
Lumbar intraarticular injections	2	2	1	1	1	7
Thoracic intraarticular injections	2	2	1	1	1	7
Cervical intraarticular injections	2	2	1	1	1	7
Lumbar radiofrequency neurotomy	2	2	1	1	1	7
Thoracic radiofrequency neurotomy	2	2	1	1	1	7
Cervical radiofrequency neurotomy	2	2	1	1	1	7
<b>SACROILIAC JOINT INTERVENTIONS</b>						
Sacroiliac joint injections/nerve blocks	1	1	2	1	1	6
Sacroiliac joint nerve radiofrequency	1	1	2	1	1	6
Sacroiliac joint fusion	4	4	1	3	2	14
<b>MINOR PROCEDURES</b>						
Trigger point and intramuscular injections (including piriformis injection)	1	1	1	1	1	5
Peripheral nerve blocks including mandibular and maxillary nerve blocks	1	1	1	1	1	5
Intraarticular injections of extremity joints	1	1	1	1	1	5

Table 19 cont. Risk stratification of interventional techniques based on anatomical risk factors, procedural risk factors, bleeding risk, antiplatelet/anticoagulant risk, and medical or physiologic status.

	Anatomical Risk Factors	Procedural Risk Factors	Bleeding Risk	Antiplatelet / Anticoagulant Risk	Medical or Physiologic (Variable) Risk	Total Risk
<b>SYMPATHETIC BLOCKS</b>						
Ganglion impar blocks	1	1	1	1	2	6
Hypogastric plexus blocks	3	4	2	2	2	13
Lumbar sympathetic blocks	3	4	2	2	2	13
Celiac plexus blocks	3	4	2	2	2	13
Splanchnic sympathetic blocks	3	4	2	2	2	13
Thoracic sympathetic blocks	4	4	3	3	2	16
Stellate ganglion blocks	4	4	3	3	2	16
Trigeminal ganglion, ophthalmic division, and sphenopalatine ganglion blocks	4	4	3	4	2	17
<b>NEUROMODULATION PROCEDURES</b>						
Dorsal column and dorsal root ganglion stimulator trial and implantation	4	4	4	4	2	18
Intrathecal catheter and pump implant	4	4	4	4	2	18
Pocket revision and implantable pulse generator/intrathecal pump replacement	1	1	1	2	2	7
Peripheral nerve stimulation trial and implantation of extremities	1	1	1	1	1	5
Peripheral nerve stimulation trial and implantation of lumbar medial branches	2	2	2	2	2	10
Peripheral nerve stimulation trial and implantation of thoracic medial branches	4	3	3	3	2	15
Peripheral nerve stimulation trial and implantation of cervical medial branches	4	3	3	3	3	16
Trigeminal branch nerve blocks (mandibular, maxillary, and other branches)	2	1	1	1	1	6
Trigeminal and cranial nerve blocks and stimulation	4	4	2	4	2	16
<b>INTRADISCAL, INTERSPINOUS, AND DECOMPRESSION PROCEDURES</b>						
Lumbar discography and intradiscal procedures	4	4	1	4	2	15
Thoracic discography and intradiscal procedures	4	4	1	4	2	15
Cervical discography and intradiscal procedures	4	4	1	4	2	15
Percutaneous and endoscopic disc decompression procedures	4	4	1	4	2	15
Vertebral augmentation (sacral, lumbar, thoracic, and cervical)	4	4	1	2	2	13
Minimally invasive lumbar decompression (MILD)	4	4	4	4	2	18
Intervertebral spinous prosthesis including lateral fusion	4	4	1	4	2	15
Intrapect procedure	4	4	1	3	2	14

\* Change from 2019 guidelines

Table 20. ASIPP's classification of interventional techniques based on the potential risk for bleeding compared to ASRA guidelines (14).

Low-Risk Procedures	ASRA	ASIPP	Moderate or Intermediate-Risk Procedures**	ASRA**	ASIPP	High-Risk Procedures**	ASRA**
<ol style="list-style-type: none"> <li>1. Trigger point and intramuscular injections (including piriformis injection)</li> <li>2. Peripheral nerve blocks including mandibular and maxillary nerve blocks</li> <li>3. Sacroiliac joint and ligament injections and nerve blocks</li> <li>4. Facet joint interventions (intra-articular injections, medial branch and L5 dorsal ramus nerve blocks and radiofrequency neurotomy)</li> <li>5. Intraarticular injections of extremity joints</li> <li>6. Pocket revision and implantable pulse generator/intrathecal pump replacement</li> <li>7. Peripheral nerve stimulation trial and implantation of extremities</li> <li>8. Lumbar transforaminal epidural injections at L3, L4, L5, and S1</li> <li>9. Ganglion impar blocks</li> <li>10. Sacroiliac joint nerve radiofrequency</li> <li>11. Trigeminal branch nerve blocks (mandibular, maxillary, and other branches)</li> </ol>	<ol style="list-style-type: none"> <li>1. Trigger point injections including piriformis injection</li> <li>2. Peripheral nerve blocks</li> <li>3. Sacroiliac joint injection and sacral lateral branch blocks</li> <li>4. Thoracic and lumbar facet medial branch nerve block and radiofrequency ablation</li> <li>5. Peripheral joints and musculoskeletal injections</li> <li>6. Pocket revision and implantable pulse generator/intrathecal pump replacement</li> <li>7. Peripheral nerve stimulation trial and implantation of extremities</li> </ol>	<ol style="list-style-type: none"> <li>1. Caudal epidural injections*</li> <li>2. Caudal epidural adhesiolysis*</li> <li>3. Lumbar interlaminar epidural injection at L5, S1</li> <li>4. Cervical, thoracic, and lumbar transforaminal at L1 and L2</li> <li>5. Peripheral nerve and implantation of lumbar medial branches</li> </ol>	<ol style="list-style-type: none"> <li>1. Transforaminal epidural steroid injections (cervical, thoracic, lumbar, sacral)</li> <li>2. Intradiscal procedures (cervical, thoracic, lumbar)</li> <li>3. Sympathetic blocks (stellate, thoracic, splanchnic, celiac, lumbar, hypogastric)</li> <li>4. Interlaminar epidural steroid injections (cervical, thoracic, lumbar, sacral)</li> <li>5. Cervical† facet medial branch nerve block and radiofrequency ablation</li> <li>6. Trigeminal and sphenopalatine ganglia blocks</li> </ol>	<ol style="list-style-type: none"> <li>1. Cervical, thoracic, and lumbar (above L5) interlaminar epidurals</li> <li>2. Peripheral nerve stimulation trial and implantation of thoracic and cervical medial branches.</li> <li>3. Trigeminal ganglion, ophthalmic division, and sphenopalatine ganglion blocks</li> <li>4. Discography and intradiscal procedures (lumbosacral, cervical, and thoracic)</li> <li>5. Dorsal column and dorsal root ganglion stimulator trial and implantation</li> <li>6. Intrathecal catheter and pump implant</li> <li>7. Vertebral augmentation (sacral, lumbar, thoracic, and cervical)</li> <li>8. Percutaneous and endoscopic disc decompression procedures</li> <li>9. Minimally invasive lumbar decompression (MILD)</li> <li>10. Trigeminal and cranial nerve blocks and stimulation</li> <li>11. Sympathetic blocks (stellate ganglion, thoracic sympathetic, splanchnic, celiac plexus, lumbar sympathetic, hypogastric plexus)</li> <li>12. Percutaneous adhesiolysis with interlaminar or transforaminal approach (cervical, thoracic, and lumbar)</li> <li>13. Intervertebral spinous prosthesis including lateral fusion</li> <li>14. Sacroiliac joint fusion</li> <li>15. Intracept procedure</li> </ol>	<ol style="list-style-type: none"> <li>1. Spinal cord stimulation trial and implant</li> <li>2. Intrathecal catheter and pump implant</li> <li>3. Vertebral augmentation (vertebroplasty and kyphoplasty)</li> <li>4. Percutaneous decompression laminotomy</li> <li>5. Epiduroscopy and epidural decompression</li> <li>6. Dorsal root ganglion stimulation**</li> </ol>		

ASIPP: American Society of Interventional Pain Physicians; ASRA: American Society of Regional Anesthesia and Pain Medicine

\*Change from 2019 guidelines.

\*\*Patients with high risk of bleeding (e.g., old age, history of bleeding tendency, concurrent uses of other anticoagulants/antiplatelets, liver cirrhosis or advanced liver disease, and advanced renal disease) undergoing low or intermediate-risk procedures should be treated as intermediate or high risk, respectively.

†There is rich neck vascularity in the vicinity of the target structure(s) (refer to the section entitled Anatomical Considerations for Hematoma Development in Spinal and Nonspinal Areas).

‡Peripheral neuromodulation is low to intermediate risk, depending on the location of the targeted nerve in relation to critical vessels and the invasiveness of the procedure. Source(s): Manchikanti L, et al. Epidural interventions in the management of chronic spinal pain: American Society of Interventional Pain Physicians (ASIPP) comprehensive evidence-based guidelines. *Pain Physician* 2021; 24:S27-S208 (52); Kaye AD, et al. Responsible, safe, and effective use of antithrombotics and anticoagulants in patients undergoing interventional techniques: American Society of Interventional Pain Physicians (ASIPP) guidelines. *Pain Physician* 2019; 22:S75-S128 (1); and Narouze S, Benzon HT, Provenzano D, et al. Interventional spine and pain procedures in patients on antiplatelet and anticoagulant medications (Second Edition): Guidelines from the American Society of Regional Anesthesia and Pain Medicine, the European Society of Regional Anesthesia and Pain Therapy, the American Academy of Pain Medicine, the International Neuromodulation Society, the North American Neuromodulation Society, and the World Institute of Pain. *Reg Anesth Pain Med* 2018; 43:225-262 (14).

- antiplatelet therapy interruption
- Determination of whether to use bridging anticoagulation
- Determination of timing of restarting of anticoagulant or antiplatelet therapy

### 5.6.1 Estimation of Thromboembolic and Bleeding Risk

Douketis and Lip (11) showed neuraxial anesthesia and epidural injections under high-risk with high bleed risk surgery procedures with a 30-day risk of major bleed > 2%. They also considered dental procedures as low risk with continuation of antiplatelets and anticoagulants in most patients during these procedures. The risk classification of perioperative thrombotic risk is high, moderate, and low. Thus, interventional pain physicians can determine the perioperative thrombotic risk.

Specific considerations have been provided for neuraxial invasive procedures including neuraxial interventional procedures and surgical interventions (124,125,382). Thus, any procedures requiring entering the epidural space must be considered as a potential major bleeding risk intervention that requires complete hemostatic function. The overall incidences of neuraxial hematoma, based on the old literature continues to be quoted as estimated as 1/220,000 patients for epidural anesthesia or interventions (383). However, in the presence of risk factors such as multiple attempts, spinal abnormalities, inherited or acquired coagulopathies, and heparin administration, the bleeding risk can be increased by up to two orders of magnitude.

Risk stratification of interventional techniques is shown in Tables 19 and 20, which also shows comparisons with ASRA guidelines (14). Multiple procedures as shown below are included in the high-risk category, which are crucial in interventional pain management.

1. Cervical, thoracic, and lumbar (above L5) interlaminar epidurals
2. Peripheral nerve stimulation trial and implantation of thoracic and cervical medial branches.
3. Trigeminal ganglion, ophthalmic division, and sphenopalatine ganglion blocks
4. Discography and intradiscal procedures (lumbosacral, cervical, and thoracic)
5. Dorsal column and dorsal root ganglion stimulator trial and implantation
6. Intrathecal catheter and pump implant
7. Vertebral augmentation (sacral, lumbar, thoracic, and cervical)
8. Percutaneous and endoscopic disc decompression

procedures

9. Minimally invasive lumbar decompression (MILD)
10. Trigeminal and cranial nerve blocks and stimulation
11. Sympathetic blocks (stellate ganglion, thoracic sympathetic, splanchnic, celiac plexus, lumbar sympathetic, hypogastric plexus)
12. Percutaneous adhesiolysis with interlaminar or transforaminal approach (cervical, thoracic, and lumbar)
13. Intervertebral spinous prosthesis including lateral fusion
14. Sacroiliac joint fusion
15. Intrarecept procedure

These differ from ASRA guidelines, which listed the following in the high-risk category:

1. Spinal cord stimulation trial and implant
2. Intrathecal catheter and pump implant
3. Vertebral augmentation (vertebroplasty and kyphoplasty)
4. Percutaneous decompression laminotomy
5. Epiduroscopy and epidural decompression
6. Dorsal root ganglion stimulation

Evidence was developed based on the literature as provided earlier; however, evidence was not available for multiple procedures which was based on consensus derived from anatomic, procedural, and patient risk factors.

Moderate or intermediate risk procedures include the following:

1. Caudal epidural injections
2. Caudal epidural adhesiolysis
3. Lumbar interlaminar epidural injection at L5, S1
4. Cervical, thoracic, and lumbar transforaminal at L1 and L2
5. Peripheral nerve stimulation trial and implantation of lumbar medial branches

In contrast, ASRA guidelines showed the following procedures into intermediate risk:

1. Transforaminal epidural steroid injections (cervical, thoracic, lumbar, sacral)
2. Intradiscal procedures (cervical, thoracic, lumbar)
3. Sympathetic blocks (stellate, thoracic, splanchnic, celiac, lumbar, hypogastric)
4. Interlaminar epidural steroid injections (cervical, thoracic, lumbar, sacral)
5. Cervical facet medial branch nerve block and radiofrequency ablation



6. Trigeminal and sphenopalatine ganglia blocks

A significant proportion of patients are included in the low-risk category. These include:

1. Trigger point and intramuscular injections (including piriformis injection)
2. Peripheral nerve blocks including mandibular and maxillary nerve blocks
3. Sacroiliac joint and ligament injections and nerve blocks
4. Facet joint interventions (intra-articular injections, medial branch and L5 dorsal ramus nerve blocks and radiofrequency neurotomy)
5. Intraarticular injections of extremity joints
6. Pocket revision and implantable pulse generator/ intrathecal pump replacement
7. Peripheral nerve stimulation trial and implantation of extremities
8. Lumbar transforaminal epidural injections at L3, L4, L5, and S1
9. Ganglion impar blocks
10. Sacroiliac joint nerve radiofrequency
11. Trigeminal branch nerve blocks (mandibular, maxillary, and other branches)

This is in contrast to ASRA guidelines which include the following:

1. Trigger point injections including piriformis injection
2. Peripheral nerve blocks

3. Sacroiliac joint injection and sacral lateral branch blocks

4. Thoracic and lumbar facet medial branch nerve block and radiofrequency ablation
5. Peripheral joints and musculoskeletal injections
6. Pocket revision and implantable pulse generator/ intrathecal pump replacement
7. Peripheral nerve stimulation trial and implant

**5.6.2 Determination of Timing of Anticoagulant Interruption**

Determination of timing of anticoagulant use and its interruption is an extremely important aspect and variable among the specialties and authors (1,10-15,52-54,74-87,127,381,384-412). However, these risk stratifications and recommendations are based on noninterventional techniques as low, medium, or high risk, or minor or major surgery. In general, these recommendations show aspirin to be continued for all types of surgeries and cessation of Rivaroxaban (Xarelto), Apixaban (Eliquis), Endoxaban (Savaysa, Lixiana) for 24 hours for minor surgery and 48 hours for major surgery. Further, these recommendations show clopidogrel (Plavix), prasugrel (Effient) and ticagrelor (Brilinta) to be held for 5-7 days, both for minor and major surgery (384). Table 21 shows a sample recommended preoperative withholding times of oral antiplatelet and anticoagulant drugs (384).

Table 21. Recommended preoperative withholding times of oral antiplatelet and anticoagulant drugs.

Drug	Half-life	Time to withhold prior to		Time to restart after	
		Minor surgery	Major surgery	Minor surgery	Major surgery
Warfarin (Coumadin)	20–60 h	3–5 days*	3–5 days	24 h, overlapping therapy with heparin	48–72 h; overlapping therapy with heparin
Apixaban (Eliquis)	8–15 h	24 h**	48 h**	24 h	24–48 h
Rivaroxaban (Xarelto)	5–9 h (Elderly: 11–13 h)	24 h**	48 h**	24 h	24–48 h
Edoxaban (Savaysa, Lixiana)	10–14 h	24 h**	48 h**	24 h	24–48 h
Betrixaban (Bevyxxa)	19–27 h	≥ 4 days	≥ 4 days	24 h	24–48 h
Dabigatran (Pradaxa)	12–17 h	CrCl > 50 mL: 24 h CrCl < 50 mL: 75 h	CrCl > 50 mL: 72 h CrCl < 50 mL: 120 h	24 h	24–48 h
Aspirin	7–10 days	usually continued	usually continued	usually continued	usually continued
Clopidogrel (Plavix)	7–10 days	5–7 days	5–7 days	24 h	24–48 h
Prasugrel (Effient)	7–10 days	5–7 days	5–7 days	24 h	24–48 h
Ticagrelor (Brilinta)	5–7 days	3–5 days	3–5 days	24 h	24–48 h

\*In some cases, continued drug administration is feasible

\*\*In case of impaired renal function, withholding interval should be prolonged and/or drug level should be evaluated by laboratory tests

CrCl: creatinine clearance

Adapted and modified: Moster M, Bolliger D. Perioperative guidelines on antiplatelet and anticoagulant agents: 2022 update. *Curr Anesthesiol Rep* 2022; 12:286-296 (384).

Figure 11 shows perioperative management of warfarin and low molecular weight heparin based on risk category. Based on these recommendations by Douketis et al (10), warfarin is continued for minimal bleed risk, whereas low to moderate bleed risk, as well as high bleed risk, warfarin was stopped for 5 days. These guidelines are not uniform. As shown in Table 21, Moster and Bollinger (384) recommended it to be stopped for 3-5 days. Individualized care may achieve an appropriate INR below 1.5 after stopping for 2 days. Figure 11 also shows initiation of low molecular heparin therapy, which has been questioned and no longer a recommendation as it increases the risk.

Figure 12 shows managing DOAC therapy based on procedure bleeding risk. It is recommended to stop Apixaban (Eliquis), Dabigatran (Pradaxa) (CrCl ≥ 50 mL/min), Edoxaban (Savaysa, Lixiana), and Rivaroxaban (Xarelto) one day before the procedure, whereas for high risk, they recommend stopping 2 days before the procedure and resumption on the second day. They also show that in patients with renal dysfunction on Dabigatran with creatine clearance < 50 mL per minute, the interruption is 2 days for low and moderate risk categories and 4 days for high-risk category.

Figure 13 shows recommended perioperative withholding times of antiplatelet or anticoagulant drugs for interventional procedures, similar to other recommendations.

These recommendations show that for high-risk procedures, aspirin, clopidogrel (Plavix), and prasugrel (Effient) are discontinued 6 days prior to the procedures and resumed after one day. In reference to ticagrelor (Brilinta), it is discontinued for 5 days and resumed after one day. For ticlopidine (Ticlid), which has been discontinued in the United States, for high-risk procedures, it is stopped for 7 days and resumed after one day. For intermediate or moderate-risk procedures, aspirin is stopped for 3 days, clopidogrel (Plavix) for 5 days, prasugrel (Effient) for 5 days, ticagrelor (Brilinta) for 3 days, and ticlopidine (Ticlid) for 7 days with resuming intake after one day. For low-risk procedures, recommendations are highly variable based on our evidence and previous recommendations and the literature. For low-risk procedures, all of the drugs may be continued or stopped as in intermediate or moderate risk procedures.

Figure 14 shows perioperative management of patients receiving DOACs during interventional proce-

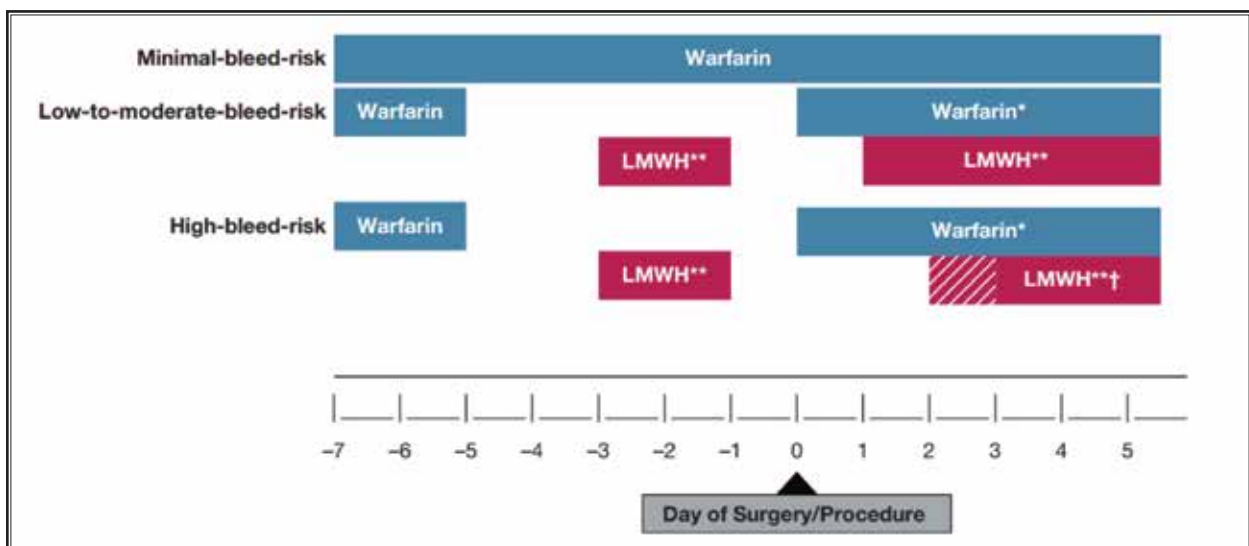


Fig. 11. Perioperative management of vitamin K antagonists (warfarin) and LMWH = low-molecular-weight heparin.

\*Warfarin can be resumed on the evening of procedure (D0) for most patients, or the day after procedure (i.e., D1) at the patient's usual maintenance dose.

\*\*Bridging suggested for high thrombotic risk populations with full-dose, subcutaneous LMWH (e.g., enoxaparin, 1 mg/kg bid or 1.5 mg/kg daily or dalteparin, 100 IU/kg bid or 200 IU/kg daily), with the last dose given the AM of the day prior to the procedure (i.e., D-1) at half the total daily dose.

†Low-dose LMWH (e.g., enoxaparin, 40 mg daily or dalteparin 5,000 IU daily) can be used for VTE prophylaxis for first 24-72 hours post-procedure, with full dose LMWH resumed 2-3 days post-procedure. Day of Surgery/Procedure

Source: Douketis JD, Spyropoulos AC, Murad MH, et al. Perioperative management of antithrombotic therapy: An American College of Chest Physicians Clinical Practice Guideline. *Chest* 2022; 162:e207-e243 (10).

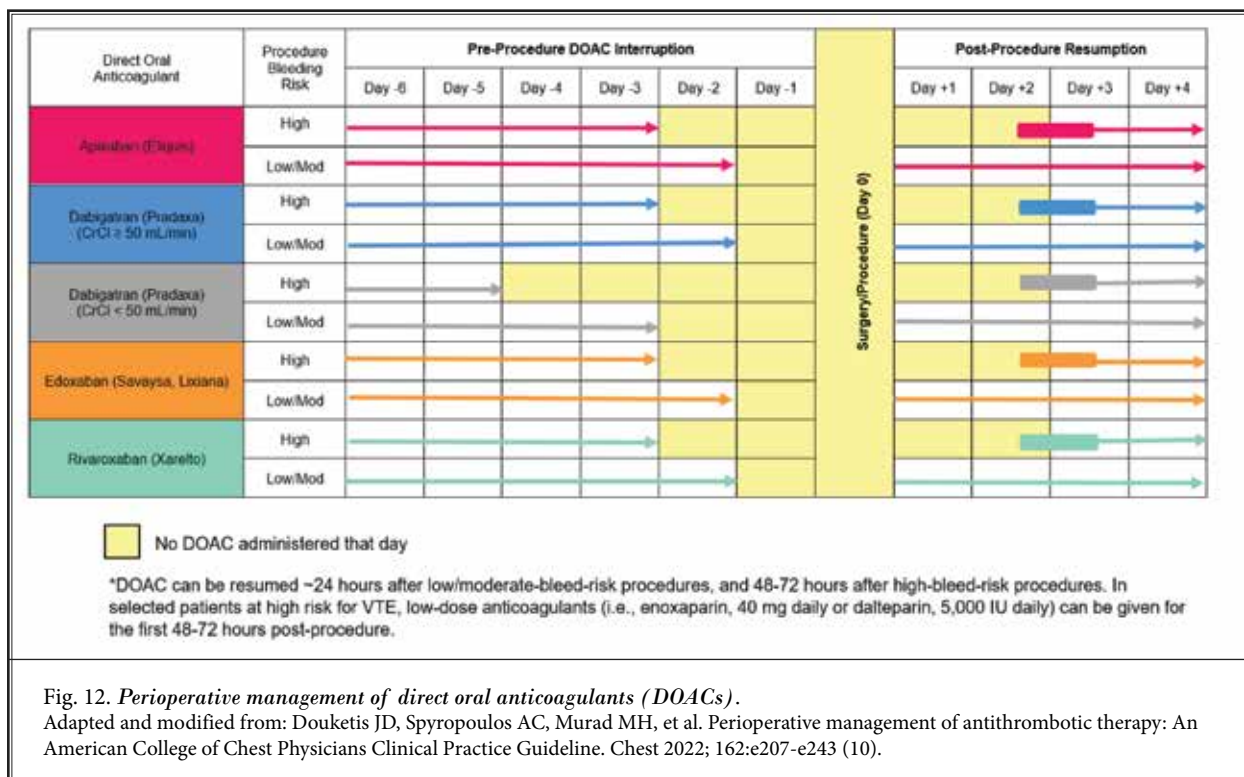


Fig. 12. Perioperative management of direct oral anticoagulants (DOACs).

Adapted and modified from: Douketis JD, Spyropoulos AC, Murad MH, et al. Perioperative management of antithrombotic therapy: An American College of Chest Physicians Clinical Practice Guideline. Chest 2022; 162:e207-e243 (10).

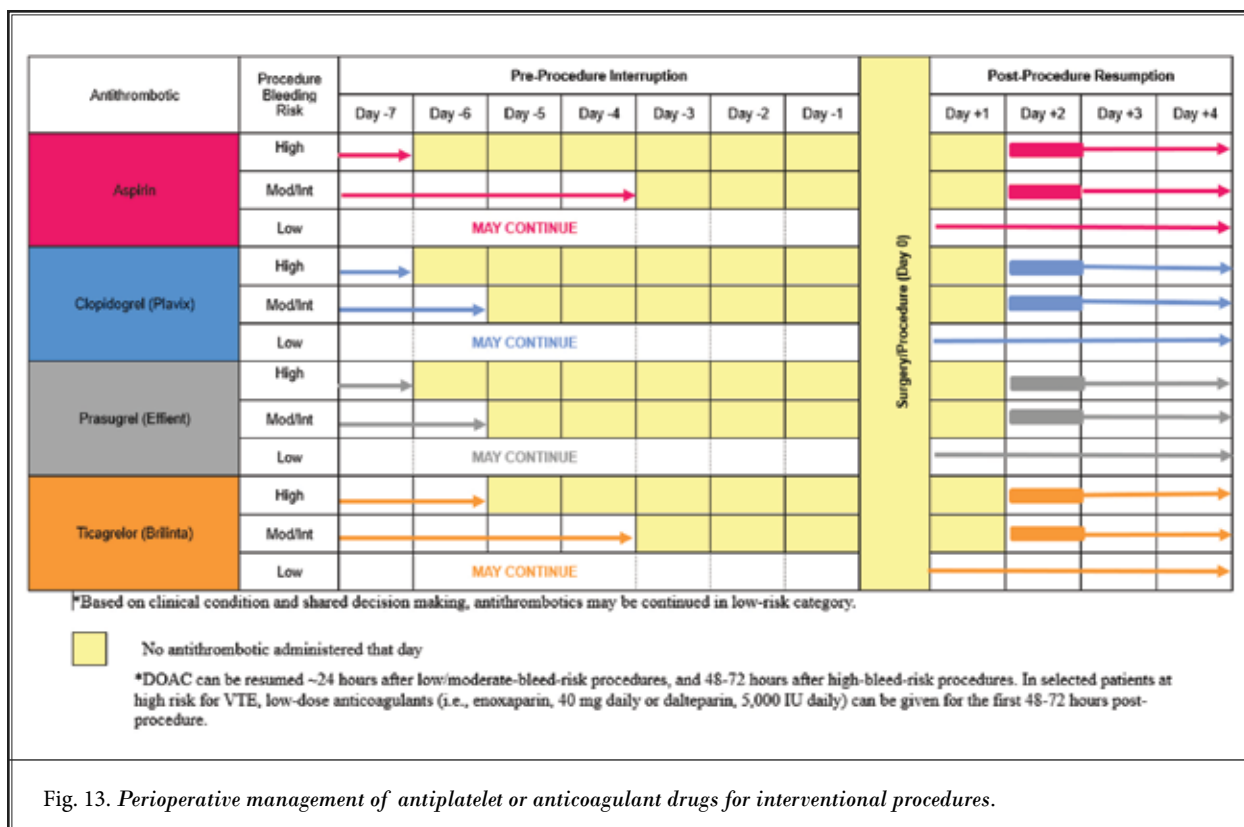


Fig. 13. Perioperative management of antiplatelet or anticoagulant drugs for interventional procedures.

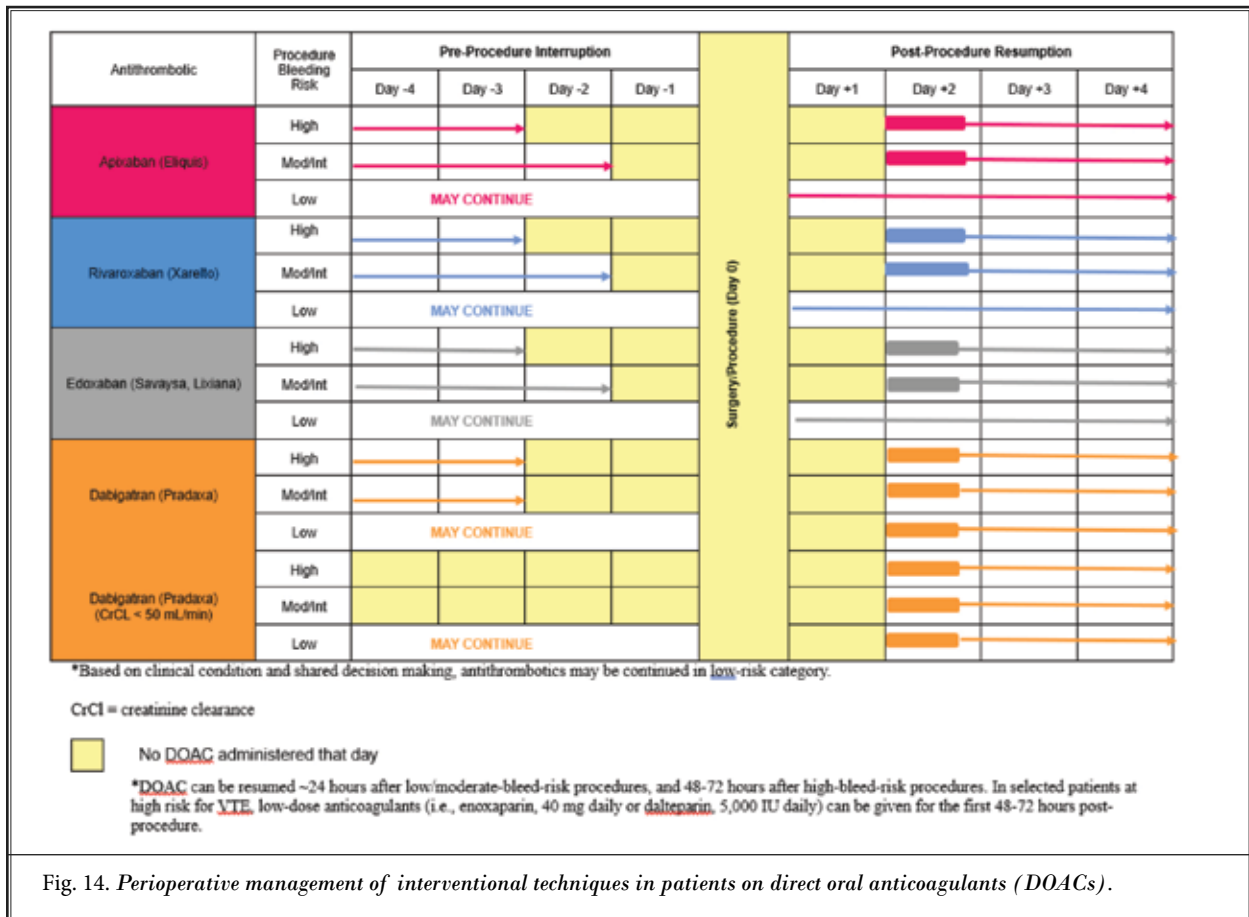


Fig. 14. Perioperative management of interventional techniques in patients on direct oral anticoagulants (DOACs).

dures. Perioperative management of DOACs is similar to recommendations as described by medical guidelines in Fig. 12 (10).

For patients in the high-risk category, DOAC interruption is 2 days prior to the procedure, the day of the procedure, and one day following the procedure, leading to a total cessation of 4 days unless creatinine clearance is less than 50 mL per minute, in which case dabigatran (Pradaxa), is stopped for 4 days with resuming it on day 2 with a total cessation of 6 days. For intermediate or moderate risk category, pre-procedural cessation of DOACs is a total of 2 days, the day before and the day of the procedure, and they can be resumed on the next day. Similar to the high-risk category for dabigatran (Pradaxa), the cessation for moderate or intermediate category is 2 days and resumption on the first day, totaling cessation of 3 days.

For low-risk category, the recommendation is that there is no need of cessation; however, based on other variables, it may be changed to moderate or interme-

diante category and follow the recommendations for intermediate risk category.

In reference to warfarin (Coumadin), Douketis et al (10,11) recommended continuing for minimal bleed risk. For low to moderate bleed risk, they recommend warfarin to be withheld for 5 days with bridging, even though the guidance states lack of value of bridging.

However, for interventional procedures, a 1 to 3-day interruption is recommended to achieve an optimal INR of  $\leq 3.0$  for low-risk procedures, 2 to 3 day interruption with an optimal INR of  $\leq 2.0$  for intermediate risk or moderate risk procedures and 3 to 5 day interruption for optimal INR of  $\leq 1.5$  for high-risk procedures.

Low molecular weight heparin bridging may be considered for high-risk surgical procedures such as spinal cord stimulators and intrathecal implantables. The trial may also be shortened. Bridging may be performed by a cardiologist, or if a cardiologist recommends, interventional pain physician may perform.

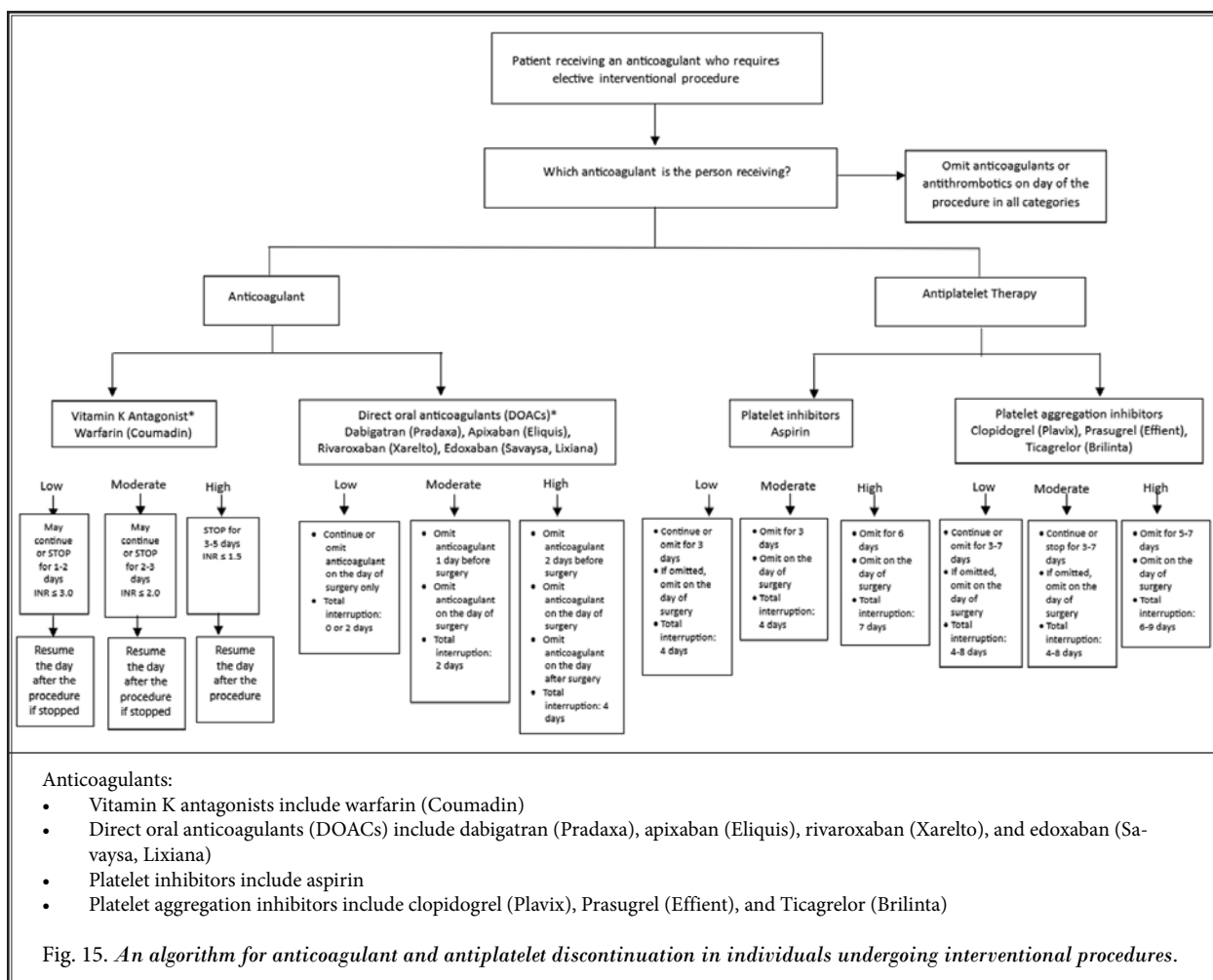
Based on the above, the following algorithm

has been developed for interventional techniques (Fig. 15) for patients on anticoagulant or antiplatelet therapy.

### 5.6.2.1 Bridge Therapy

Interventional pain physicians commonly encounter patients on oral anticoagulation for various indications, such as atrial fibrillation, venous thromboembolism, and the presence of a mechanical heart valve. The guidance as to whether to bridge these patients to heparin (or low molecular weight heparin) prior to procedures has evolved over time. It was previously thought that all patients on oral anticoagulation should be bridged, given the increased risk of stroke and venous thromboembolism with discontinuation of these medications. However, more recent studies suggest that, for certain patients, the risks of bridging may outweigh the benefits.

One meta-analysis of 34 studies (total of 12,278 patients included) of patients on vitamin K antagonists undergoing elective procedures found no difference in the risk of thrombotic events between bridged and unbridged groups (385). This was further confirmed in two more recent large randomized controlled trials, the PERIOP2 and BRIDGE trials. These trials assessed the benefit of bridging patients on warfarin in the perioperative period. Both studies found that there was no reduction in thromboembolic events in the bridged group compared to the group receiving placebo (386,387). For patients on DOACs, the Perioperative Anticoagulation Use for Surgery Evaluation (PAUSE) study looked at 3,000 patients with atrial fibrillation and found that a perioperative management strategy involving discontinuing DOACs in the perioperative period without utilizing heparin bridging resulted in low rates of thromboembolic events (15). Furthermore,



it has been shown that patients treated with bridge therapy have an increased risk for bleeding compared to those not bridged (385,386).

The decision on whether to bridge patients should be made on a case-by-case basis. Though not all patients require bridge therapy, patients who are at high risk for thromboembolism are still recommended to be bridged. The PERIOP 2 study provides guidance on how to safely bridge patients in clinical situations where the benefits outweigh the risks of bridge therapy (387,388).

### ***5.6.3 Post-Procedure Resumption of Antiplatelet and Anticoagulant Therapy***

The evidence and recommendations have been

highly variable in the available literature. As shown in Table 21 and Figs. 11-14, these are also variable for minor surgery and major surgery, ranging from 24 hours to 72 hours for warfarin, 24-48 hours for all the remaining drugs. For warfarin, despite recommendations to avoid the bridging, low molecular heparin may be started after the surgery after 24 hours for low bleed risk and 48-72 hours for high bleed risk procedures.

For interventional techniques, based on the available literature from various groups, similar patterns are utilized using minor surgery as low-risk and major surgery as moderate or intermediate and high-risk.

## **6.0 GUIDELINES FOR MANAGING ANTICOAGULANT AND ANTIPLATELET THERAPY DURING INTERVENTIONAL TECHNIQUES**

ASIPP guidelines with recommendations and statements are developed based on a comprehensive review of the literature of thromboembolic risk, bleeding risk, anatomical factors, procedural factors and medical or physiologic status. Further, we also utilized review of previous guidelines for interventional pain management, as well as for general surgery, endoscopy and ophthalmic surgery as developed by various organizations.

Table 22 shows guidelines for antiplatelet and anticoagulation medication management for interventional procedures. This table also shows comparisons of ASIPP guidelines and ASRA published guidelines. These recommendations differ from our previously published guidelines, as well as from ASRA guidelines based on the present analysis of the evidence.

General recommendations based on ASRA guidelines (14) are to discontinue the drugs for 5 half-lives for drugs following first-order metabolism; however, the exception to the 5 half-lives recommendation should occur in individuals with hepatic dysfunction, and renal

dysfunction including nephrotic syndrome. Cessation of all drugs for 5 half-lives may not be sound for interventional techniques in the perioperative period. Pharmacologically, 5 half-lives are required to eliminate a drug completely. As an example, in the management of DOACs, clinical practice guidelines from CHEST, published in 2022 (10), recommend cessation for one day in patients with low- and moderate-risk, and 2 days for high-risk procedures. However, these guidelines vary if there is renal dysfunction with creatinine clearance of less than 50 mL per minute. Thus, based on ASRA guidelines, Dabigatran is recommended to stop for 4 days, whereas Rivaroxaban, Apixaban, and Edoxaban have been recommended to stop for 3 days. This may put patients at increased thromboembolic risk. In addition, ASRA Guidelines (14) described 3 case reports of spinal hematoma related to DOAC, with all of them being subarachnoid or intrathecal injections. Thus, for the present guidelines, the panel has decided to utilize extensively studied guidelines for chest physicians (10), and other available literature including other available guidelines.

Table 23 shows a procedural checklist for managing anticoagulant and antiplatelet therapy during interventional techniques.

Table 22. Guidelines for antithrombotic medication management and interventional techniques (risk stratification described in Table 19).

Medication	Time to Wait After Last Dose of Medication Before Interventional Techniques Are Performed				Timing of Therapy Restoration or Restarting	
	Low Risk Procedures**		Moderate Or Intermediate Risk Procedures**		High-Risk Procedures**	
	ASIPP	ASRA	ASIPP	ASRA	ASIPP	ASRA
<ul style="list-style-type: none"> <li>• Trigger point and intramuscular injections</li> <li>• Peripheral nerve blocks</li> <li>• Sacroiliac joint injections</li> <li>• Thoracic and lumbar facet medial branch nerve block and radiofrequency ablation</li> <li>• Peripheral joints and musculoskeletal injections</li> <li>• Pocket revision/intraarticular pump replacement</li> <li>• Peripheral nerve stimulation trial and implantation of extremities</li> <li>• Lumbar transforaminal epidural injections at L3, L4, L5, and S1</li> <li>• Ganglion impar blocks</li> <li>• Sacroiliac joint nerve radiofrequency</li> <li>• Trigeminal branch nerve blocks (mandibular, maxillary, and other branches)</li> </ul>	<ul style="list-style-type: none"> <li>• Trigger point injections</li> <li>• Peripheral nerve blocks</li> <li>• Sacroiliac joint injections</li> <li>• Thoracic and lumbar facet medial branch nerve block and radiofrequency ablation</li> <li>• Peripheral joints and musculoskeletal injections</li> <li>• Pocket revision/intraarticular pump replacement</li> <li>• Peripheral nerve stimulation trial and implant</li> </ul>	<ul style="list-style-type: none"> <li>• Caudal epidural injections*</li> <li>• Caudal epidural adhesiolysis*</li> <li>• Lumbar interlaminar epidural at L5, S1</li> <li>• Cervical, thoracic, and lumbar transforaminal at L1 and L2</li> <li>• Peripheral nerve stimulation trial and implantation of lumbar medial branches</li> </ul>	<ul style="list-style-type: none"> <li>• All transforaminal epidural injections</li> <li>• All intradiscal procedure</li> <li>• Sympathetic blocks</li> <li>• All interlaminar epidural injections</li> <li>• Cervical facet medial branch nerve block and radiofrequency ablation</li> <li>• Trigeminal and sphenopalatine ganglia blocks</li> </ul>	<ul style="list-style-type: none"> <li>• Cervical, thoracic, and lumbar (above L5) interlaminar epidurals</li> <li>• Peripheral nerve stimulation trial and implantation of thoracic and cervical medial branches.</li> <li>• Trigeminal ganglion, ophthalmic division, and sphenopalatine ganglion blocks</li> <li>• Discography and intradiscal procedures</li> <li>• Dorsal column and dorsal root ganglion stimulator trial and implantation</li> <li>• Intrathecal catheter and pump implant</li> <li>• Vertebral augmentation</li> <li>• Percutaneous and endoscopic disc decompression procedures</li> <li>• Minimally invasive lumbar decompression (MILD)</li> <li>• Trigeminal and cranial nerve blocks and stimulation</li> <li>• Sympathetic blocks (stellate ganglion, thoracic sympathetic, splanchnic, celiac plexus, lumbar sympathetic, hypogastric plexus)</li> <li>• Percutaneous adhesiolysis with interlaminar or transforaminal approach (cervical, thoracic, and lumbar)</li> <li>• Intervertebral spinous prosthesis including lateral fusion</li> <li>• SI joint fusion</li> <li>• Intracept procedure</li> </ul>	<ul style="list-style-type: none"> <li>• Spinal cord stimulation trial and implant</li> <li>• Intrathecal catheter and pump implant</li> <li>• Vertebral augmentation (vertebroplasty and kyphoplasty)</li> <li>• Percutaneous decompression laminotomy</li> <li>• Epiduroscopy and epidural decompression</li> <li>• Dorsal root ganglion stimulation</li> </ul>	



Table 22 cont. Guidelines for antithrombotic medication management and interventional techniques (risk stratification described in Table 19).

Medication	Time to Wait After Last Dose of Medication Before Interventional Techniques Are Performed						Timing of Therapy Restoration or Restarting	
	Low Risk Procedures**		Moderate Or Intermediate Risk Procedures**		High-Risk Procedures**		ASIPP	ASRA
	ASIPP	ASRA	ASIPP	ASRA	ASIPP	ASRA	ASIPP	ASRA
NSAIDS (COX 1) (COX 2)	May continue or stop 1-10 days due to lack of protective effect	Stop 1-10 days due to lack of protective effect	May continue or stop 1-10 days due to lack of protective effect	Stop 1-10 days due to lack of protective effect	May continue or stop 1-10 days due to lack of protective effect	Stop 1-10 days due to lack of protective effect	24 hours	24 hours
THC/CBD	May continue or stop 1-10 days	N/A	May continue or stop 1-10 days	N/A	Stop for 5 days	N/A	24 hours	N/A
Garlic	Continue or may stop for 3 days	Stop for 4 days	Continue or may stop for 3 days	Stop for 4 days	Stop for 6 days	Stop for 6 days	24 hours	24 hours
Vitamin E	Continue or may stop for 3 days	Stop for 4 days	Continue or may stop for 3 days	Stop for 4 days	Stop for 6 days	Stop for 6 days	24 hours	24 hours
Fish Oil	Continue or may stop for 3 days	Stop for 4 days	Continue or may stop for 3 days	Stop for 4 days	Stop for 6 days	Stop for 6 days	24 hours	24 hours
Aspirin								
Low-Dose Aspirin	Continue or may stop for 3 days	Stop for 4 days	Continue or may stop for 3 days	Stop for 4 days	Stop for 6 days	Stop for 6 days	24 hours	24 hours
High Dose Aspirin	Continue or may stop for 3 days	Stop for 4 days	Continue or may stop for 3 days	Stop for 4 days	Stop for 6 days	Stop for 6 days	24 hours	24 hours
Antiplatelet Agents (Phosphodiesterase Inhibitors)								
Dipyridamole (Persantine)	May continue	May continue	May continue	May continue	May continue or stop for 2 days	Stop for 2 days	12 hours	12 hours
Clostrazol (Pletal)	May continue	May continue	May continue	May continue	May continue or stop for 2 days	Stop for 2 days	12 hours	12 hours
Aggrenox (dipyridamole plus aspirin)	May continue	Stop for 4 days	May continue	Stop for 3 days	Stop for 6 days	Stop for 6 days	24 hours	24 hours
Platelet Aggregation Inhibitors								
Clopidogrel (Plavix)	May continue	May continue	May continue or stop for 5 days	Stop for 7 days	Stop for 6 days	Stop for 7 days	12 hours	12 hours
Prasugrel (Effient)	May continue	May continue	May continue or stop for 5 days	Stop for 7-10 days	Stop for 6 days	Stop for 7-10 days	24 hours	24 hours
Ticagrelor (Brilinta)	May continue	Continue or stop 5 days	May continue or stop for 3 days	Stop 5 days	Stop for 5 days	Stop for 5 days	24 hours	24 hours
Vitamin K Antagonists								
Warfarin	May continue or stop for 1 to 2 days INR ≤ 3.0	INR < 3.0	May continue or stop for 2-3 days INR ≤ 2.0	Stop for 5 days INR normalize	Stop for 3-5 days INR ≤ 1.5	Stop for 5 days INR normalize	12-24 hours	24 hours

Table 22 cont. Guidelines for antithrombotic medication management and interventional techniques (risk stratification described in Table 19).

Medication	Time to Wait After Last Dose of Medication Before Interventional Techniques Are Performed						Timing of Therapy Restoration or Restarting	
	Low Risk Procedures**		Moderate Or Intermediate Risk Procedures**		High-Risk Procedures**		ASIPP	ASRA
	ASIPP	ASRA	ASIPP	ASRA	ASIPP	ASRA	ASIPP	ASRA
<b>Direct Oral Anticoagulants (DOACs)</b>								
Dabigatran (Pradaxa)	May continue or stop for 1 day	May continue or stop for 4 days	Stop for 2 days	Stop for 4 days	Stop for 2 days	Stop for 4 days	24 hours	24 hours
Dabigatran (Pradaxa) (CrCl ≤ 50 ml/min)	May continue or stop for 1 day	May continue or stop for 5-6 days	Stop for 3-4 days	Stop for 5-6 days	Stop for 3-4 days	Stop for 5-6 days	24 hours	24 hours
Apixaban (Eliquis)	May continue or stop for 1 day	May continue or stop for 3 days	Stop for 1 day	Stop for 3 days	Stop for 2 days	Stop for 3 days	24 hours	24 hours
Rivaroxaban (Xarelto)	May continue or stop for 1 day	May continue or stop for 3 days	Stop for 1 day	Stop for 3 days	Stop for 2 days	Stop for 3 days	24 hours	24 hours
Edoxaban (Savaysa, Lixiana)	May continue or stop for 1 day	May continue or stop for 3 days	Stop for 1 day	Stop 3 days	Stop for 2 days	Stop 3 days	24 hours	24 hours
<b>Heparins</b>								
Heparin (treatment) - IV	Discontinue for 4 hours	Discontinue for 6 hours	Discontinue for 4 hours	Discontinue for 6 hours	Discontinue for 4 hours	Discontinue for 6 hours	24 hours	24 hours
Heparin (treatment) - SC	Discontinue for 6 hours	Discontinue for 6 hours	Discontinue for 6 hours	Discontinue for 6 hours	Discontinue for 24 hours	Discontinue for 24 hours	24 hours	24 hours
Low Molecular Weight Heparin	Discontinue for 24 hours	Discontinue for 24 hours	Discontinue for 24 hours	Discontinue for 24 hours	Discontinue for 24 hours	Discontinue for 24 hours	24 hours	24 hours

\*Change from 2019 guidelines

\*\*For full list of procedures please see Table 20. These differ from ASIPP classification to ASRA classification.

Adapted and modified from: Manchikanti L, et al. Epidural interventions in the management of chronic spinal pain: American Society of Interventional Pain Physicians (ASIPP) comprehensive evidence-based guidelines. *Pain Physician* 2021; 24:S27-S208 (52) and Kaye AD, et al. Responsible, safe, and effective use of antithrombotics and anticoagulants in patients undergoing interventional techniques: American Society of Interventional Pain Physicians (ASIPP) guidelines. *Pain Physician* 2019; 22:S75-S128 (1) and Narouze S, et al. Interventional spine and pain procedures in patients on antiplatelet and anticoagulant medications (Second Edition): Guidelines from the American Society of Regional Anesthesia and Pain Medicine, the European Society of Regional Anaesthesia and Pain Therapy, the American Academy of Pain Medicine, the International Neuromodulation Society, the North American Neuromodulation Society, and the World Institute of Pain. *Reg Anesth Pain Med* 2018; 43:225-262 (14).

Table 23. *Procedural checklist for managing anticoagulant and antiplatelet therapy during interventional techniques.*

<b>PROCEDURE:</b>
<p>1.0 Patient evaluation and Identification of Risk Factors</p> <ul style="list-style-type: none"> <li><input type="checkbox"/> 1.1 Age</li> <li><input type="checkbox"/> 1.2 Diabetes</li> <li><input type="checkbox"/> 1.3 Bleeding disorders</li> <li><input type="checkbox"/> 1.4 Hypertension</li> <li><input type="checkbox"/> 1.5 Obesity</li> <li><input type="checkbox"/> 1.6 Low body weight</li> <li><input type="checkbox"/> 1.7 Renal disease</li> <li><input type="checkbox"/> 1.8 Low creatinine clearance</li> </ul>
<p>2.0 Identification of Anticoagulant or Antithrombotic Medication</p> <ul style="list-style-type: none"> <li><input type="checkbox"/> 2.1 Aspirin Use: <ul style="list-style-type: none"> <li>• Primary Prophylaxis: Absence of established cardiovascular disease or risk factor</li> <li>• Secondary Prophylaxis: Presence of cardiovascular or cerebrovascular disease</li> </ul> </li> <li><input type="checkbox"/> 2.2 Antiplatelets <ul style="list-style-type: none"> <li>• Clopidogrel (Plavix)</li> <li>• Prasugrel (Effient)</li> <li>• Ticagrelor (Brilinta)</li> </ul> </li> <li><input type="checkbox"/> 2.3 Direct oral anticoagulants (DOACs) <ul style="list-style-type: none"> <li>• Dabigatran (Pradaxa)</li> <li>• Apixaban (Eliquis)</li> <li>• Rivaroxaban (Xarelto)</li> <li>• Edoxaban (Savaysa, Lixiana)</li> </ul> </li> <li><input type="checkbox"/> 2.4 Warfarin (Coumadin)</li> <li><input type="checkbox"/> 2.5 Identification of over-the-counter drugs influencing thrombolysis: <ul style="list-style-type: none"> <li>• Garlic</li> <li>• Vitamin E</li> </ul> </li> <li><input type="checkbox"/> 2.6 Fish Oil <ul style="list-style-type: none"> <li>• Primary Prophylaxis: Absence of established cardiovascular disease or risk factor</li> <li>• Secondary Prophylaxis: Presence of cardiovascular or cerebrovascular disease</li> </ul> </li> <li><input type="checkbox"/> 2.7 SSRIs <ul style="list-style-type: none"> <li>• Citalopram (Celexa)</li> <li>• Fluoxetine (Prozac)</li> <li>• Escitalopram (Lexapro)</li> <li>• Paroxetine (Paxil)</li> <li>• Sertraline (Zoloft)</li> </ul> </li> <li><input type="checkbox"/> 2.8 NSAIDs</li> </ul>
<ul style="list-style-type: none"> <li><input type="checkbox"/> 3.0 Risk Stratification and Recommendations <ul style="list-style-type: none"> <li>• Low risk</li> <li>• Moderate or intermediate risk</li> <li>• High risk</li> </ul> </li> </ul>
<input type="checkbox"/> 4.0 Informed Decision Making
<input type="checkbox"/> 5.0 Restarting of Drugs
<input type="checkbox"/> 6.0 Postoperative Monitoring

## 7.0 RECOMMENDATIONS AND STATEMENTS

1. The risk of thromboembolic events and associated morbidity and mortality is higher than that of epidural hematoma formation and associated morbidity and mortality with critical management, with the interruption of antiplatelet and anticoagulant therapy preceding interventional techniques, though both risks are significant.  
**Evidence Level: Moderate; Strength of Recommendation: Moderate**
  2. Risk stratification categorized multiple interventional techniques into low-risk, moderate or intermediate risk, and high-risk.  
**Evidence Level: Low to moderate; Strength of Recommendation: Moderate to strong**
  3. Risk stratification of patients undergoing interventional techniques on antiplatelet or anticoagulant therapy based on anatomical risk factors, procedural risk factors, bleeding risk factors, anticoagulant risk factors, and medical or physiological status provide a physiologic and clinically appropriate basis in developing the developing the guidelines.  
**Evidence Level: Moderate; Strength of Recommendation: Moderate**
  4. Risk factors with severe degenerative arthritis with or without spinal stenosis, ankylosing spondylitis, osteoporosis, older age, frailty, previous stroke, intracranial bleed, hypertension, diabetes, thrombocytopenia, chronic renal failure, chronic NSAID or steroid therapy, multiple attempts, epidural fibrosis, and previous surgery may increase bleeding observed during the procedure and risk of epidural hematoma.  
**Evidence Level: Moderate; Strength of Recommendation: Moderate**
  5. Risk stratification should be upgraded to low to moderate or intermediate and moderate or intermediate to high based on other risk factors.  
**Evidence Level: Low; Strength of Recommendation: Low to Moderate**
  6. All procedures categorized as high-risk include:
    - a. Cervical, thoracic, and lumbar (above L5) interlaminar epidurals
    - b. Peripheral nerve stimulation trial and implantation of throacic and cervical medial branches.
    - c. Trigeminal ganglion, ophthalmic division, and sphenopalatine ganglion blocks
    - d. Discography and intradiscal procedures (lumbosacral, cervical, and thoracic)
    - e. Dorsal column and dorsal root ganglion stimulator trial and implantation
    - f. Intrathecal catheter and pump implant
    - g. Vertebral augmentation (sacral, lumbar, thoracic, and cervical)
    - h. Percutaneous and endoscopic disc decompression procedures
    - i. Minimally invasive lumbar decompression (MILD)
    - j. Trigeminal and cranial nerve blocks and stimulation
    - k. Sympathetic blocks (stellate ganglion, thoracic sympathetic, splanchnic, celiac plexus, lumbar sympathetic, hypogastric plexus)
    - l. Percutaneous adhesiolysis with interlaminar or transforaminal approach (cervical, thoracic, and lumbar)
    - m. Intervertebral spinous prosthesis including lateral fusion
    - n. Sacroiliac joint fusion
    - o. Intracept procedure
- Evidence Level: Moderate; Strength of Recommendation: Moderate**
7. Procedures categorized as moderate or intermediate-risk include:
    - a. Caudal epidural injections \*
    - b. Caudal epidural adhesiolysis \*
    - c. Lumbar interlaminar epidural injection at L5, S1
    - d. Cervical, thoracic, and lumbar transforaminal at L1 and L2
    - e. Peripheral nerve stimulation trial and implantation of lumbar medial branches**Evidence Level: Moderate; Strength of Recommendation: Moderate**
  8. Procedures categorized as low-risk include:
    - a. Trigger point and intramuscular injections (including piriformis injection)
    - b. Peripheral nerve blocks including mandibular and maxillary nerve blocks
    - c. Sacroiliac joint and ligament injections and nerve blocks
    - d. Facet joint interventions (intra-articular injections, medial branch and L5 dorsal ramus nerve blocks and radiofrequency neurotomy)
    - e. Intraarticular injections of extremity joints
    - f. Pocket revision and implantable pulse generator/intrathecal pump replacement
    - g. Peripheral nerve stimulation trial and implantation of extremities
    - h. Lumbar transforaminal epidural injections at L3, L4, L5, and S1

\* Change from 2019 guidelines

- i. Ganglion impar blocks
- j. Sacroiliac joint nerve radiofrequency
- k. Trigeminal branch nerve blocks (mandibular, maxillary, and other branches)

**Evidence Level: Moderate; Strength of Recommendation: Moderate**

9. Discontinuation of aspirin (81 or 325 mg) for 6 days for high-risk procedures. The clinician may choose to continue aspirin (81 or 325 mg) without interruption for low and moderate or intermediate risk procedures or discontinue (81 or 325 mg) for 3 days. Similarly, additional factors may increase the risk and necessitate change in the guidance for low and moderate or intermediate risk patients.

**Evidence Level: Moderate; Strength of Recommendation: Moderate**

10. Discontinuation of most NSAIDs, excluding aspirin, for 1 to 2 days and some 4 to 10 days may be considered of moderate and high-risk procedures.

**Evidence Level: Low; Strength of Recommendation: Weak**

11. In patients on anticoagulant therapy with Warfarin, low risk procedures may be performed with INR of  $\leq 3.0$  with 1 to 2 days of cessation if warranted, for moderate or intermediate risk procedures an INR of  $\leq 2.0$  is recommended with 2 to 3 days of cessation of Warfarin therapy if warranted, and for high-risk procedures an INR of  $< 1.5$  is recommended with cessation of Warfarin therapy for 3 to 5 days if warranted.

**Evidence Level: Moderate; Strength of Recommendation: Moderate**

12. Anticoagulant therapy with direct acting anticoagulants dabigatran (Pradaxa), apixaban (Eliquis), rivaroxaban (Xarelto), and Edoxaban (Savaysa, Lixiana) is discontinued for 2 days for high-risk procedures and one day for moderate or intermediate risk procedures. Discontinuation is adjusted to 2 days and 3-4 days for dabigatran (Pradaxa) with creatinine clearance below 50 mL/minute. For low-risk procedures, direct acting oral coagulants may be continued. Based on clinical condition and importance, a shared decision may be made to continue for moderate or intermediate risk procedures with normal renal function.

**Evidence Level: Moderate; Strength of Recommendation: Moderate**

13. Antiplatelet agents such as dipyridamole, cilostazol, and Aggrenox (dipyridamole plus aspirin) may be continued for low and moderate or intermediate risk procedures. For high-risk procedures, dipyridamole and cilostazol may be continued or stopped for 2

days, with Aggrenox (dipyridamole plus aspirin) to be stopped for 6 days.

**Evidence Level: Low; Strength of Recommendation: Moderate**

14. Antiplatelet therapy with clopidogrel (Plavix) and prasugrel (Effient) are discontinued for 6 days for high-risk procedures and 5 days for intermediate or moderate risk procedures. They are continued in low-risk procedures. Ticagrelor (Brilinta) is discontinued for 5 days in high risk. Ticlopidine (Ticlid) (discontinued in the U.S.) is discontinued for 7 days for high and moderate or intermediate risk procedures and 3 days in moderate risk procedures and may be continued in low-risk procedures.

**Evidence Level: Moderate; Strength of Recommendation: Moderate**

15. Timing of therapy of restoration or restarting is recommended during 12 to 24-hour period for moderate or intermediate risk procedures, and low risk procedures if the decision was made to hold based on risk factors, and 24-48 hours for major risk procedures, based on postoperative bleeding status. If thromboembolic risk is high, antithrombotic therapy may be resumed 12 hours after the interventional procedure is performed, with appropriate assessment and monitoring for clinically significant bleeding.

**Evidence Level: Low; Strength of Recommendation: Moderate**

16. Diagnosis of epidural hematoma is clinically based on unexpected pain at the site of the injection with rapid neurological deterioration and MRI confirmation. Neurosurgical consult is necessary to avoid neurological sequelae.

**Evidence Level: Moderate; Strength of Recommendation: Moderate**

17. If thromboembolic risk is high, low molecular weight heparin bridge therapy can be instituted during cessation of the anticoagulant, and the low molecular weight heparin can be discontinued 24 hours before the pain procedure.

**Evidence Level: Low; Strength of Recommendation: Weak**

18. Shared decision making between the patient, the pain specialist, and the treating physicians if cessation is contemplated is recommended for consideration of all the appropriate risks associated with continuation or discontinuation of antiplatelet or anticoagulant therapy.

**Evidence Level: Moderate; Strength of Recommendation: High**

## **8.0 CONCLUSION**

Managing chronic pain in patients undergoing anticoagulant and antiplatelet therapy is a complex and increasingly common challenge that requires a multidisciplinary approach. The interplay between the necessity of anticoagulant therapy to prevent thromboembolic events and the need for interventional pain management procedures underscores the importance of carefully balancing these treatments. Evidence indicates that withholding anticoagulant or antiplatelet therapy carries significant risks, including cardiovascular and cerebrovascular events, which are further exacerbated by chronic stress. Therefore,

it is crucial to develop strategies that minimize interruptions in anticoagulant therapy while ensuring the safety and efficacy of pain management interventions. The literature highlights the need for tailored guidelines that consider the specific risks associated with different types of procedures and patient conditions. By adhering to these guidelines and leveraging a comprehensive understanding of both anticoagulant therapy and interventional techniques, interventional pain physicians can better navigate the complexities of treating chronic pain in this vulnerable patient population, ultimately improving outcomes and reducing the incidence of adverse events.

### Acknowledgments

The authors wish to thank Bert Fellows, MA, Director Emeritus of Psychological Services at Pain Management Centers of America, for manuscript review, and Tonie M. Hatton and Diane E. Neihoff, transcriptionists, for their assistance in preparation of this manuscript. We would like to thank the editorial board of Pain Physician for review and criticism in improving the manuscript.

### AUTHOR AFFILIATIONS

---

#### Adam M. Kaye, PharmD, FASCP, FCPHA

Dr. A.M. Kaye is Clinical Professor of Pharmacy, Department of Pharmacy Practice, Thomas J. Long School of Pharmacy, University of the Pacific, Stockton, CA, USA  
akaye@pacific.edu

#### Alaa Abd-Elseyed, MD

Dr. Abd-Elseyed is Medical Director, UW Pain Services, Division Chief Chronic Pain Medicine, and Associate Professor of Anesthesiology, University of Wisconsin, Madison, WI, USA  
alaawny@hotmail.com; abdelseyed@wisc.edu

#### Alan D. Kaye, MD, PhD

Dr. Kaye is Professor, Pain Fellowship Director, Vice Chair of Research, Department of Anesthesiology; Professor, Department of Pharmacology, Toxicology, and Neurosciences, Louisiana State University Health Sciences Center at Shreveport, Shreveport, LA; Professor, Department of Anesthesiology, Tulane School of Medicine, and Professor, Department of Anesthesiology and Pharmacology, LSU School of Medicine, New Orleans, LA, USA  
akaye@lsuhsc.edu

#### Alexander Bautista, MD

Dr. Bautista is Professor, University of Louisville, Department of Anesthesiology and Perioperative Medicine, Louisville, KY, USA  
alexander.bautista@louisville.edu

#### Amol Soin, MD

Dr. Soin is Medical Director, Ohio Pain Clinic, and Clinical Assistant Professor of Surgery at Wright State University, Dayton, OH, USA  
drsoin@gmail.com; ohioinclinic@gmail.com

#### Anilkumar Vinayakan, MD

Dr. Vinayakan is Medical Director, Norton Pain Management Associates, and Clinical Assistant Professor,

### Disclosures

Funding: There was no external funding in the preparation of the guidelines. Internal funding provided by the American Society of Interventional Pain Physicians (ASIPP) was limited to preparation of the publication.

Department of Anesthesiology, University of Louisville, Louisville, KY, USA  
anilvinaya@hotmail.com

#### Anjum Bux, MD

Dr. Bux is CEO, Bux Pain Management, Lexington, KY, USA  
anjumbux@aol.com

#### Annu Navani, MD

Dr. Navani is Chief Medical Officer, Boomerang Health Care, Walnut Creek, CA, Medical Director, Le Reve Regenerative Wellness, San Jose, CA, USA  
annu@navani.net; anavani@boomeranghc.com

#### Byron J. Schneider, MD

Dr. Schneider is Associate Professor, Department of Physical Medicine & Rehabilitation, Vanderbilt University Medical Center, Nashville, TN, USA  
byron.j.schneider@vumc.org

#### Chelsi J. Flanagan, DO, MPH

Dr. Flanagan, Department of Anesthesiology, Ochsner Clinic Foundation, New Orleans, LA, USA  
chelsiflanagan@gmail.com

#### Christopher G. Gharibo, MD

Dr. Gharibo is the Medical Director of Pain Medicine within Department of Anesthesiology, Peri-Operative Care & Pain Medicine, NYU Langone Health; Professor, Department of Anesthesiology, Perioperative Care, and Pain Medicine, and Professor, Department of Orthopedic Surgery at NYU Grossman School of Medicine, New York, NY, USA  
cgharibo@usa.net

#### Devi Nampiaparampil, MD

Dr. Nampiaparampil is Medical Director, Metropolis Pain Medicine, and Clinical Associate Professor, Dept. of Rehabilitation Medicine, NYU Grossman School of Medicine, New York, NY, USA  
devichechi@gmail.com

**Emiliya Rakhmimova, BA**

Ms. Rakhmimova is a medical student at Renaissance School of Medicine at Stony Brook University, Stony Brook, NY, USA  
Emiliya.Rakhmimova@stonybrookmedicine.edu

**Gerard Limerick, MD, PhD**

Dr. Limerick, Assistant Professor, Physical Medicine & Rehabilitation, Johns Hopkins University School of Medicine, Baltimore, MD, USA  
glimeri1@jhmi.edu

**Jay Karri, MD**

Dr. Karri, Departments of Orthopedic Surgery and Anesthesiology, University of Maryland School of Medicine, Baltimore, MD, USA  
jaykarri@gmail.com

**Joshua A. Hirsch, MD**

Dr. Hirsch is Vice Chair of Procedural Services, Director Interventional Neuroradiology, Chief Interventional Spine, Associate Department Chair, Massachusetts General Hospital/Harvard Medical School, Boston, MA, USA  
jahirsch@mgh.harvard.edu

**Kenneth D. Candido, MD**

Dr. Candido is Director of Pain Medicine, Thorek Memorial Hospital, and Clinical Professor of Anesthesia & Surgery, University of Illinois College of Medicine-Chicago, Chicago, IL, USA  
kdcandido1@gmail.com; kdcandido@yahoo.com; kdcandido2@gmail.com

**Kunj G. Patel, MD**

Dr. Patel is Founder, Medical Director, Criss Clinics, San Francisco & Daly City, CA, President, Cofounder, Chief Technical Officer, SafeBeat Rx, Inc., San Francisco, CA, USA  
kunj.patel@gmail.com; dr.patelkunj@gmail.com

**Laxmaiah Manchikanti, MD**

Dr. Manchikanti is Director, Pain Management Centers of America, Paducah, KY, Clinical Professor, Anesthesiology and Perioperative Medicine, University of Louisville, Louisville, KY, and Professor of Anesthesiology-Research, Department of Anesthesiology, School of Medicine, LSU Health Sciences Center, Shreveport, LA, USA  
drIm@thepainmd.com

**Mahendra R. Sanapati, MD**

Dr. Sanapati is Director, Pain Management Centers of America, and Voluntary Faculty Member, Indiana University School of Medicine, Evansville, IN, and Assistant Professor of Anesthesiology, University of Louisville, Louisville, KY, USA  
msanapati@gmail.com

**Mayank Gupta, MD**

Dr. Gupta is President & CEO of Kansas Pain Management and Neuroscience Research Center, LLC, Overland Park, KS, and Adjunct Clinical Assistant Professor of Anesthesiology, Kansas City University of Medicine and Biosciences, Kansas City, MO, USA  
mayankempire@yahoo.com; mayank.g@kansaspainmanagement.com

**Megan K. Applewhite, MD**

Dr. Applewhite, Associate Professor of Surgery and Associate Director, MacLean Center for Clinical Medical Ethics, University of Chicago, Chicago, IL, USA  
Megan.Applewhite@bsd.uchicago.edu

**Nebojsa Nick Knezevic, MD, PhD**

Dr. Knezevic is Vice Chair for Research and Education, Department of Anesthesiology, Advocate Illinois Masonic Medical Center, Chicago, IL, and Clinical Professor, Department of Anesthesiology and Clinical Professor, Department of Surgery, College of Medicine, University of Illinois, Chicago, IL, USA  
nick.knezevic@gmail.com

**Paul J. Christo, MD, MBA**

Dr. Christo is an Associate Professor and Interim Chief, Division of Pain Medicine, Department of Anesthesiology and Critical Care Medicine, The Johns Hopkins University School of Medicine, Baltimore, MD, USA  
pchristo@jhmi.edu

**Sairam Atluri, MD**

Dr. Atluri is Medical Director, Tri-State Spine Care Institute, Cincinnati, OH, USA  
saiatluri@gmail.com

**Sanjay Bakshi, MD**

Dr. Bakshi is CEO, PRC Associates, , MBM Management and Specialty Surgery Partners, Daytona Beach, FL, USA  
drbakshi58@gmail.com



**Sanjeeva Gupta, MD**

Dr. Gupta is a Consultant in Pain Medicine, Department of Anesthesia, Pain Medicine, ICU and Sleep Medicine, Bradford Teaching Hospitals NHS Foundation Trust, Bradford, West Yorkshire, UK  
sgupta6502@aol.com

**Sara E. Nashi, MD**

Dr. Nashi, Director of the Pain Division, TriHealth Physician Practices, Cincinnati, OH, USA  
saranashi4110@gmail.com

**Scott Stayner, MD, PhD**

Dr. Stayner is Medical Director, Nura Precision Pain Management, Minneapolis, MN, USA  
sstayner@nura-clinics.com

**Sierra Willeford, DO**

Dr. Willeford is PM&R Resident Physician, Johns Hopkins Hospital, Baltimore, MD, USA  
sierrawilleford@gmail.com

**Standiford Helm II, MD**

Dr. Helm is Clinical Professor, Division of Pain Medicine, Department of Anesthesiology and Peri-Operative Care, University of California, Irvine, UCI Health Center for Pain and Wellness, Gottschalk Medical Plaza, Irvine, CA, USA.  
drhelm@thehelmcenter.com

**Vinayak Belamkar, MD**

Dr. Belamkar is an interventional pain physician at Witham Health Services, Frankfort, IN, USA  
belamkar@gmail.com

**Vivekanand A. Manocha, MD**

Dr. Manocha is Assistant Professor, Department of Surgery, Wright State University School of Medicine, Dayton, OH, and Interventional Pain Physician, Beacon Orthopedics & Sports Medicine, Cincinnati, OH, USA  
rxspine@painmanagementohio.com

**Vidyasagar Pampati, MSc**

Vidyasagar Pampati is a Statistician, Pain Management Centers of America, Paducah, KY, USA  
sagar@thepainmd.com

**CONFLICT OF INTEREST**

Dr. Abd-Elseyed received research grant from Medtronic and consulting fees from Avanos, Medtronic, Curonix, and Averitas.

Dr. Candido has received payment for being an expert witness for Workman's Compensation case reviews in Illinois.

Dr. Gupta receives educational grants from Abbott to organize meetings.

Dr. Helm receives payment for expert testimonies and support for attending meetings and/or travel. He is the principal investigator for Curonix Freedom 1 clinical trial.

Dr. Hirsch receives grants or contracts from Neiman Health Policy Institute, is a consultant for Medtronic, Relievant, and Sanofi, and is the Chair CSMB of neurovascular studies for Balt: Rapid Medical.

Dr. Nampiaparampil receives honoraria for lectures and speakers bureau for AbbVie.

Dr. Schneider receives consulting fees from Carelton Health and State Farm, payment for expert testimony from various medical legal law firms, support for attending North American Spine Society and International Pain and Spine Intervention Society (IP SIS) meetings and is on the Board of Directors of IP SIS.

Dr. Soin has patents planned, issued or pending for Soin Neuroscience and is a clinical advisor for Neuroff and Neuros Medical.

## REFERENCES

- Kaye AD, Manchikanti L, Novitch MB, et al. Responsible, safe, and effective use of antithrombotics and anticoagulants in patients undergoing interventional techniques: American Society of Interventional Pain Physicians (ASIPP) guidelines. *Pain Physician* 2019; 22:S75-S128.
- Manchikanti L, Falco FJE, Benyamin RM, et al. Assessment of bleeding risk of interventional techniques: A best evidence synthesis of practice patterns and perioperative management of anticoagulant and antithrombotic therapy. *Pain Physician* 2013; 16:SE261-SE318.
- Manchikanti L, Pampati V, Sanapati MR, et al. COVID-19 pandemic reduced utilization of interventional techniques 18.7% in managing chronic pain in the Medicare population in 2020: Analysis of utilization data from 2000 to 2020. *Pain Physician* 2022; 25:223-238.
- Manchikanti L, Pampati V, Knezevic NN, et al. The influence of COVID-19 on utilization of epidural procedures in managing chronic spinal pain in the Medicare population. *Spine (Phila Pa 1976)* 2023; 48:950-961.
- Manchikanti L, Kaye AD, Latchaw RE, et al. Impact of COVID-19 pandemic on utilization patterns of facet joint interventions in managing spinal pain in Medicare population. *Pain Ther* 2023; 12:505-527.
- Manchikanti L, Simopoulos TT, Pampati V, et al. Impact of COVID-19 pandemic and updated utilization patterns of sacroiliac joint injections from 2000 to 2020 in the fee-for-service (FFS) Medicare population. *Pain Physician* 2022; 25:239-250.
- Manchikanti L, Senapathi SHV, Milburn JM, et al. Utilization and expenditures of vertebral augmentation continue to decline: An analysis in fee-for-service (FFS) Recipients from 2009 to 2018. *Pain Physician* 2021; 24:401-415.
- Manchikanti L, Pampati V, Vangala BP, et al. Spinal cord stimulation trends of utilization and expenditures in fee-for-service (FFS) Medicare population from 2009 to 2018. *Pain Physician* 2021; 24:293-308.
- Manchikanti L, Kosanovic R, Pampati V, Kaye AD. Declining utilization patterns of percutaneous adhesiolysis procedures in the fee-for-service (FFS) Medicare population. *Pain Physician* 2021; 24:17-29.
- Douketis JD, Spyropoulos AC, Murad MH, et al. Perioperative management of antithrombotic therapy: An American College of Chest Physicians Clinical Practice Guideline. *Chest* 2022; 162:e207-e243.
- Douketis JD, Lip GYH. Perioperative management of patients receiving anticoagulants. *UpToDate* 2023. Accessed 12/6/2023. <https://www.uptodate.com/contents/perioperative-management-of-patients-receiving-anticoagulants/print>
- Bainey KR, Marquis-Gravel G, Belley-Côté E, et al. Canadian Cardiovascular Society/Canadian Association of Interventional Cardiology 2023 Focused Update of the Guidelines for the Use of Antiplatelet Therapy. *Can J Cardiol* 2024; 40:160-181.
- Valgimigli M, Bueno H, Byrne RA; ESC Scientific Document Group; ESC Committee for Practice Guidelines (CPG); ESC National Cardiac Societies. 2017 ESC focused update on dual antiplatelet therapy in coronary artery disease developed in collaboration with EACTS: The Task Force for Dual Antiplatelet Therapy in Coronary Artery Disease of the European Society of Cardiology (ESC) and of the European Association for Cardio-Thoracic Surgery (EACTS). *Eur Heart J* 2018; 39:213-260.
- Narouze S, Benzon HT, Provenzano D, et al. Interventional spine and pain procedures in patients on antiplatelet and anticoagulant medications (Second Edition): Guidelines from the American Society of Regional Anesthesia and Pain Medicine, the European Society of Regional Anaesthesia and Pain Therapy, the American Academy of Pain Medicine, the International Neuromodulation Society, the North American Neuromodulation Society, and the World Institute of Pain. *Reg Anesth Pain Med* 2018; 43:225-262.
- Douketis JD, Spyropoulos AC, Duncan J, et al. Perioperative management of patients with atrial fibrillation receiving a direct oral anticoagulant. *JAMA Intern Med* 2019; 179:1469-1478.
- Buck BH, Sposato LA, Field TS. Looking for atrial fibrillation with insertable cardiac monitors-is 1 year long enough and does it matter? *JAMA Neurol* 2023; 80:1266-1268.
- van Hylckama Vlieg MAM, Nasserinejad K, Visser C, et al. The risk of recurrent venous thromboembolism after discontinuation of anticoagulant therapy in patients with cancer-associated thrombosis: A systematic review and meta-analysis. *EClinicalMedicine* 2023; 64:102194.
- Zhang H, Xie H, Wang X, Zhu Z, Duan F. Effectiveness and safety of non-vitamin K antagonist oral anticoagulant in the treatment of patients with morbid obesity or high body weight with venous thromboembolism: A meta-analysis. *Medicine (Baltimore)* 2023; 102:e35015.
- Galea R, Seiffge D, Räber L. Atrial fibrillation and ischemic stroke despite oral anticoagulation. *J Clin Med* 2023; 12:5784.
- Schneider BJ, Miller DC, Mattie R, McCormick ZL, Smith C. Anticoagulants for lumbar epidural steroid injections. *Pain Med* 2020; 21:1294-1295.
- Darwish G. The effect of direct oral anticoagulant therapy (DOACs) on oral surgical procedures: A systematic review. *BMC Oral Health* 2023; 23:743.
- De Caterina R. The current role of anticoagulants in cardiovascular medicine. *J Cardiovasc Med (Hagerstown)* 2009; 10:595-604.
- Madrid C, Sanz M. What influence do anticoagulants have on oral implant therapy? A systematic review. *Clin Oral Implants Res* 2009; 20:96-106.
- Bajkin BV, Vujkov SB, Milekic BR, Vuckovic BA. Risk factors for bleeding after oral surgery in patients who continued using oral anticoagulant therapy. *J Am Dent Assoc* 2015; 146:375-381.
- Cannon PD, Dharmar VT. Minor oral surgical procedures in patients on oral anticoagulants—a controlled study. *Aust Dent J* 2003; 48:115-118.
- Jenkins AT, Kantorovich A, Burman L. Contemporary use of oral antithrombotic agents: Focus on dual and triple therapeutic approaches. *Pharmacotherapy* 2017; 37:1545-1564.
- Colonna P, Andreotti F, Ageno W, Pengo V, Marchionni N. Clinical conundrums in antithrombotic therapy management: A Delphi Consensus panel. *Int J Cardiol* 2017; 249:249-256.
- Scherillo M, Cirillo P, Formigli D, et al. Antiplatelet therapy for non-ST-segment elevation myocardial infarction in complex “real” clinical scenarios: a consensus document of the “Campania NSTEMI Study Group”. *Angiology* 2017; 68:598-607.
- Zhao Q, Zhu Y, Xu Z, et al. Effect of

- ticagrelor plus aspirin, ticagrelor alone, or aspirin alone on saphenous vein graft patency 1 year after coronary artery bypass grafting: A randomized clinical trial. *JAMA* 2018; 319:1677-1686.
30. Johnston SC, Easton JD, Farrant M, et al; Clinical Research Collaboration, Neurological Emergencies Treatment Trials Network, and the POINT Investigators. Clopidogrel and aspirin in acute ischemic stroke and high-risk TIA. *N Engl J Med* 2018; 379:215-225.
  31. Grotta JC. Antiplatelet therapy after ischemic stroke or TIA. *N Engl J Med* 2018; 379:291-292.
  32. Alexander JH. Ticagrelor following coronary artery bypass grafting: For better vein graft patency or better patient outcomes? *JAMA* 2018; 319:1661-1662.
  33. Roule V, Blanchart K, Humbert X, et al. Antithrombotic therapy for ACS in elderly patients. *Cardiovasc Drugs Ther* 2017; 31:609-618.
  34. Proietti M, Romanazzi I, Romiti GF, Farcomeni A, Lip GYH. Real-world use of Apixaban for stroke prevention in atrial fibrillation: A systematic review and meta-analysis. *Stroke* 2018; 49:98-106.
  35. Johnston A, Jones WS, Hernandez AF. The ADAPTABLE Trial and aspirin dosing in secondary prevention for patients with coronary artery disease. *Curr Cardiol Rep* 2016; 18:81.
  36. Goes R, Muskens IS, Smith TR, Mekary RA, Broekman mL, Moojen WA. Risk of aspirin continuation in spinal surgery: A systematic review and meta-analysis. *Spine J* 2017; 17:1939-1946.
  37. Laferrière C, Moazzami C, Belley-Côté E, et al. Aspirin for the primary prevention of vascular ischemic events: An updated systematic review and meta-analysis to support shared decision-making. *CJC Open* 2023; 5:881-890.
  38. McNeil JJ, Nelson MR, Woods RL, et al; ASPREE Investigator Group. Effect of aspirin on all-cause mortality in the healthy elderly. *N Engl J Med* 2018; 379:1519-1528.
  39. Mahady SE, Margolis KL, Chan A, et al. Major GI bleeding in older persons using aspirin: Incidence and risk factors in the ASPREE randomised controlled trial. *Gut* 2021; 70:717-724.
  40. Kumar N, Palmisciano P, Dhawan S, Boakye M, Drazin D, Sharma M. Spontaneous spinal hematoma in patients using antiplatelets and anticoagulants: A systematic review. *World Neurosurg* 2024; 184:e185-e194.
  41. Schieber MR, Schubert AK, Hubner W, Volk T. Influence of antithrombotic medication on size and neurological outcome of spinal epidural hematoma after neuraxial anesthesia: A systematic review. *Reg Anesth Pain Med* 2023 Dec 21: Epub ahead of print.
  42. Hart RG, Sharma M, Mundl H, et al; NAVIGATE ESUS Investigators. Rivaroxaban for Stroke Prevention after Embolic Stroke of Undetermined Source. *N Engl J Med* 2018; 378:2191-2201.
  43. Tsao CW, Aday AW, Almaraz ZI, et al. Heart disease and stroke statistics-2022 update: A report from the American Heart Association. *Circulation* 2022; 145:e153-e639.
  44. Chugh SS, Havmoeller R, Narayanan K, et al. Worldwide epidemiology of atrial fibrillation: A Global Burden of Disease 2010 Study. *Circulation* 2014; 129:837-847.
  45. Wolf PA, Abbott RD, Kannel WB. Atrial fibrillation as an independent risk factor for stroke: The Framingham Study. *Stroke* 1991; 22:983-988.
  46. Seiffge DJ, De Marchis GM, Koga M, et al; RAF, RAF-DOAC, CROMIS-2, SAMURAI, NOACISP, Erlangen, and Verona registry collaborators. Ischemic Stroke despite oral anticoagulant therapy in patients with atrial fibrillation. *Ann Neurol* 2020; 87:677-687.
  47. Ip YMB, Lau KK, Ko H, et al. Association of alternative anticoagulation strategies and outcomes in patients with ischemic stroke while taking a direct oral anticoagulant. *Neurology* 2023; 101:e358-e369.
  48. Polymeris AA, Meinel TR, Oehler H, et al. Aetiology, secondary prevention strategies and outcomes of ischaemic stroke despite oral anticoagulant therapy in patients with atrial fibrillation. *J Neurol Neurosurg Psychiatry* 2022; 93:588-598.
  49. Best JG, Cardus B, Klijn CJM, et al. Antithrombotic dilemmas in stroke medicine: New data, unsolved challenges. *J Neurol Neurosurg Psychiatry* 2022; 93:939-951.
  50. Manchikanti L, Benyamin RM, Swicegood JR, et al. Assessment of practice patterns of perioperative management of antiplatelet and anticoagulant therapy in interventional pain management. *Pain Physician* 2012; 15:E955-E968.
  51. Manchikanti L, Sanapati MR, Pampati V, et al. Updated assessment of practice patterns of perioperative management of antiplatelet and anticoagulant therapy in interventional pain management. *Pain Physician* 2024; 27:S95-S114.
  52. Manchikanti L, Knezevic NN, Navani A, et al. Epidural interventions in the management of chronic spinal pain: American Society of Interventional Pain Physicians (ASIPP) comprehensive evidence-based guidelines. *Pain Physician* 2021; 24:S27-S208.
  53. Manchikanti L, Sanapati MR, Kaye AD, Kaye AM. Antiplatelet and anticoagulant therapy in interventional pain management. In: Manchikanti L, Singh V, Falco FJE, Kaye AD, Sooin A, Hirsch JA (eds). *Essentials of Interventional Techniques in Managing Chronic Pain*, 2nd ed. Springer Nature Switzerland, 2024, pp 83-100.
  54. Manchikanti L, Kaye AD, Sooin A, et al. Comprehensive evidence-based guidelines for facet joint interventions in the management of chronic spinal pain: American Society of Interventional Pain Physicians (ASIPP) guidelines. *Pain Physician* 2020; 23:S1-S127.
  55. Manchikanti L, Malla Y, Wargo BW, et al. A prospective evaluation of bleeding risk of interventional techniques in chronic pain. *Pain Physician* 2011; 14:317-329.
  56. Endres S, Shufelt A, Bogduk N. The risks of continuing or discontinuing anticoagulants for patients undergoing common interventional pain procedures. *Pain Med* 2017; 18:403-409.
  57. Smith CC, Schneider B, McCormick ZL, et al; Standards Division of the Spine Intervention Society. Risks and benefits of ceasing or continuing anticoagulant medication for image-guided procedures for spine pain: A systematic review. *Pain Med* 2018; 19:438-448.
  58. Endres S, Hefti K, Schlimgen E, Bogduk N. Update of a study of not ceasing anticoagulants for patients undergoing injection procedures for spinal pain. *Pain Med* 2020; 21:918-921.
  59. Kumar V, Turakhia PB, Wunnava MS. Pulmonary embolism during dorsal column stimulator (DCS) trial. *Reg Anesth Pain Med* 2013; 38 (abstract only).
  60. Seo KH, Nahm FS, Han WK, et al. Aspirin cessation before interventional procedures: Not blindly following guidelines but making test-based decisions. *Pain Physician* 2022; 25:501-507.
  61. Benzton HT, Nelson AM, Patel AG, et al. Literature review of spinal hematoma case reports: Causes and outcomes in pediatric, obstetric, neuraxial and pain

- medicine cases. *Reg Anesth Pain Med* 2024 Jan 23; Epub ahead of print.
62. Linn AJ, Desilva C, Peeters-Asdourian C. Thromboembolic stroke: A rare complication associated with periprocedural management of an epidural steroid injection. *Pain Physician* 2009; 12:159-162.
  63. Moeschler SM, Warner NS, Lamer TJ, et al. Bleeding complications in patients undergoing percutaneous spinal cord stimulator trials and implantations. *Pain Med* 2016; 17:2076-2081.
  64. LaVallee J, Royer R, Smith G. Prevalence of bleeding complications following ultrasound-guided botulinum toxin injections in patients on anticoagulation or antiplatelet therapy. *PM R* 2017; 9:1217-1224.
  65. Swicegood J, Manchikanti L, Benyamin R, Hirsch J. A report of acute thoracic epidural hematoma after interlaminar epidural injection. *IPM Reports* 2017; 1:33-38.
  66. Swicegood J, Manchikanti L, Benyamin R, Hirsch J. Two cases of acute epidural hematoma formation after cervical interlaminar epidural steroid injections. *IPM Reports* 2017; 1:27-32.
  67. Jenkie E, Benyamin R, Manchikanti L. Fish oil as a potential contributor to epidural hematoma following cervical epidural steroid injection: A case report and focused literature review. *IPM Reports* 2017; 1:19-26.
  68. Manchikanti L, Malla Y, Benyamin R, Hirsch J. Prevalence of epidural hematoma following cervical epidural injections in interventional pain management settings: Literature review with two case reports. *IPM Reports* 2017; 1:11-17.
  69. Kim SH, Han YJ, Kim YH, et al. Spontaneous absorption of a lumbar epidural hematoma after interlaminar epidural steroid injection in a patient with spinal stenosis: Close observation as a treatment strategy. *Chin Med J (Engl)* 2018; 131:117-118.
  70. Manchikanti L, Gruber TJ, Prabhakar H, Hirsch JA. Acute epidural hematoma following a cervical epidural injection in a patient without bleeding risk. *IPM Reports* 2018; 2:119-126.
  71. Lam CM, Monroe BR, Novosat T. Spontaneous resolution of presumed acute epidural hematoma formation after lumbar epidural steroid injection. *IPM Reports* 2017; 1:189-193.
  72. Candido KD. Epidural hematoma formation following neuraxial interventional pain management procedures. Have we even begun to comprehend the mechanisms and risk factors? *IPM Reports* 2017; 1:7-10.
  73. Breivik H, Norum H, Fenger-Eriksen C, et al. Reducing risk of spinal haematoma from spinal and epidural pain procedures. *Scand J Pain* 2018; 18:129-150.
  74. Horlocker TT, Bajwa ZH, Ashraf Z, et al. Risk assessment of hemorrhagic complications associated with nonsteroidal antiinflammatory medications in ambulatory pain clinic patients undergoing epidural steroid injection. *Anesth Analg* 2002; 95:1691-1697.
  75. Ahmed SU, Tonidandel W, Trella J, Martin NM, Chang Y. Peri-procedural protocols for interventional pain management techniques: A survey of US pain centers. *Pain Physician* 2005; 8:181-185.
  76. Deer TR, Narouze S, Provenzano DA, et al. The Neurostimulation Appropriateness Consensus Committee (NACC): Recommendations on bleeding and coagulation management in neurostimulation devices. *Neuromodulation* 2017; 20:51-62.
  77. Petraglia FW 3rd, Farber SH, Gramer R, et al. The incidence of spinal cord injury in implantation of percutaneous and paddle electrodes for spinal cord stimulation. *Neuromodulation* 2016; 19:85-90.
  78. Goodman BS, House LM, Vallabhaneni S, Mallempati S, Willey MR, Smith MT. Anticoagulant and antiplatelet management for spinal procedures: A prospective, descriptive study and interpretation of guidelines. *Pain Med* 2017; 18:1218-1224.
  79. van Helmond N, Day W, Chapman KB. Continuing anti-thrombotic medication during low-to-intermediate risk spinal procedures: A retrospective evaluation. *Pain Physician* 2017; 20:437-443.
  80. Furman MB, Bernstein J, Gilhool L, et al. Epidural hematoma risks associated with ceasing vs maintaining anticoagulant and/or antiplatelet medications for cervical and thoracic interlaminar epidural steroid injections. *Int Pain Med* 2023; 2:100277.
  81. Lagerkranser M. Neuraxial blocks and spinal haematoma: Review of 166 case reports published 1994-2015. Part 1: Demographics and risk-factors. *Scand J Pain* 2017; 15:118-129.
  82. Lagerkranser M, Lindquist C. Neuraxial blocks and spinal haematoma: Review of 166 cases published 1994 - 2015. Part 2: Diagnosis, treatment, and outcome. *Scand J Pain* 2017; 15:130-136.
  83. Warner NS, Hooten WM, Warner MA, et al. Bleeding and neurologic complications in 58,000 interventional pain procedures. *Reg Anesth Pain Med* 2017; 42:782-787.
  84. Ehsanian R, Rosati RM, Kennedy DJ, Schneider BJ. Antiplatelet and anticoagulant risk for select spine interventions: A retrospective cohort. *Pain Med* 2020; 21:910-917.
  85. Kubulus C, Gürtesch CA, Wagenpfeil G, Sessler DI, Volk T. Antithrombotic drugs and the risk of bloody punctures in regional anesthesia - a retrospective registry analysis. *Reg Anesth Pain Med* 2022; rapm-2022-103806.
  86. Simon JI, Gehret J, Larsen ES, Hummerston KS, Koehler Iii PJ, Kitei PM. Caudal epidural steroid injections in the setting of remaining on antithrombotics: A retrospective study. *Pain Physician* 2021; 24:E821-E828.
  87. Gallice M, Rouberol F, Albaladejo P, et al. Managing antithrombotic therapy in vitreoretinal surgery. *J Fr Ophthalmol* 2015; 38:61-73.
  88. Benyamin RM, Vallejo R, Wang V, Kumar N, Cedeno DL, Tamrazi A. Acute epidural hematoma formation in cervical spine after interlaminar epidural steroid injection despite discontinuation of clopidogrel. *Reg Anesth Pain Med* 2016; 41:398-401.
  89. Buvanendran A, Young AC. Spinal epidural hematoma after spinal cord stimulator trial lead placement in a patient taking aspirin. *Reg Anesth Pain Med* 2014; 39:70-72.
  90. Chien GC, McCormick Z, Araujo M, Candido KD. The potential contributing effect of ketorolac and fluoxetine to a spinal epidural hematoma following a cervical interlaminar epidural steroid injection: A case report and narrative review. *Pain Physician* 2014; 17:E385-395.
  91. Giberson CE, Barbosa J, Brooks ES, et al. Epidural hematomas after removal of percutaneous spinal cord stimulator trial leads: Two case reports. *Reg Anesth Pain Med* 2014; 39:73-77.
  92. Page J, Moisi M, Oskouian RJ. Lumbar epidural hematoma following interlaminar fluoroscopically guided epidural steroid injection. *Reg Anesth Pain Med* 2016; 41:402-404.
  93. Sanders RA, Bendel MA, Moeschler SM, Mauck WD. Epidural hematoma following interlaminar epidural

- injection in patient taking aspirin. *Reg Anesth Pain Med* 2018; 43:310-312.
94. Berrigan WA, Whitehair C, Zorowitz R. Acute spinal epidural hematoma as a complication of dry needling: A case report. *PM R* 2019; 11:313-316.
  95. Cameron CM, Scott DA, McDonald WM, Davies MJ. A review of neuraxial epidural morbidity: Experience of more than 8,000 cases at a single teaching hospital. *Anesthesiology* 2007; 106:997-1002.
  96. Noori S, Laufer I, Gulati A. Acute epidural hematoma occurring after removal of percutaneous spinal cord stimulator trial leads in a cancer patient with chronic thrombocytopenia: A case report. *IPM Reports* 2018; 2:27-33.
  97. Warner NS, Bendel MA, Warner MA, et al. Bleeding complications in patients undergoing intrathecal drug delivery system implantation. *Pain Med* 2017; 18:2422-2427.
  98. Caputo AM, Gottfried ON, Nimjee SM, Brown CR, Michael KW, Richardson WJ. Spinal epidural hematoma following epidural steroid injection in a patient treated with dabigatran: A case report. *JBJS Case Connect* 2013; 3:e64.
  99. Warner NS, Moeschler SM, Warner MA, et al. Bleeding complications in patients undergoing celiac plexus block. *Reg Anesth Pain Med* 2016; 41:488-493.
  100. Lagerkranser M, Johnsson H, Ljungström KG. Management of thrombocyte inhibitors prior to surgery. Too early withdrawal can result in severe risks for the patient. *Lakartidningen* 2008; 105:2188-2189.
  101. Gould MK, Garcia DA, Wren SM, et al. Prevention of VTE in nonorthopedic surgical patients: Antithrombotic therapy and prevention of thrombosis, 9th ed: American College of Chest Physicians evidence-based clinical practice guidelines. *Chest* 2012; 141:e227S-e277S.
  102. Falck-Ytter Y, Francis CW, Johanson NA, et al. Prevention of VTE in orthopedic surgery patients: Antithrombotic therapy and prevention of thrombosis, 9th ed: American College of Chest Physicians evidence-based clinical practice guidelines. *Chest* 2012; 141:e278S-e325S.
  103. ACCP-NHLBI national conference on antithrombotic therapy. American College of Chest Physicians and the National Heart, Lung and Blood Institute. *Chest* 1986; 89:1S-106S.
  104. Guyatt GH, Akl EA, Crowther M, Schünemann HJ, Gutterman DD, Lewis SZ. Introduction to the ninth edition: Antithrombotic therapy and prevention of thrombosis, 9th ed: American College of Chest Physicians evidence-based clinical practice guidelines. *Chest* 2012; 141:48S-52S.
  105. Eikelboom JW, Hirsh J, Spencer FA, Baglin TP, Weitz JI. Antiplatelet drugs: Antithrombotic therapy and prevention of thrombosis, 9th ed: American College of Chest Physicians evidence-based clinical practice guidelines. *Chest* 2012; 141:e89S-e119S).
  106. Manchikanti L, Kaye AM, Knezevic NN, et al. Comprehensive, evidence-based, consensus guidelines for prescription of opioids for chronic non-cancer pain from the American Society of Interventional Pain Physicians (ASIPP). *Pain Physician* 2023;26:S7-S126.
  107. Dowell D, Haegerich TM, Chou R. CDC guideline for prescribing opioids for chronic pain—United States, 2016. *MMWR Recomm Rep* 2016; 65:1-49.
  108. Dowell D, Ragan KR, Jones CM, Baldwin GT, Chou R. CDC Clinical Practice Guideline for Prescribing Opioids for Pain — United States, 2022. *MMWR Recomm Rep* 2022; 71:1-95.
  109. U.S. Department of Health and Human Services. Pain Management Best Practices Inter-Agency Task Force. Final Report on Pain Management Best Practices: Updates, Gaps, Inconsistencies, and Recommendations. May 9, 2019. Accessed 02/02/2024. <https://www.hhs.gov/sites/default/files/pmtf-final-report-2019-05-23.pdf>
  110. Bell LV, Fitzgerald SF, Flusk D, Poulin PA, Rash JA. Healthcare provider knowledge, beliefs, and attitudes regarding opioids for chronic non-cancer pain in North America prior to the emergence of COVID-19: A systematic review of qualitative research. *Can J Pain* 2023; 7:2156331.
  111. Manchikanti L, Singh V, Kaye AD, Hirsch JA. Lessons for better pain management in the future: Learning from the past. *Pain Ther* 2020; 9:373-391.
  112. Applewhite MK, Leyva MA, Giordano J. Grounding guidelines in ethics: Recommendations for implementation in practice. *Pain Physician* 2023; 26:S1-S5.
  113. The National Uniform Claims Committee. Specialty Designation for Interventional Pain Management-09. Accessed 02/28/2023. <http://www.cms.hhs.gov/transmittals/Downloads/r1779b3.pdf>
  114. Medicare Payment Advisory Commission. Report to the Congress: Paying for interventional pain services in ambulatory settings. Washington, DC: MedPAC. December 2001. Accessed 02/28/2023. <https://permanent.fdlp.gov/lps21261/dec2001PainManagement.pdf>
  115. Graham R, Mancher M, Wolman DM, Greenfield S, Steinberg E (eds); *Committee on Standards for Developing Trustworthy Clinical Practice Guidelines; Institute of Medicine. Clinical Practice Guidelines We Can Trust*. The National Academies Press, Washington, DC, 2011.
  116. Jue JJ, Cunningham S, Lohr K, et al. Developing and Testing the Agency for Healthcare Research and Quality's National Guideline Clearinghouse Extent of Adherence to Trustworthy Standards (NEATS) Instrument. *Ann Intern Med* 2019; 170:480-487.
  117. Manchikanti L, Falco FJE, Benyamin RM, Kaye AD, Boswell MV, Hirsch JA. A modified approach to grading of evidence. *Pain Physician* 2014; 17:E319-E325.
  118. Manchikanti L, Atluri S, Boswell MV, et al. Methodology for evidence synthesis and development of comprehensive evidence-based guidelines for interventional techniques in chronic spinal pain. *Pain Physician* 2021; 24:S1-S26.
  119. EBM Toolkit, Learn EBM: What is GRADE? *BMJ Best Practice*. Accessed 04/05/2023. <https://bestpractice.bmj.com/info/us/toolkit/learn-ebm/what-is-grade/>
  120. Balslem H, Helfand M, Schünemann HJ, et al. GRADE guidelines: 3. Rating the quality of evidence. *J Clin Epidemiol* 2011; 64:401-406.
  121. Ryan R, Hill S. How to GRADE the quality of the evidence. Version 3.0. December 2016. Accessed 04/05/2023. <http://ccrg.cochrane.org/author-resources>
  122. Dal-Ré R, Janiaud P, Ioannidis JPA. Real-world evidence: How pragmatic are randomized controlled trials labeled as pragmatic? *BMC Med* 2018; 16:49.
  123. Jones J, Hunter D. Consensus methods for medical and health services research. *BMJ* 1995; 311:376-380.
  124. Dubois V, Dincq AS, Douxfils J, et al. Perioperative management of patients on direct oral anticoagulants. *Thromb J* 2017; 15:14.
  125. Herranz-Heras JC, Alcalde-Blanco L, Cañas-Zamarra I, et al. Update on the perioperative management of antiplatelets and anticoagulants in ophthalmic surgery. *Arch Soc Esp*

- Ophthalmol (Engl Ed)* 2021; 96:422-429.
126. Saito K, Saito Y, Muramatsu T, et al. Impact of perioperative antithrombotic strategies on clinical events in non-cardiac surgery. *Heart Vessels* 2022; 37:1337-1343.
  127. Shah S, Nayfeh T, Hasan B, et al. Perioperative management of vitamin K antagonists and direct oral anticoagulants: A systematic review and meta-analysis. *Chest* 2023; 163:1245-1257.
  128. Wolff G, Navarese EP, Brockmeyer M, et al. Perioperative aspirin therapy in non-cardiac surgery: A systematic review and meta-analysis of randomized controlled trials. *Int J Cardiol* 2018; 258:59-67.
  129. Horlocker TT, Vandermeulen E, Kopp SL, Gogarten W, Leffert LR, Benzon HT. Regional Anesthesia in the patient receiving antithrombotic or thrombolytic therapy: American Society of Regional Anesthesia and Pain Medicine Evidence-Based Guidelines (Fourth Edition). *Reg Anesth Pain Med* 2018; 43:263-309.
  130. Vandermeulen EP, van Aken H, Vermeylen J. Anticoagulants and spinal epidural anesthesia. *Anesth Analg* 1994; 79:1165-1177.
  131. Wulf H. Epidural anaesthesia and spinal haematoma. *Can J Anaesth* 1996; 43:1260-1271.
  132. Desai MJ, Dua S. Perineural hematoma following lumbar transforaminal steroid injection causing acute-on-chronic lumbar radiculopathy: A case report. *Pain Pract* 2014; 14:271-277.
  133. Shanthanna H, Park J. Acute epidural haematoma following epidural steroid injection in a patient with spinal stenosis. *Anaesthesia* 2011; 66:837-839.
  134. Williams KN, Jackowski A, Evans PJ. Epidural haematoma requiring surgical decompression following repeated cervical epidural steroid injections for chronic pain. *Pain* 1990; 42:197-199.
  135. Ghaly RF. Recovery after high-dose methylprednisolone and delayed evacuation: A case of spinal epidural hematoma. *J Neurosurg Anesthesiol* 2001; 13:323-328.
  136. Weller RS, Gerancher JC, Crews JC, Wade KL. Extensive retroperitoneal hematoma without neurologic deficit in two patients who underwent lumbar plexus block and were later anticoagulated. *Anesthesiology* 2003; 98:581-585.
  137. Stoll A, Sanchez M. Epidural hematoma after epidural block: Implications for its use in pain management. *Surg Neurol* 2002; 57:235-240.
  138. Swerdlow M. Medico-legal aspects of complications following pain relieving blocks. *Pain* 1982; 13:321-331.
  139. Chiravuri S, Wasserman R, Chawla A, Haider N. Subdural hematoma following spinal cord stimulator implant. *Pain Physician* 2008; 11:97-101.
  140. Xu R, Bydon M, Gokaslan ZL, Wolinsky JP, Witham TF, Bydon A. Epidural steroid injection resulting in epidural hematoma in a patient despite strict adherence to anticoagulation guidelines. *J Neurosurg Spine* 2009; 11:358-364.
  141. Ain RJ, Vance MB. Epidural hematoma after epidural steroid injection in a patient withholding enoxaparin per guidelines. *Anesthesiology* 2005; 102:701-703.
  142. Lee JH, Lee H, Jo DJ. An acute cervical epidural hematoma as a complication of dry needling. *Spine (Phila Pa 1976)* 2011; 36:E891-E893.
  143. Reitman CA, Watters W 3rd. Subdural hematoma after cervical epidural steroid injection. *Spine (Phila Pa 1976)* 2002; 27:E174-E176.
  144. Eftekhari B, Ketabchi E, Ghodsi M, Esmaeili B. Lumbar epidural hematoma due to lumbar acupuncture. *Neurol India* 2005; 53:245-246.
  145. Ozdemir O, Calisaneller T, Yildirim E, Altinors N. Acute intracranial subdural hematoma after epidural steroid injection: A case report. *J Manipulative Physiol Ther* 2007; 30:536-538.
  146. Chen JC, Chen Y, Lin SM, Yang HJ, Su CF, Tseng SH. Acute spinal epidural hematoma after acupuncture. *J Trauma* 2006; 60:414-416.
  147. Lee JY, Nassr A, Ponnappan RK. Epidural hematoma causing paraplegia after a fluoroscopically guided cervical nerve-root injection. A case report. *J Bone Joint Surg Am* 2007; 89:2037-2039.
  148. Bose B. Quadriparesis following cervical epidural steroid injections: Case report and review of the literature. *Spine J* 2005; 5:558-563.
  149. Domenicucci M, Marruzzo D, Pesce A, Raco A, Missori P. Acute spinal epidural hematoma after acupuncture: Personal case and literature review. *World Neurosurg* 2017; 102:695.e11-695.e14.
  150. Fitzgibbon DR, Posner KL, Domino KB, Caplan RA, Lee LA, Cheney FW; American Society of Anesthesiologists. Chronic pain management: American Society of Anesthesiologists Closed Claims Project. *Anesthesiology* 2004; 100:98-105.
  151. Maier C, Gleim M, Weiss T, Stachetzki U, Nicolas V, Zenz M. Severe bleeding following lumbar sympathetic blockade in two patients under medication with irreversible platelet aggregation inhibitors. *Anesthesiology* 2002; 97:740-743.
  152. Benzon HT, Wong HY, Siddiqui T, Ondra S. Caution in performing epidural injections in patients on several antiplatelet drugs. *Anesthesiology* 1999; 91:1558-1559.
  153. Keane JR, Ahmadi J, Gruen P. Spinal epidural hematoma with subarachnoid hemorrhage caused by acupuncture. *AJNR Am J Neuroradiol* 1993; 14:365-366.
  154. Choi JJ, Chang YJ, Jung WS, Lee KC, Kim JH, Jo YY. Discordant lumbar epidural hematoma after caudal steroid injection: A case report (CARE-compliant). *Medicine (Baltimore)* 2017; 96:e7127.
  155. Kim M, Park KS. Intracranial chronic subdural hematoma presenting with intractable headache after cervical epidural steroid injection. *J Korean Neurosurg Soc* 2015; 58:144-146.
  156. Takawira N, Han RJ, Nguyen TQ, Gaines JD, Han TH. Spinal cord stimulator and epidural haematoma. *Br J Anaesth* 2012; 109:649-650.
  157. Kloss BT, Sullivan AM, Rodriguez E. Epidural hematoma following spinal cord stimulator implant. *Int J Emerg Med* 2010; 3:483-484.
  158. Smith CC, Lin JL, Shokat M, Dosanjh SS, Casthely D. A report of paraparesis following spinal cord stimulator trial, implantation and revision. *Pain Physician* 2010; 13:357-363.
  159. Santiago FM, Santiago J, Prieto M, et al. Dorsal epidural hematoma after implantation of a dorsal nerve stimulator. *Rev Esp Anesthesiol Reanim* 2005; 52:440-441.
  160. Chen CY, Liu GC, Sheu RS, Huang CL. Bacterial meningitis and lumbar epidural hematoma due to lumbar acupuncture: A case report. *Kaohsiung J Med Sci* 1997; 13:328-331.
  161. Nam KH, Choi CH, Yang MS, Kang DW. Spinal epidural hematoma after pain control procedure. *J Korean Neurosurg Soc* 2010; 48:281-284.
  162. Jang JS, Jin HY, Seo JS, et al. A meta-analysis of randomized controlled trials appraising the efficacy and safety of cilostazol after coronary artery stent implantation. *Cardiology* 2012; 122:133-143.

163. Kolber MR, Korownyk C. An aspirin a day? Aspirin use across a spectrum of risk: Cardiovascular disease, cancers and bleeds. *Expert Opin Pharmacother* 2014; 15:153-157.
164. Raj PP, Shah RV, Kaye AD, Denaro S, Hoover JM. Bleeding risk in interventional pain practice: Assessment, management, and review of the literature. *Pain Physician* 2004; 7:3-51.
165. Gupta S, Sharma M. Interventional pain medicine practice in the UK and the USA: A survey of 242 pain physicians. *Pain Physician* 2020; 23:127-134.
166. McCormick ZL, Popescu A, Smith C; Spine Intervention Society's Patient Safety Committee. Fact finders for patient safety: Risk of bleeding with nonaspirin nonsteroidal anti-inflammatory drugs before spine procedures. *Pain Med* 2018; 19:2322-2323.
167. Lucijanic M, Ziga S, Grgurevic I. Comment to: "Management and outcome of gastrointestinal bleeding in patients taking oral anticoagulants or antiplatelet drugs". *J Gastroenterol* 2017; 52:1075-1076.
168. Luo M, Cao Q, Zhao Z, et al. Risk factors of epidural hematoma in patients undergoing spinal surgery: A meta-analysis of 29 cohort studies. *Int J Surg* 2023; 109:3147-3158.
169. Ali D, El Khoumsi M, Gorur Y, Cardoso B, Villalba NL. Rare case of ischaemic stroke following cervical transforaminal injection. *Eur J Case Rep Intern Med* 2019; 6:001082.
170. Aljuboori Z, Williams B. Spinal intramedullary hematoma presenting years following a cervical epidural injection. *Surg Neurol Int* 2021; 12:430.
171. Bao C, Bao S. Hemorrhagic infarction of cerebellum and brainstem due to cervical epidural steroid injection - Case report and review of the literature. *Acad Forensic Pathol* 2018; 8:952-956.
172. Chen CL, Chang MH, Lee WJ. A case report: An acute spinal epidural hematoma after acupuncture mimicking stroke. *J Emerg Med* 2020; 58:e185-e188.
173. Dehaene S, Biesemans J, Van Boxem K, Vidts W, Sterken J, Van Zundert J. Post-dural puncture headache evolving to a subdural hematoma: A case report. *Pain Pract* 2021; 21:83-87.
174. Kim SI, Lee DH, Kim SH, Cho YH. Spinal epidural hematoma occurring at a distance from the transforaminal epidural injection site: A case report. *Medicine (Baltimore)* 2019; 98:e16654.
175. Lee DY, Park YJ, Kim KT, Lee JH, Kim DH. Acute lumbosacral hemorrhagic ganglion cyst after transforaminal epidural steroid injection. *Acta Orthop Traumatol Turc* 2018; 52:475-479.
176. Nogami R, Matsuoka H, Ohashi S, Narikiyo M, Nagasaki H, Tsuboi Y. Spinal subarachnoid hemorrhage after percutaneous kyphoplasty: A case report and literature review. *J Spine Surg* 2022; 8:491-496.
177. Platt A, Ammar FE, Collins J, Ramos E, Goldenberg FD. Pseudo-subarachnoid hemorrhage and gadolinium encephalopathy following lumbar epidural steroid injection. *Radiol Case Rep* 2020; 15:1935-1938.
178. Yu Y, Kim TH, Lee SH, Chang MC. Epidural hematoma after trans-sacral epiduroscopic laser decompression: A case report. *Photobiomodul Photomed Laser Surg* 2020; 38:112-114.
179. Beasley D, Goree JH. Cervical epidural hematoma following interlaminar epidural steroid injection via the contralateral oblique view in patient taking omega-3 fatty acids. *Reg Anesth Pain Med* 2019; 44:253-255.
180. Kim GE, Hong SJ, Kang SS, Ki HJ, Park JH. Epidural hematoma treated by aspiration after transforaminal epidural steroid injection - A case report. *Anesth Pain Med (Seoul)* 2021; 16:184-190.
181. Cho YJ, Jung H, Moon S, Ryoo HW. Cervical epidural hematoma with Brown-Sequard syndrome caused by an epidural injection: A case report. *Clin Exp Emerg Med* 2021; 8:336-339.
182. Kim SW, Chang MC. Epidural hematoma after caudal epidural pulsed radiofrequency stimulation: A case report. *Medicine (Baltimore)* 2018; 97:e13090.
183. Mehta N. Intracranial hemorrhage and pneumocephaly after cervical epidural injection. *Clin Pract Cases Emerg Med* 2019; 3:369-371.
184. Zou P, Gong HL, Wei JM, et al. Spinal epidural hematoma after percutaneous kyphoplasty: Case report and literature review. *J Pain Res* 2020; 13:2799-2804.
185. Helm S, Sanapati MR, Noe C, Racz G. Fulminant Cervical epidural hematomas: Why do they happen, how can we minimize their occurrence, and what can we do when they do occur? A Perspective. *Pain Physician* 2023; 26:449-456.
186. Domenicucci M, Mancarella C, Santoro G, et al. Spinal epidural hematomas: Personal experience and literature review of more than 1000 cases. *J Neurosurg Spine* 2017; 27:198-208.
187. Banik RK, Chen CC. Spinal epidural hematoma after interlaminar cervical epidural steroid injection. *Anesthesiology* 2019; 131:1342-1343.
188. Palmer E. Management of cervical epidural hematoma after cervical epidural steroid injection using a catheter technique. *Pain Med* 2020; 21:1301-1302.
189. Smith GA, Pace J, Strohl M, Kaul A, Hayek S, Miller JP. Rare neurosurgical complications of epidural injections: An 8-yr single-institution experience. *Oper Neurosurg (Hagerstown)* 2017; 13:271-279.
190. Karri J, Chien GC, Polson G, McDaniel S, Glaser S. Case of epidural hematoma following a lumbar epidural steroid injection in a patient taking aspirin and duloxetine. *Pain Med Case Reports* 2020; 4:121-126.
191. Petro J, Asgerally A, Simopoulos T, Urits I, Aner M. Diagnosis and spontaneous resolution of an epidural hematoma in a patient presenting after cervical epidural steroid injection. *IPM Reports* 2018; 2:213-219.
192. Mallett SV. Clinical utility of viscoelastic tests of coagulation (TEG/ROTEM) in patients with liver disease and during liver transplantation. *Semin Thromb Hemost* 2015; 41:527-537.
193. Mimata R, Higashi M, Yasui M, Hirai T, Yamaura K. Spinal epidural hematoma following epidural catheter removal in a patient with postoperative urgent coronary intervention and Intra-Aortic Balloon Pumping (IABP): A case report. *Am J Case Rep* 2019; 20:1356-1359.
194. Park J, Ahn R, Son D, Kang B, Yang D. Acute spinal subdural hematoma with hemiplegia after acupuncture: A case report and review of the literature. *Spine J* 2013; 13:e59-e63.
195. Fan X, Ren H, Lu Z. Epidural hematoma with dramatical recovery: A rare severe complication of spinal cord stimulation. *Asian J Surg* 2022; 45:2460-2461.
196. Ito Y, Bhagwat A. Intrathecal haematoma after an epidural blood patch. *BMJ Case Rep* 2022; 15:e246725.
197. Chu EC, Trager RJ, Lai CR, Shum JS. Spontaneous cervical epidural hematoma following COVID-19 illness presenting to a chiropractor: A case report. *Cureus* 2022; 14:e32199.
198. Kim CH, Kim P, Ju CI, Kim SW. Massive epidural hematoma caused by percutaneous epidural neuroplasty: A

- case report. *Korean J Neurotrauma* 2023; 19:393-397.
199. Elgafy H, Peters N, Lea JE, Wetzel RM. Hemorrhagic lumbar synovial facet cyst secondary to transforaminal epidural injection: A case report and review of the literature. *World J Orthop* 2016; 7:452-457.
  200. Williamson ES, Hughes JA, Bentley CM, Neely GA, Hollis NM. Hematoma after continuous erector spinae plane block with catheter placement: A case report. *A A Pract* 2022; 16:e01653.
  201. Metzger C, Liu AA, Wang C, Gordin V. Development of psoas hematoma after lumbar sympathetic block in a patient on anticoagulants. *Pain Med Case Reports* 2021; 5:333-336.
  202. Hongo T, Iseda K, Tsuchiya M, et al. Two cases of spontaneous cervical epidural hematoma without back or neck pain in elderly Japanese men. *Acute Med Surg* 2017; 5:181-184.
  203. Roden KS, Owen JA, Nobles RH. Intrathecal bleed following percutaneous spinal cord stimulator trial lead placement. *IPM Reports* 2017; 1:105-111.
  204. Menezes M, Orhurhu V, Quezado R, Shihab A. Hematoma after a fluoroscopically guided sacroiliac joint injection: A case report. *Pain Med Case Reports* 2021; 5:63-66.
  205. Gungor S, Aiyer R. Epidural hematoma development contralateral to dura after lumbar transforaminal epidural steroid injection. *Pain Manag* 2017; 7:367-375.
  206. Thomas O, Rein H, Strandberg K, Schott U. Coagulative safety of epidural catheters after major upper gastrointestinal surgery: Advanced and routine coagulation analysis in 38 patients. *Perioper Med (Lond)* 2016; 5:28.
  207. Thomas OD. Haemostatic safety in epidural analgesia. Lund: Lund University, Faculty of Medicine, Doctoral Dissertation Series 2016:117. Accessed 1/9/2024. [http://portal.research.lu.se/portal/files/15557976/Haemostatic\\_safety\\_in\\_epidural\\_analgesia\\_minus\\_manus.pdf](http://portal.research.lu.se/portal/files/15557976/Haemostatic_safety_in_epidural_analgesia_minus_manus.pdf)
  208. Forkin KT, Colquhoun DA, Nemergut EC, Huffmeyer JL. The coagulation profile of end-stage liver disease and considerations for intraoperative management. *Anesth Analg* 2018; 126:46-61.
  209. Patrono C, Baigent C, Hirsh J, Roth G; Physicians American College of Chest Physicians. Antiplatelet drugs: American College of Chest Physicians evidence based clinical practice guidelines (8th Edition). *Chest* 2008; 133:199S-233S.
  210. Moshfegh K, Redondo M, Julmy F, et al. Antiplatelet effects of clopidogrel compared with aspirin after myocardial infarction: Enhanced inhibitory effects of combination therapy. *J Am Coll Cardiol* 2000; 36:699-705.
  211. Onyeji CO, Tessier PR, Nightingale CH, Vallee F, Nicolau DP. Pharmacokinetics of ticlopidine in the rabbit. *J Pharm Pharmacol* 1999; 51:393-396.
  212. Baker WL, White CM. Role of prasugrel, a novel P2Y12 receptor antagonist, in the management of acute coronary syndromes. *Am J Cardiovasc Drugs* 2009; 9:213-229.
  213. Brandt JT, Close SL, Iturria SJ, et al. Common polymorphisms of CYP2C19 and CYP2C9 affect the pharmacokinetic and pharmacodynamic response to clopidogrel but not prasugrel. *J Thromb Haemost* 2007; 5:2429-2436.
  214. Gu X, Fu X, Wang Y, Zhang W, et al. Comparison of ticagrelor and high-dose clopidogrel on the platelet functions in patients with inadequate response to clopidogrel. *Am J Cardiovasc Dis* 2017; 7:1-8.
  215. Teng R. Ticagrelor: Pharmacokinetic, pharmacodynamic and pharmacogenetic profile: An update. *Clin Pharmacokinet* 2015; 54:1125-1138.
  216. Teng R, Oliver S, Hayes MA, Butler K. Absorption, distribution, metabolism, and excretion of ticagrelor in healthy subjects. *Drug Metab Dispos* 2010; 38:1514-1521.
  217. Weber AA, Schrör K. Pharmacology of ticlopidine and clopidogrel in comparison with acetylsalicylic acid. *Internist (Berl)* 1997; 38:1115-1120.
  218. Schrör K. The pharmacology of cilostazol. *Diabetes Obes Metab* 2002; 4:S14-S19.
  219. Russell TL, Berardi RR, Barnett JL, O'Sullivan TL, Wagner JG, Dressman JB. Ph-related changes in the absorption of dipyridamole in the elderly. *Pharm Res* 1994; 11:136-143.
  220. Woo SK, Kang WK, Kwon KI. Pharmacokinetic and pharmacodynamic modeling of the antiplatelet and cardiovascular effects of cilostazol in healthy humans. *Clin Pharmacol Ther* 2002; 71:246-252.
  221. Lee K, Kim JY, Yoo BS, et al. Cilostazol augments the inhibition of platelet aggregation in clopidogrel low-responders. *J Thromb Haemost* 2010; 8:2577-2579.
  222. Ikeda Y, Kikuchi M, Murakami H, et al. Comparison of the inhibitory effects of cilostazol, acetylsalicylic acid and ticlopidine on platelet functions ex vivo. Randomized, double-blind crossover study. *Arzneimittelforschung* 1987; 37:563-566.
  223. Gogarten W, Vandermeulen E, Van Aken H, Kozek S, Llau JV, Samama CM; European Society of Anaesthesiology. Regional anaesthesia and antithrombotic agents: Recommendations of the European Society of Anaesthesiology. *Eur J Anaesthesiol* 2010; 27:999-1015.
  224. Collier BS. Anti-GPIIb/IIIa drugs: Current strategies and future directions. *Thromb Haemost* 2001; 86:427-443.
  225. Rosencher N, Bonnet MP, Sessler DI. Selected new antithrombotic agents and neuraxial anaesthesia for major orthopaedic surgery: management strategies. *Anaesthesia* 2007; 62:1154-11660.
  226. Andexxa-An antidote for apixaban and rivaroxaban. *JAMA* 2018; 320:399-400.
  227. Plosker GL. Rivaroxaban: A review of its use in acute coronary syndromes. *Drugs* 2014; 74:451-464.
  228. Frost C, Wang J, Nepal S, et al. Apixaban, an oral, direct factor Xa inhibitor: Single dose safety, pharmacokinetics, pharmacodynamics and food effect in healthy subjects. *Br J Pharmacol* 2013; 75:476-487.
  229. Frost C, Nepal S, Wang J, et al. Safety, pharmacokinetics and pharmacodynamics of multiple oral doses of apixaban, a factor Xa inhibitor, in healthy subjects. *Br J Clin Pharmacol* 2013; 76:776-786.
  230. Raghavan N, Frost CE, Yu Z, et al. Apixaban metabolism and pharmacokinetics after oral administration to humans. *Drug Metab Dispos* 2009; 37:74-81.
  231. Stacy ZA, Call WB, Hartmann AP, Peters GL, Richter SK. Edoxaban: A comprehensive review of the pharmacology and clinical data for the management of atrial fibrillation and venous thromboembolism. *Cardiol Ther* 2016; 5:1-18.
  232. Ansell J, Hirsh J, Hylek E, Jacobson A, Crowther M, Palareti G; American College of Chest Physicians. Pharmacology and management of the vitamin K antagonists: American College of Chest Physicians Evidence-Based Clinical Practice Guidelines (8th Edition). *Chest* 2008; 133:160S-198S.



233. Horlocker TT, Heit JA. Low molecular weight heparin: Biochemistry, pharmacology, perioperative prophylaxis regimens, and guidelines for regional anesthetic management. *Anesth Analg* 1997; 85:874-885.
234. Aursulesei V, Costache II. Anticoagulation in chronic kidney disease: from guidelines to clinical practice. *Clin Cardiol* 2019; 42:774-782.
235. Applefield D, Krishnan S. Protamine. [Updated 2023 Jan 8]. In: StatPearls [Internet]. Treasure Island (FL): StatPearls Publishing; 2023 Jan-.
236. Sokolowska E, Kalaska B, Miklosz J, Mogielnicki A. The toxicology of heparin reversal with protamine: past, present and future. *Expert Opin Drug Metab Toxicol* 2016; 12:897-909.
237. Kaye AD, Clarke RC, Sabar R, et al. Herbal medicines: current trends in anesthesiology practice--a hospital survey. *J Clin Anesth* 2000; 12:468-471.
238. Bajwa SJ, Panda A. Alternative medicine and anesthesia: Implications and considerations in daily practice. *Ayu* 2012; 33:475-480.
239. Uddin SA, Roma K, Ross L, et. al. Extensive spontaneous cervical epidural hematoma due to oral anticoagulant (dabigatran) successfully treated with reversal agent idarucizumab alone. *Surg Neurol Int* 2022; 13:259.
240. Srivastava KC. Evidence for the mechanism by which garlic inhibits platelet aggregation. *Prostaglandins Leukot Med* 1986; 22:313-321.
241. Rendu F, Daveloose D, Debouzy JC, et al. Ajoene, the antiplatelet compound derived from garlic, specifically inhibits platelet release reaction by affecting the plasma membrane internal microviscosity. *Biochem Pharmacol* 1989; 38:1321-1328.
242. Hatfield J, Saad S, Housewright C. Dietary supplements and bleeding. *Proc (Bayl Univ Med Cent)* 2022; 35:802-807.
243. Akintoye E, Sethi P, Harris WS, et al. Fish oil and perioperative bleeding: Insights from the OPERA randomized trial. *Circ Cardiovasc Qual Outcomes* 2018; 11:e004584.
244. Chen G, Qian ZM, Zhang J, et al. Regular use of fish oil supplements and course of cardiovascular diseases: prospective cohort study. *BMJ Med* 2024; 3:e000451.
245. Can Vitamin E cause bleeding? MEDSAFE, June 2022, Prescriber Update 43(2): 22-23. Accessed 2/6/2024. <https://www.medsafe.govt.nz/profs/PUArticles/June2022/Can-Vitamin-E-cause-bleeding.html>
246. Zeiss R, Connemann BJ, Schönfeldt-Lecuona C, Gahr M. Risk of bleeding associated with antidepressants: Impact of causality assessment and competition bias on signal detection. *Front Psychiatry* 2021; 12:727687.
247. Nochaiwong S, Ruengorn C, Awiphan R, et al. Use of serotonin reuptake inhibitor antidepressants and the risk of bleeding complications in patients on anticoagulant or antiplatelet agents: A systematic review and meta-analysis. *Ann Med* 2022; 54:80-97.
248. Pollack CV Jr, Reilly PA, Eikelboom J, et. al. Idarucizumab for Dabigatran Reversal. *N Engl J Med* 2015; 373:511-520.
249. U.S. Food and Drug Administration Package Insert. PRAXBIND® (idarucizumab) injection, for intravenous use, Initial U.S. Approval: 2015. Revised October 2015. Accessed 1/9/2024. [https://www.accessdata.fda.gov/drugsatfda\\_docs/label/2015/761025lbl.pdf](https://www.accessdata.fda.gov/drugsatfda_docs/label/2015/761025lbl.pdf)
250. U.S. Food and Drug Administration Package Insert. ANDEXXA® (coagulation factor Xa (recombinant), inactivated-zhzo) Lyophilized powder for solution for intravenous injection, Initial U.S. Approval: 2018. Revised May 2022. Accessed 1/9/2024 <https://www.fda.gov/media/113279/download>
251. Benz AP, Xu L, Eikelboom JW, et. al. Andexanet Alfa for Specific Anticoagulation Reversal in Patients with Acute Bleeding during Treatment with Edoxaban. *Thromb Haemost* 2022; 122:998-1005.
252. Connolly SJ, Crowther M, Eikelboom JW, et. al. Full Study Report of Andexanet Alfa for Bleeding Associated with Factor Xa Inhibitors. *N Engl J Med* 2019; 380:1326-1335.
253. Bradshaw PG, Keegan SP, Droegge ME, et. al. Reversal of apixaban and rivaroxaban with Andexanet alfa prior to invasive or surgical procedures. *Pharmacotherapy* 2022; 42:780-791.
254. Smetana KS, Counts J, Sodhi A, et. al. Review of target-specific anticoagulation reversal agents. *Crit Care Nurs Q* 2022; 45:180-188.
255. de Olano J, Howland MA, Su MK. Massive intentional enoxaparin overdose managed with minimal protamine: A single case report. *Am J Health Syst Pharm* 2023; 80:e98-e103.
256. Gorr HS, Lu LY, Hung E. Reversal of direct oral anticoagulants: Highlights from the Anticoagulation Forum guideline. *Cleve Clin J Med* 2021; 88:98-103.
257. Galhardo C Jr, Yamauchi LHI, Dantas H, et. al. Clinical protocols for oral anticoagulant reversal during high risk of bleeding for emergency surgical and nonsurgical settings: A narrative review. *Braz J Anesthesiol* 2021; 71:429-442.
258. Puelacher C, Lurati-Buse G, Singeisen H, Dang M, Cuculi F, Müller C. Perioperative myocardial infarction/injury after noncardiac surgery. *Swiss Med Wkly* 2015; 145:w14219.
259. Chassot PG, Delabays A, Spahn DR. Perioperative antiplatelet therapy: The case for continuing therapy in patients at risk of myocardial infarction. *Br J Anaesth* 2007; 99:316-328.
260. Dawood MM, Gutpa DK, Southern J, Walia A, Atkinson JB, Eagle KA. Pathology of fatal perioperative myocardial infarction: Implications regarding physiopathology and prevention. *Int J Cardiol* 1996; 57:37-44.
261. Landesberg G. The pathophysiology of perioperative myocardial infarction: Facts and perspectives. *J Cardiothorac Vasc Anesth* 2003; 17:90-100.
262. Priebe HJ. Triggers of perioperative myocardial ischaemia and infarction. *Br J Anaesth* 2004; 93:9-20.
263. Priebe HJ. Perioperative myocardial infarction—etiology and prevention. *Br J Anaesth* 2005; 95:3-19.
264. Hoffmeister HM, Heller W, Seipel L. Activation markers of coagulation and fibrinolysis: Alterations and predictive value in acute coronary syndrome. *Thromb Haemostasis* 1999; 82:76-79.
265. Blake GJ, Ridker PM. Inflammatory biomarkers and cardiovascular risk prediction. *J Intern Med* 2002; 252:283-294.
266. Biondi-Zoccai GG, Lotrionte M, Agostoni P, et al. A systematic review and meta-analysis on the hazards of discontinuing or not adhering to aspirin among 50,279 patients at risk for coronary artery disease. *Eur Heart J* 2006; 27:2667-2674.
267. Biber A. Pharmacokinetics of ginkgo biloba extracts. *Pharmacopsychiatry* 2003; 36:S32-S37.
268. Steib A, Hadjiat F, Skibba W, Steib JP, French Spine Surgery Society. Focus on perioperative management of anticoagulants and antiplatelet agents in spine surgery. *Orthop Traumatol Surg Res* 2011; 97:S102-S106.
269. Macellari F, Paciaroni M, Agnelli G,

- Caso V. Perioperative stroke risk in nonvascular surgery. *Cerebrovasc Dis* 2012; 34:175-181.
270. Antolovic D, Reissfelder C, Rakow A, et al. A randomised controlled trial to evaluate and optimize the use of antiplatelet agents in the perioperative management in patients undergoing general and abdominal surgery—the APAP trial (ISRCTN45810007). *BMC Surg* 2011; 11:7.
271. Chassot PG, Marcucci C, Delabays A, Spahn DR. Perioperative antiplatelet therapy. *Am Fam Physician* 2010; 82:1484-1489.
272. Korte W, Cattaneo M, Chassot PG, et al. Peri-operative management of antiplatelet therapy in patients with coronary artery disease: Joint position paper by members of the working group on Perioperative Haemostasis of the Society on Thrombosis and Haemostasis Research (GTH), the working group on Perioperative Coagulation of the Austrian Society for Anesthesiology, Resuscitation and Intensive Care (ÖGARI) and the Working Group Thrombosis of the European Society for Cardiology (ESC). *Thromb Haemost* 2011; 105:743-749.
273. Savonitto S, Caracciolo M, Cattaneo M, DE Servi S. Management of patients with recently implanted coronary stents on dual antiplatelet therapy who need to undergo major surgery. *J Thromb Haemost* 2011; 9:2133-2142.
274. Bell B, Layland J, Poon K, Spaulding C, Walters D. Focused clinical review: Periprocedural management of antiplatelet therapy in patients with coronary stents. *Heart Lung Circ* 2011; 20:438-445.
275. Tan VP, Yan BP, Kiernan TJ, Ajani AE. Risk and management of upper gastrointestinal bleeding associated with prolonged dual-antiplatelet therapy after percutaneous coronary intervention. *Cardiovasc Revasc Med* 2009; 10:36-44.
276. Grines CL, Bonow RO, Casey DE Jr, et al; American Heart Association; American College of Cardiology; Society for Cardiovascular Angiography and Interventions; American College of Surgeons; American Dental Association; American College of Physicians. Prevention of premature discontinuation of dual antiplatelet therapy in patients with coronary artery stents: A science advisory from the American Heart Association, American College of Cardiology, Society for Cardiovascular Angiography and Interventions, American College of Surgeons, and American Dental Association, with representation from the American College of Physicians. *J Am Dent Assoc* 2007; 138:652-655.
277. Chassot PG, Delabays A, Spahn DR. Perioperative use of anti-platelet drugs. *Best Pract Res Clin Anaesthesiol* 2007; 21:241-256.
278. Ray JG, Deniz S, Olivieri A, et al. Increased blood product use among coronary artery bypass patients prescribed preoperative aspirin and clopidogrel. *BMC Cardiovasc Disord* 2003; 3:3.
279. Michlig C, Vu DH, Wasserfallen JB, Spahn DR, Schneider P, Tissot JD. Three years of haemo-vigilance in a general university hospital. *Transfus Med* 2003; 13:63-72.
280. Kearon C, Hirsh J. Current concepts: Management of anticoagulation before and after elective surgery. *N Engl J Med* 1997; 336:1506-1511.
281. Vial JH, McLeod LJ, Roberts MS. Rebound elevation in urinary thromboxane B<sub>2</sub> and 6-keto-PGF<sub>1</sub> alpha exacerbation after aspirin withdrawal. *Adv Prostaglandin Thromboxane Leukot Res* 1991; 21A:157-160.
282. Weber AA, Braun M, Hohlfeld T, Schwippert B, Tschöpe D, Schrör K. Recovery of platelet function after discontinuation of clopidogrel treatment in healthy volunteers. *Br J Clin Pharmacol* 2001; 52:333-336.
283. Vilahur G, Choi BG, Zafar MU, et al. Normalization of platelet reactivity in clopidogrel-treated subjects. *J Thromb Haemost* 2007; 5:82-90.
284. Collet JP, Montalescot G, Blanchet B, et al. Impact of prior use or recent withdrawal of oral antiplatelet agents on acute coronary syndrome. *Circulation* 2004; 110:2361-2367.
285. Howard-Alpe GM, de Bono J, Hudsmith L, Orr WP, Foex P, Sear JW. Coronary artery stents and non-cardiac surgery. *Br J Anaesth* 2007; 98:560-574.
286. Sharma AK, Ajani AE, Hamwi SM, et al. Major noncardiac surgery following coronary stenting: When is it safe to operate? *Catheter Cardiovasc Interv* 2004; 63:141-145.
287. Iakovou I, Schmidt T, Bonizzi E, et al. Incidence, predictors, and outcome of thrombosis after successful implantation of drug eluting stents. *JAMA* 2005; 293:2126-2130.
288. Horlocker TT, Wedel DJ, Rowlingson JC, et al. Regional anesthesia in the patient receiving antithrombotic or thrombolytic therapy: American Society of Regional Anesthesia and Pain Medicine evidence-based guidelines (third edition). *Reg Anesth Pain Med* 2010; 35:64-101.
289. Horlocker TT, Wedel DJ, Schroeder DR, et al. Preoperative antiplatelet therapy does not increase the risk of spinal hematoma associated with regional anesthesia. *Anesth Analg* 1995; 80:303-309.
290. Horlocker TT, Wedel DJ, Offord KP. Does preoperative antiplatelet therapy increase the risk of hemorrhagic complications associated with regional anesthesia? *Anesth Analg* 1990; 70:631-634.
291. Wamala H, Scott IA, Caney X. Perioperative management of new oral anticoagulants in patients undergoing elective surgery at a tertiary hospital. *Intern Med J* 2017; 47:1412-1421.
292. Lum DJ, Ross PA, Bishop MA, Caetano ML, Malpani R, Streiff MB. Evaluation of a standardized perioperative management protocol in the adult hematology anticoagulation management service. *Ann Pharmacother* 2017; 51:1077-1083.
293. Sun MT, Wood MK, Chan W, et al. Risk of intraocular bleeding with novel oral anticoagulants compared with warfarin: A systematic review and meta-analysis. *JAMA Ophthalmol* 2017; 135:864-870.
294. Irizarry-Alvarado JM, Seim LA. Perioperative management of anticoagulants. *Curr Clin Pharmacol* 2017; 12:145-151.
295. Duranteau J, Taccone FS, Verhamme P, Agno W, ESAVTE Guidelines Task Force. European guidelines on perioperative venous thromboembolism prophylaxis: Intensive care. *Eur J Anaesthesiol* 2018; 35:142-146.
296. Khan H, Kumar V, Ghulam-Jelani Z, et al. Safety of spinal cord stimulation in patients who routinely use anticoagulants. *Pain Med* 2018; 19:1807-1812.
297. Childers CP, Maggard-Gibbons M, Ulloa JG, et al. Perioperative management of antiplatelet therapy in patients undergoing non-cardiac surgery following coronary stent placement: A systematic review. *Syst Rev* 2018; 7:4.
298. Sobieraj DM, Coleman CI, Pasupuleti V, Deshpande A, Kaw R, Hernandez AV. Comparative efficacy and safety of anticoagulants and aspirin for extended treatment of venous thromboembolism:

- A network meta-analysis. *Thromb Res* 2015; 135:888-896.
299. Akl EA, Kahale L, Terrenato I, et al. Oral anticoagulation in patients with cancer who have no therapeutic or prophylactic indication for anticoagulation. *Cochrane Database Syst Rev* 2014; 7:CD006466.
  300. Rollins BM, Silva MA, Donovan JL, Kanaan AO. Evaluation of oral anticoagulants for the extended treatment of venous thromboembolism using a mixed-treatment comparison, meta-analytic approach. *Clin Ther* 2014; 36:1454-1464.
  301. Hernandez I, Zhang Y, Saba S. Comparison of the effectiveness and safety of apixaban, dabigatran, rivaroxaban, and warfarin in newly diagnosed atrial fibrillation. *Am J Cardiol* 2017; 120:1813-1819.
  302. de Souza Brito F, Mehta RH, Lopes RD, et al. Nonsteroidal anti-inflammatory drugs and clinical outcomes in patients undergoing coronary artery bypass surgery. *Am J Med* 2017; 130:462-468.
  303. Hess PL, Kim S, Fonarow GC, et al; Outcomes Registry for Better Informed Treatment of Atrial Fibrillation (ORBIT-AF) Patients and Investigators. Absence of oral anticoagulation and subsequent outcomes among outpatients with atrial fibrillation. *Am J Med* 2017; 130:449-456.
  304. Dunn AS, Turpie AG. Perioperative management of patients receiving oral anticoagulants: A systematic review. *Arch Intern Med* 2003; 163:901-908.
  305. Ono S, Fujishiro M, Kanzaki H, et al. Conflicting clinical environment about the management of antithrombotic agents during the periendoscopic period in Japan. *J Gastroenterol Hepatol* 2011; 26:1434-1440.
  306. Ono S, Fujishiro M, Kodashima S, et al. Evaluation of safety of endoscopic biopsy without cessation of antithrombotic agents in Japan. *J Gastroenterol* 2012; 47:770-774.
  307. Stone DH, Goodney PP, Schanzer A, et al; Vascular Study Group of New England. Clopidogrel is not associated with major bleeding complications during peripheral arterial surgery. *J Vasc Surg* 2011; 54:779-784.
  308. Lip GY, Durrani OM, Roldan V, Lip PL, Marin F, Reuser TQ. Peri-operative management of ophthalmic patients taking antithrombotic therapy. *Int J Clin Pract* 2011; 65:361-371.
  309. Gerstein NS, Schulman PM, Gerstein WH, Petersen TR, Tawil I. Should more patients continue aspirin therapy perioperatively?: Clinical impact of aspirin withdrawal syndrome. *Ann Surg* 2012; 255:811-819.
  310. Law SK, Song BJ, Yu F, Kurbanyan K, Yang TA, Caprioli J. Hemorrhagic complications from glaucoma surgery in patients on anticoagulation therapy or antiplatelet therapy. *Am J Ophthalmol* 2008; 145:736-746.
  311. Lee LA, Posner KL, Kent CD, Domino KB. Complications associated with peripheral nerve blocks: Lessons from the ASA Closed Claims Project. *Int Anesthesiol Clin* 2011; 49:56-67.
  312. Lee LA, Posner KL, Domino KB, Caplan RA, Cheney FW. Injuries associated with regional anesthesia in the 1980s and 1990s: A closed claims analysis. *Anesthesiology* 2004; 101:143-152.
  313. Cook TM, Counsell D, Wildsmith JA; Royal College of Anaesthetists Third National Audit Project. Major complications of central neuraxial block: Report on the Third National Audit Project of the Royal College of Anaesthetists. *Br J Anaesth* 2009; 102:179-190.
  314. Tam NL, Pac-Soo C, Pretorius PM. Epidural haematoma after a combined spinal-epidural anaesthetic in a patient treated with clopidogrel and dalteparin. *Br J Anaesth* 2006; 96:262-265.
  315. Stafford-Smith M. Impaired haemostasis and regional anaesthesia. *Can J Anaesth* 1996; 43:R129-R141.
  316. Moen V, Dahlgren N, Irestedt L. Severe neurological complications after central neuraxial blockades in Sweden 1990-1999. *Anesthesiology* 2004; 101:950-959.
  317. Lee JH, Shin KS, Park SJ, et al. Comparison of clinical efficacy between transforaminal and interlaminar epidural injections in lumbosacral disc herniation: A systematic review and meta-analysis. *Pain Physician* 2018; 21:433-448.
  318. Lee JH, Kim DH, Kim DH, et al. Comparison of clinical efficacy of epidural injection with or without steroid in lumbosacral disc herniation: A systematic review and meta-analysis. *Pain Physician* 2018; 21:449-468.
  319. Manchikanti L, Benyamin RM, Falco FJ, Kaye AD, Hirsch JA. Do epidural injections provide short- and long-term relief for lumbar disc herniation? A systematic review. *Clin Orthop Relat Res* 2015; 473:1940-1956.
  320. Manchikanti L, Nampiaparampil DE, Manchikanti KN, et al. Comparison of the efficacy of saline, local anesthetics, and steroids in epidural and facet joint injections for the management of spinal pain: A systematic review of randomized controlled trials. *Surg Neurol Int* 2015; 6:S194-S235.
  321. Chan L, Bailin MT. Spinal epidural hematoma following central neuraxial blockade and subcutaneous enoxaparin: A case report. *J Clin Anesth* 2004; 16:382-385.
  322. Miller DC, Schneider BJ, McCormick ZL. Caution when withholding antithrombotic and antiplatelet agents for interventional spine procedures and the need for further risk stratification. *Pain Physician* 2019; 22:413-415.
  323. Ansari S, Heavner JE, McConnell DJ, et al. The peridural membrane of the spinal canal: A critical review. *Pain Pract* 2012; 12:315-325.
  324. Standring S. Macroscopic anatomy of the spinal cord and spinal nerves. In: *Gray's Anatomy: The Anatomical Basis of Clinical Practice*. 39th ed. Churchill Livingstone, London, UK, 2005, pp 775-788.
  325. Bowsler D. A comparative study of the azygous venous system in man, monkey, dog, cat, rat and rabbit. *J Anat* 1954; 88:400-406.
  326. Woollam DHM, Millen JW. The arterial supply of the spinal cord and its significance. *J Neurochem* 1955; 18:97-102.
  327. Nickalls RW, Kokri MS. The width of the posterior epidural space in obstetric patients. *Anaesthesia* 1986; 41:432-433.
  328. Cramer GD. The cervical region. In: Cramer GD, Darby SA, editors. *Basic and Clinical Anatomy of the Spine, Spinal Cord, and ANS*. 2nd ed. Elsevier, St. Louis, 2005, pp. 142-209.
  329. Lirk P, Kolbitsch C, Putz G, et al. Cervical and high thoracic ligamentum flavum frequently fails to fuse in the midline. *Anesthesiology* 2003; 99:1387-1390.
  330. Hogan QH. Epidural anatomy examined by cryomicrotome section. Influence of age, vertebral level, and disease. *Reg Anesth* 1996; 21:395-406.
  331. Joshi J, Roytman M, Aiyer R, Mauer E, Chazen JL. Cervical spine ligamentum flavum gaps: MR characterisation and implications for interlaminar epidural injection therapy. *Reg Anesth Pain Med* 2022; 47:459-463.
  332. Zaki SM. Study of the human ligamentum flavum in old age: A histological and morphometric study. *Folia Morphol (Warsz)* 2014; 73:492-499.
  333. Yoon SP, Kim HJ, Choi YS. Anatomic

- variations of cervical and high thoracic ligamentum flavum. *Korean J Pain* 2014; 27:321-325.
334. Schultz DM, Hagedorn JM, Abd-Elseyed A, Stayner S. Safety of interlaminar cervical epidural injections: Experience with 12,168 procedures in a single pain clinic. *Pain Physician* 2022; 25:49-58.
335. Manchikanti L, Malla Y, Cash KA, Pampati V. Do the gaps in the ligamentum flavum in the cervical spine translate into dural punctures? An analysis of 4,396 fluoroscopic interlaminar epidural injections. *Pain Physician* 2015; 18:259-266.
336. Reina MA, Franco CD, López A, Dé Andrés JA, van Zundert A. Clinical implications of epidural fat in the spinal canal. A scanning electron microscopic study. *Acta Anaesthesiol Belg* 2009; 60:7-17.
337. Breschet G. Anatomie: essai sur les veines du rachis. Mequignon-Marvis, Paris, France, 1819.
338. Batson OV. The function of the vertebral veins and their role in the spread of metastases. 1940. *Clin Orthop Relat Res* 1995; 312:4-9.
339. Groen RJ, Groenewegen HJ, van Alphen HA, Hoogland PV. Morphology of the human internal vertebral venous plexus: A cadaver study after intravenous Araldite CY 221 injection. *Anat Rec* 1997; 249:285-294.
340. Hogan QH. Lumbar epidural anatomy. A new look by cryomicrotome section. *Anesthesiology* 1991; 75:767-775.
341. Bernards CM. Sophistry in medicine: lessons from the epidural space. *Reg Anesth Pain Med* 2005; 30:56-66.
342. Meijenhorst GC. Computed tomography of the lumbar epidural veins. *Radiology* 1982; 145:687-691.
343. Igarashi T, Hirabayashi Y, Shimizu R, Saitoh K, Fukuda H, Mitsuhashi H. The lumbar extradural structure changes with increasing age. *Br J Anaesth* 1997; 78:149-152.
344. Kreppel D, Antoniadis G, Seeling W. Spinal hematoma: a literature survey with meta-analysis of 613 patients. *Neurosurg Rev* 2003; 26:1-49.
345. Igarashi T, Hirabayashi Y, Shimizu R, et al. Inflammatory changes after extradural anaesthesia may affect the spread of local anaesthetic within the extradural space. *Br J Anaesth* 1996; 77:347-351.
346. Uribe J, Moza K, Jimenez O, Green B, Levi AD. Delayed postoperative spinal epidural hematomas. *Spine J* 2003; 3:125-129.
347. Huntoon MA. The vertebral artery is unlikely to be the sole source of vascular complications occurring during stellate ganglion block. *Pain Pract* 2010; 10:25-30.
348. Okuda Y, Urabe K, Kitajima T. Retropharyngeal or cervicomedial haematomas following stellate ganglion block. *Eur J Anaesthesiol* 2003; 20:757-759.
349. Higa K, Hirata K, Hirota K, Nitahara K, Shono S. Retropharyngeal hematoma after stellate ganglion block: Analysis of 27 patients reported in the literature. *Anesthesiology* 2006; 105:1238-1245; discussion 5A-6A.
350. Narouze S. Beware of the "serpentine" inferior thyroid artery while performing stellate ganglion block. *Anesth Analg* 2009; 109:289-290.
351. Mehta SR, Baione KR, Cantor WJ, et al; members of the Secondary Panel. 2018 Canadian Cardiovascular Society/Canadian Association of Interventional Cardiology Focused Update of the Guidelines for the Use of Antiplatelet Therapy. *Can J Cardiol* 2018; 34:214-233.
352. Albaladejo P, Bonhomme F, Blais N, et al. Management of direct oral anticoagulants in patients undergoing elective surgeries and invasive procedures: updated guidelines from the French Working group on Perioperative Hemostasis (GIHP) - September 2015. *Anaesth Crit Care Pain Med* 2017; 36:73-76.
353. Douketis JD, Spyropoulos AC, Spencer FA, et al. Perioperative management of antithrombotic therapy: antithrombotic therapy and prevention of thrombosis, 9th ed: American College of Chest Physicians evidence-based clinical practice guidelines. *Chest* 2012; 141:e326S-e350S.
354. Spyropoulos AC, Al-Badri A, Sherwood MW, Douketis JD. Perioperative Management of Patients on a vitamin K antagonist or a direct oral anticoagulant requiring an elective procedure or surgery. *J Thromb Haemost* 2016; 14:875-885.
355. Tafur A, Douketis JD. Perioperative anticoagulant management in patients with atrial fibrillation: practical implications of recent clinical trials. *Pol Arch Med Wewn* 2015; 125:666-671.
356. Statman BJ. Perioperative management of oral antithrombotics in dentistry and oral surgery: Part 2. *Anesth Prog* 2023; 70:37-48.
357. Patrono C, Ciabattini G, Patrignani P, et al. Clinical pharmacology of platelet cyclooxygenase inhibition. *Circulation* 1985; 72:1177-1184.
358. Patrono C, Ciabattini G, Pinca E, et al. Low dose aspirin and inhibition of thromboxane B2 production in healthy subjects. *Thromb Res* 1980; 17: 317-327.
359. Patrignani P, Filabozzi P, Patrono C. Selective cumulative inhibition of platelet thromboxane production by low-dose aspirin in healthy subjects. *J Clin Invest* 1982; 69:1366-1372.
360. Chaer RA, Graham JA, Mureebe L. Platelet function and pharmacologic inhibition. *Vasc Endovascular Surg* 2006; 40:261-267.
361. Najean Y, Ardaillou N, Dresch C. Platelet lifespan. *Annu Rev Med* 1969; 20:47-62.
362. Rocca B, Santilli F, Pitocco D, et al. The recovery of platelet cyclooxygenase activity explains interindividual variability in responsiveness to low-dose aspirin in patients with and without diabetes. *J Thromb Haemost* 2012; 10:1220-1230.
363. Jimenez AH, Stubbs ME, Tofler GH, Winther K, Williams GH, Muller JE. Rapidity and duration of platelet suppression by enteric-coated aspirin in healthy young men. *Am J Cardiol* 1992; 69:258-262.
364. Zisman E, Erport A, Kohanovsky E, et al. Platelet function recovery after cessation of aspirin: preliminary study of volunteers and surgical patients. *Eur J Anaesthesiol* 2010; 27:617-623.
365. Kim C, Pfeiffer ML, Chang JR, Burnstine MA. Perioperative considerations for antithrombotic therapy in ophthalmic surgery: A review of current evidence and practice guidelines. *Ophthalmic Plast Reconstr Surg* 2022; 38:226-233.
366. Gorog DA, Sweeny JM, Fuster V. Antiplatelet drug 'resistance'. Part 2: laboratory resistance to antiplatelet drugs—fact or artifact? *Nat Rev Cardiol* 2009; 6:365-373.
367. Notarangelo MF, Bontardelli F, Merlini PA. Genetic and nongenetic factors influencing the response to clopidogrel. *J Cardiovasc Med (Hagerstown)* 2013; 14:S1-S7.
368. Kreutz RP, Owens J, Jin Y, et al. Cytochrome P450 3A4\*22, PPAR- $\alpha$ , and ARNT polymorphisms and clopidogrel response. *Clin Pharmacol* 2013; 5:185-192.
369. Capodanno D, Ferreiro JL, Angiolillo DJ. Antiplatelet therapy: new pharmacological agents and changing paradigms. *J Thromb Haemost* 2013;

- 11:316-329.
370. Brandt JT, Payne CD, Wiviott SD, et al. A comparison of prasugrel and clopidogrel loading doses on platelet function: magnitude of platelet inhibition is related to active metabolite formation. *Am Heart J* 2007; 153:e9-e16
371. Rahman AA, Platt RW, Beradid S, Boivin JF, Rej S, Renoux C. Concomitant use of selective serotonin reuptake inhibitors with oral anticoagulants and risk of major bleeding. *JAMA Netw Open* 2024; 7:e243208.
372. Sawaya C, Sawaya R. Central nervous system bleeding after a lumbar puncture: Still an ongoing complication. *Am J Case Rep* 2018; 19:1103-1107.
373. De Cassai A, Correale C, Sandei L. Neuraxial and perineural bleeding after neuraxial techniques: an overview of the last year. *Eurasian J Med* 2020; 52:211-216.
374. Khan TW, Yacoub A. Pitfalls in interventional pain medicine: Hyponatremia after DDAVP for a patient with Von Willebrand Disease undergoing an epidural steroid injection. *Case Rep Anesthesiol* 2017; 2017:6467090.
375. Zhang B, Chen J, Zou N, et al. Spontaneous resolution and complete recovery of spontaneous cervical epidural hematoma: Report of two cases and literature review. *Neurochirurgie* 2019; 65:27-31.
376. Teles P, Correia JP, Pappamikail L, et al. A spontaneous cervical epidural hematoma mimicking a stroke - A case report. *Surg Neurol Int* 2020; 11:1157.
377. Emamhadi M, Ghadarjani S, Alijani B, et al. Spontaneous cervical epidural hematoma with stroke manifestations. *Asian J Neurosurg* 2019; 14:286-288.
378. Mohamed EH, Dsouza LB, Elnabawy WA, Bashir K, Elmoheen A. Acute spinal extradural hematoma and cord compression: Case report and a literature review. *Cureus* 2020; 12:e11603.
379. Lenzer J. Anticoagulants cause the most serious adverse events, finds US analysis. *BMJ* 2012;344:e3989.
380. Yoo HS, Park SW, Han JH, et al. Paraplegia caused by an epidural hematoma in a patient with unrecognized chronic idiopathic thrombocytopenic purpura following an epidural steroid injection. *Spine (Phila Pa 1976)* 2009; 34:E376-E379.
381. Furman MB, Bernstein J, McCormick ZL, et al. Concerns regarding 'Interventional spine and pain procedures in patients on antiplatelet and anticoagulant medications (second edition)'. *Reg Anesth Pain Med* 2019; 44:416-417.
382. Oprea AD, Noto CJ, Halaszynski TM. Risk stratification, perioperative and periprocedural management of the patient receiving anticoagulant therapy. *J Clin Anesth* 2016; 34:586-599.
383. Carrier M, Le Gal G, Wells PS, Rodger MA. Systematic review: Case-fatality rates of recurrent venous thromboembolism and major bleeding events among patients treated for venous thromboembolism. *Ann Intern Med* 2010;152:578-589.
384. Moster M, Bolliger D. Perioperative guidelines on antiplatelet and anticoagulant agents: 2022 update. *Curr Anesthesiol Rep* 2022; 12:286-296.
385. Siegal D, Yudin J, Kaatz S, Douketis JD, Lim W, Spyropoulos AC. Periprocedural heparin bridging in patients receiving vitamin K antagonists: Systematic review and meta-analysis of bleeding and thromboembolic rates. *Circulation* 2012; 126:1630-1639.
386. Douketis JD, Spyropoulos AC, Kaatz S, et al; BRIDGE Investigators. Perioperative bridging anticoagulation in patients with atrial fibrillation. *N Engl J Med* 2015; 373:823-833.
387. Kovacs MJ, Wells PS, Anderson DR, et al; PERIOP2 Investigators. Postoperative low molecular weight heparin bridging treatment for patients at high risk of arterial thromboembolism (PERIOP2): Double blind randomised controlled trial. *BMJ* 2021; 373:n1205.
388. Nikolakopoulos I, Spyropoulos AC. Heparin bridging therapy for patients on chronic oral anticoagulants in periprocedural settings. *Semin Thromb Hemost.* 2020; 46:26-31.
389. Micheletta F, Ferrara M, Bertozzi G, Volonnino G, Nasso M, La Russa R. Proactive Risk Assessment through Failure Mode and Effect Analysis (FMEA) for perioperative management model of oral anticoagulant therapy: A pilot project. *Int J Environ Res Public Health* 2022; 19:16430.
390. Aldhaeefi M, Badreldin HA, Alsuwayyid F, et al. Practical guide for anticoagulant and antiplatelet reversal in clinical practice. *Pharmacy (Basel)* 2023; 11:34.
391. Bonhomme F, Grape S. Periprocedural management of oral anticoagulation - Limit the bleeding risk in elective procedures. *Rev Med Suisse* 2022; 18:2323-2326.
392. Shah S, Urtecho M, Firwana M, et al. Perioperative management of antiplatelet therapy: A systematic review and meta-analysis. *Mayo Clin Proc Innov Qual Outcomes* 2022; 6:564-573.
393. Taylor J, Stiepel HR 3rd, Keefe N. Anticoagulation and antiplatelet agents in peripheral arterial interventions. *Semin Intervent Radiol* 2022; 39:364-372.
394. Boccata A, Frisone A, Lorusso F, et al. Perioperative management of antithrombotic therapy in patients who undergo dental procedures: A systematic review of the literature and network meta-analysis. *Int J Environ Res Public Health* 2023; 20:5293.
395. Lauerma P, Klingelhöfer A, Mielke D, et al. Risk Factors for severe bleeding complications in glaucoma surgery and the role of antiplatelet or anticoagulant agents. *Clin Ophthalmol* 2022; 16:1245-1254.
396. Cao D, Amabile N, Chiarito M, et al. Reversal and removal of oral antithrombotic drugs in patients with active or perceived imminent bleeding. *Eur Heart J* 2023; 44:1780-1794.
397. De Luca L, Pugliese FR, Susi B, et al. ANMCO/SIMEU Consensus document on the use of reversal agents of antithrombotic therapies in patients with active bleeding or at high-risk of major bleeding events. *G Ital Cardiol (Rome)* 2024; 25:60-69.
398. Chandan S, Desai A, Dahiya DS, et al. Risk of post-sphincterotomy bleeding with antiplatelet and anticoagulant use: a propensity-matched analysis of the U.S. Collaborative Network. *Gastrointest Endosc* 2023; 97:1129-1136.
399. Nash M, Bloch S, Golan D. Safety of lumbar puncture for people who are treated with ADP receptor antagonists. *J Neurol* 2023; 270:3052-3057.
400. Hsieh HT, Chou HJ, Wu PY, Lin SK. Bleeding risk after acupuncture in patients taking anticoagulant drugs: A case control study based on real-world data. *Complement Ther Med* 2023; 74:102951.
401. Shah HP, Reeder A, Rohrbaugh T, Kohli N. Assessing the safety of continued perioperative antithrombotic therapy in endoscopic airway surgery for laryngotracheal stenosis. *Am J Otolaryngol* 2023; 44:103857.
402. McCrum C, Furner R, Grainger S. Peri-procedural management and incidence of bleeding events following musculoskeletal injections or aspirations in people on oral anticoagulation and antiplatelet therapy. *Musculoskeletal Care* 2023; 21:702-712.

403. Li YK, Guo CG, Cheung KS, Liu KSH, Leung WK. Risk of Postcolonoscopy thromboembolic events: A real-world cohort study. *Clin Gastroenterol Hepatol* 2023; 21:3051-3059.
404. Kennedy MM, Abdel-Aty Y, Butterfield R, Zhang N, Lott DG. Is continued perioperative antithrombotic therapy safe when performing open tracheostomy? *Ann Otol Rhinol Laryngol* 2023; 132:1285-1292.
405. Amaraneni A, Chippa V, Rettew AC. Anticoagulation Safety. 2023 Apr 17. In: *StatPearls [Internet]*. Treasure Island (FL): StatPearls Publishing; 2024 Jan-.
406. Vivas D, Anguita-Gámez M, Ferrandis R, et al; REQXAA study investigators. Prospective observational registry of perioperative and periprocedural management of antithrombotic therapy in "real world": The REQXAA study. *Rev Esp Cardiol (Engl Ed)* 2023; 76:729-738.
407. Cruz Silva J, Constâncio V, Lima P, Anacleto G, Fonseca M. Effect of chronic antiplatelet and anticoagulant medication in neck hematoma and perioperative outcomes after carotid endarterectomy. *Ann Vasc Surg* 2023; 88:199-209.
408. Loving VA, Johnston BS, Reddy DH, et al. Antithrombotic therapy and hematoma risk during image-guided core-needle breast biopsy. *Radiology* 2023; 306:79-86.
409. Visonà A, Zurlo C, Panzavolta C, Gobbo A, Zalunardo B. Bleeding risk in patients with peripheral arterial disease. *Life (Basel)* 2022; 13:47.
410. Dean KR, Pavuluri H, Fox S, et al. The impact of antithrombotic medications on postoperative bleeding events following hemorrhoidectomy. *Am Surg* 2023; 89:4610-4615.
411. Gnanapandithan K, Muniraj T. Management of Antithrombotics Around Gastrointestinal Procedures. 2023 Mar 13. In: *StatPearls [Internet]*. Treasure Island (FL): StatPearls Publishing; 2024 Jan-.
412. Polania Gutierrez JJ, Rocuts KR. Perioperative Anticoagulation Management. 2023 Jan 23. In: *StatPearls [Internet]*. Treasure Island (FL): StatPearls Publishing; 2024 Jan-.

Appendix Table 1. Reports of bleeding complications and epidural hematoma associated without antithrombotic therapy with interventional procedures.

Study/Year	Case Report	Conclusions
<b>CERVICAL EPIDURAL</b>		
Ghaly, 2001 (135)  Cervical epidural hematoma  Cervical interlaminar epidural	A 56-year-old man who developed Brown-Séquard syndrome from a spinal epidural hematoma after fluoroscopically-guided cervical steroid injection. The patient reported immediate sharp shooting pain in the upper extremities on introduction of epidural Tuohy needle. Within half an hour, a neurological deficit occurred at C7/8 and right Brown-Séquard syndrome developed. MRI showed C6 to T2 spinal epidural hematoma with cord compression. Emergency spinal bilateral decompressive laminectomies and evacuation of spinal hematoma were performed within an expected delay of 10 hours from the onset of neurological deficit from C6 to T12.	Patient developed epidural hematoma without any risk factors or anticoagulant therapy. This case shows Brown-Séquard syndrome can be a presenting finding in cervical hematoma.
Stoll & Sanchez, 2002 (137)  Cervical epidural hematoma  Cervical interlaminar epidural	A healthy 34-year-old man with no evidence of coagulopathy and not taking antiplatelet medication suddenly had onset of acute cervical myelopathy from a large cervical epidural hematoma 8 days after cervical epidural steroid injection. The patient developed a Brown-Séquard type of myelopathy manifesting by severe weakness of the left arm and leg and right-sided numbness and loss of temperature appreciation. The diagnosis was made by CT scan. Following prompt surgical evaluation of the clot, the patient made a near complete recovery.	The authors concluded that this case illustrated that epidural hematoma may occur in the absence of known risk factors. The delayed onset and the absence of risk factors have implications for the use of epidural steroid injection in chronic pain management. The delayed onset can be clinically confusing, requiring the clinician to keep this issue on the differential diagnosis in the perioperative period.
Kim & Park, 2015 (155)  Intracranial chronic subdural hematoma  Cervical interlaminar epidural injection	A 39-year-old female underwent cervical epidural injection at C6 under fluoroscopic guidance. Five days after epidural injection she complained of a mild headache that was increasing in the upright position with a normal CT scan. At this time, she was treated with conservative management for a post dural puncture headache. One month later, she presented with a severe headache that was not relieved by analgesic medication, which changed in character from being positional to non-positional during the preceding month. Brain MRI revealed a chronic subdural hematoma along the left convexity. Emergency Burr Hole drainage was performed, and the headache abated.	This report indicated that an intracranial chronic subdural hematoma presenting with intractable headache after cervical epidural steroid injection should be considered a possible complication. In addition, the event of an intractable and changing post dural puncture headache after epidural injection suggests further evaluation for diagnosis of an intracranial hematoma. This is a very rare event.
Swicegood et al, 2017 (66)  Cervical epidural hematoma  Cervical interlaminar epidural injection	Authors reported a cervical epidural hematoma in a 41-year-old Caucasian female with controlled hypertension, but with no drug therapy contributing to bleeding. She received uneventful epidural injection and developed neurological dysfunction necessitating surgical decompression. She recovered without residual dysfunction.	Epidural hematoma developed in a patient without antiplatelet or anticoagulant therapy. Authors described this case of epidural hematoma in a patient with no risk factors or anticoagulant or antiplatelet therapy. This case highlights the need for vigilance in the setting of low bleeding risks.
Manchikanti et al, 2017 (68)  Cervical epidural hematoma  Cervical interlaminar epidural injection	Authors reported a case of a 61-year-old female without risk factors or anticoagulant therapy. Epidural injection was performed in the cervical spine without difficulty. Patient developed symptomatology leading to the diagnosis of cervical epidural hematoma within 3 hours after the procedure undergoing surgical intervention due to progressive neurological dysfunction.	Epidural hematoma occurred after the recommended period to discontinue aspirin. This patient had no other risk factors or other anticoagulant therapy. Patient was also successfully managed conservatively without surgical intervention. Patient developed epidural hematoma without any risk factors or anticoagulant therapy. The risks of residual effects of aspirin must be considered, and if discontinued, proper timelines should be followed.
Manchikanti et al, 2018 (70)  Cervical epidural hematoma  Cervical interlaminar epidural injection	Cervical epidural hematoma was reported in a healthy 43-year-old functioning female patient without overt risk factors for procedural hemorrhagic complications including baseline coagulopathy, baseline dysfunction, and intake of anticoagulants. There were no technical difficulties in performing the procedure. Patient developed symptomatology leading to the diagnosis of cervical and thoracic epidural hematoma with progressive neurological dysfunction necessitating surgical decompression.	Authors concluded that epidural hematoma may happen in cervical epidural injections considered as high-risk procedure without antiplatelet or anticoagulant therapy and without any risk factors. Preprocedural patient education is critical for identifying neurological signs of a hematoma.

Appendix Table 1 cont. *Reports of bleeding complications and epidural hematoma associated without antithrombotic therapy with interventional procedures.*

Study/Year	Case Report	Conclusions
<p>Banik &amp; Chen Chen, 2019 (187)</p> <p>Cervical epidural hematoma</p> <p>Cervical interlaminar epidural</p>	<p>An 80-year-old woman with epidural hematoma after C7–T1 epidural injection performed under moderate sedation. Thirty minutes after the procedure, she developed acute onset of neck pain, which progressed shortly to numbness down to her mid-sternum, 0/5 strengths in the bilateral elbows, wrists, and lower extremities, and loss of patellar reflexes. CT images taken ~3h after the onset of symptoms was notable in a sagittal image for hyperdense collection of blood within the spinal canal extending from C2–T4, and a cross-sectional view at the level of C7, which shows a biconvex-shaped hyperdense lesion within the spinal canal suggestive of epidural hematoma. The patient's localized neck pain, quadriplegia, loss of reflexes, numbness, sudden onset of symptoms, and computed tomography findings are characteristic of acute cord compression.</p>	<p>Another case of cervical epidural hematoma in an 80-year-old woman performed at C7/T1 resulted in cord compromise. There was no anticoagulant therapy.</p>
<p>Palmer, 2020 (188)</p> <p>Two cases of cervical epidural hematoma</p> <p>Cervical interlaminar epidural</p>	<p>Two cases of cervical epidural hematoma a, both in otherwise healthy patients with no apparent risk factors, that occurred after cervical epidural steroid injections. Both cases presented nearly identically with severe localized pain at the injection site. One required urgent surgical decompression, and the other was managed conservatively.</p>	<p>Case report with 2 occurrences of cervical epidural hematoma cases in patients without anticoagulant or antiplatelet therapy. These reports again indicate the need for vigilance and also appropriate evaluation of anatomic and technical risk factors.</p>
<p>Aljuboori &amp; Williams, 2021 (170)</p> <p>Chronic liquefied hematoma</p> <p>Cervical interlaminar epidural injection</p>	<p>A 38-year-old female underwent a cervical epidural steroid injection for neck pain. Four years later, age 42, the patient presented with a recurrent quadriplegia attributed to a cervical MRI-documented C3–C6 intramedullary cyst lesion, identified to be a chronic liquefied hematoma. Direct surgical decompression resulted in neurological improvement</p>	<p>Delayed chronic spinal cord intramedullary hematomas can develop, as in this case, up to 4 years following cervical epidural steroid injection. Of course, there is no way to directly correlate the injection to the complication, so a cause/effect relationship is not certain.</p>
<p>Dehaene et al, 2021 (173)</p> <p>Subdural hematoma</p> <p>Cervical interlaminar epidural injection</p>	<p>A female in her early 50s, with normal standard coagulation test results, received cervical epidural corticosteroid injections at C6 and C7 for her cervicobrachialgia syndrome. Three days after the second infiltration, she developed a post-dural puncture headache, and on day 16, a bilateral subdural hematoma was visualized on CT scan. Complete resorption of the hematoma was seen on day 25 without surgical intervention.</p>	<p>A post-dural puncture headache after any type of procedure can evolve into a subdural hematoma. A subdural hematoma should be considered if the headache changes in character, does not respond to treatment, or there are neurological signs such as nausea/vomiting and blurred vision.</p>
<p>Lee et al, 2007 (147)</p> <p>Cervical epidural hematoma</p> <p>Cervical transforaminal epidural</p>	<p>A healthy 38-year-old woman underwent a series of right transforaminal epidural injections at the C7-T1 level. Approximately 4 days after the final injection, she awakened with severe upper thoracic pain and progressive loss of sensation in the lower extremities. MRI of the spine showed a large hematoma extending from T1 to T5. The patient underwent surgical decompression. Within 6 months the patient regained full strength and sensation in both lower extremities.</p> <p>The authors cautioned that the physician should be aware that symptoms from a slowly developing epidural hematoma can present even days after an injection. In addition, the physician should be aware of the special risk circumstances of cervical transforaminal procedures.</p>	<p>However, it is one of the only case report in this category. The procedural images were not provided, and it does not appear the authors were proceduralists. One of the guideline authors (BJS) believes that given how extremely rare a C7-T1 transforaminal epidural steroid injection is, there is reasonable uncertainty that this was in fact a transforaminal epidural steroid injection despite what was reported a C7-T1 interlaminar epidural steroid injection would be much more likely. It is difficult to confirm the veracity of this case report</p>
<b>LUMBAR EPIDURAL</b>		
<p>Ozdemir et al, 2007 (145)</p> <p>Right interlaminar front subdural hematoma</p> <p>Lumbar epidural injection</p>	<p>Epidural steroid injection was performed with an #18-gauge Tuohy needle which revealed a dural puncture in a 40-year-old male. The second attempt at L3/4 level was successful. MRI showed a right frontal subdural hematoma. His headache was relieved after strict bedrest, intravenous hydration, and analgesics. The patient was discharged with full recovery after one week without neurological dysfunction.</p>	<p>The authors concluded that intracranial subdural hematoma for accidental dural puncture during epidural steroid injection is a rare complication, even though there were no risk factors in this patient. This can also be associated with intrathecal catheters.</p>



Appendix Table 1 cont. *Reports of bleeding complications and epidural hematoma associated without antithrombotic therapy with interventional procedures.*

Study/Year	Case Report	Conclusions
Platt et al, 2020 (177)  Lumbar pseudo-subarachnoid hemorrhage  Lumbar interlaminar epidural L4-5	A 73-year-old female underwent a lumbar epidural steroid injection, with a gadolinium-based contrast agent injected at the L4-5 level for epidural localization. The procedure was complicated by a dural puncture with possible intrathecal contrast injection. One day later, she experienced altered mental status. An MRI diagnosed pseudo-subarachnoid hemorrhage and gadolinium encephalopathy. The patient was discharged after 6 days to a subacute rehabilitation center without neurologic deficit.	The combination of the neurologic symptoms related to gadolinium encephalopathy and the radiographic findings of pseudo-subarachnoid hemorrhage can create a clinical presentation nearly identical to ruptured aneurysmal subarachnoid hemorrhage. Gadolinium has a very specific set of risks when used intrathecally and the use of this medium should be approached with caution.
Desai & Dua, 2014 (132)  Lumbar epidural hematoma  Lumbar transforaminal epidural (foraminal)	This is a case report of a 72-year-old female undergoing right transforaminal epidural injection at L3 and L4. Four days after the injection the patient reported progressive right lower extremity weakness, worsening sensory loss, and ambulatory dysfunction. An MRI with gadolinium enhancement showed a focal abnormal signal with involvement of the right L4-5 neuroforamina that extended slightly far laterally, consistent with a small hematoma, affecting L4 nerve root. There was no history of coagulopathy.	This case report shows that though extremely rare, perineural or foraminal hematoma may occur as a serious complication of transforaminal epidural injection, even in the setting of a standardized procedure. This brings attention to a rare, but important complication.  However, this is not truly an interlaminar epidural hematoma, a foraminal hematoma is a much different risk as it only affects the isolated nerve root and does not result in paraplegia – this difference in anatomy is likely why there are less reports of true epidural hematoma following transforaminal epidural steroid injection compared to interlaminar epidural steroid injection.
Gungor & Aiyer, 2017 (205)  Lumbar epidural hematoma  Lumbar transforaminal epidural	This case report presents the development of epidural hematoma after lumbar transforaminal epidural steroid injection in a patient who has anatomical risk factor of severe lumbar spinal stenosis. The anatomic location of epidural hematoma was at the injected level, but on the contralateral side of the dura at a distance from the needle path. Epidural vascular anatomy and the potential mechanisms of bleeding in the epidural space in the absence of direct needle trauma, including the importance of injection pressures are discussed.	This is the first reported case of an epidural hematoma on the contralateral side of the dura at a distance from the needle tip location, in the setting of severe central canal stenosis.  There was no anticoagulant or antiplatelet therapy involved.  There is no reasonable pathophysiologic explanation for this to suspect the injection was related to the contralateral hematoma – the bleeding would not have crossed the midline and pass through the epidural space and then collect in the contralateral foramen. For this case report of bleed after transforaminal epidural steroid injection the details are open to discussion or controversy.
Lee et al, 2018 (175)  Iatrogenic hemorrhagic cyst  Lumbar transforaminal epidural	A 79-year-old female received 3 trials of transforaminal steroid injection between the right L5 and S1 vertebrae within a one-month period. One day after the last injection, she was suffering from severe pain, paresthesia, and weakness in the right lower extremity. A cyst found in the right epidural area in L5 was discovered to be compressing the thecal sac and L5 nerve root, diagnosed as an iatrogenic hemorrhagic ganglion cyst due to injection with a needle. It was treated surgically.	Authors report a rare case where an asymptomatic juxtafacet cyst progressed to an iatrogenic hemorrhagic cyst as a result of epidural steroid injection, with supplemental neurologic symptoms. This case also questions the medical necessity of the “series of three”.  Thus, with a transforaminal epidural steroid injection case report, this is not actually an epidural hematoma (if it was contained in a cyst it is much more likely they incidentally violated the facet capsule during the procedure), nonetheless this is not the same bleeding complication as a true epidural hematoma. Hence, removed from epidural hematoma count.

Appendix Table 1 cont. *Reports of bleeding complications and epidural hematoma associated without antithrombotic therapy with interventional procedures.*

Study/Year	Case Report	Conclusions
<p>Kim et al, 2019 (174)</p> <p>Epidural hematoma over thecal sac from T12-L1</p> <p>Lumbar transforaminal epidural</p>	<p>An 82-year-old male with spinal stenosis, not taking any anticoagulant or antiplatelet drugs, was treated with transforaminal epidural steroid injection in the right intervertebral foramen at the L2-L3 level. The next morning, he underwent emergency MRI due to severe right lower back pain and bilateral diffuse lower extremity motor deficit. Surgical evacuation was performed that evening for a rubbery, hard, clotted hematoma over the thecal sac from T12 to L1. Two weeks later, the patient was discharged without any other symptoms.</p> <p>As with other transforaminal epidural steroid injection case reports, this raises multiple issues if the blood originated at the L2-3 segment from the injection, the hematoma did not involve that spinal segment, it would be very unlikely for all of the blood to “travel” the T12-L1 and not have any hematoma at L2-3. Only plausible explanation is that in this case the patient simply had an injection then co-incidentally had a spontaneous epidural hematoma (or something related to pressure dynamics)</p>	<p>The reason for the epidural hematoma could theoretically be due to increased intra-epidural pressure and can occur without risk factors such as anticoagulant drugs. Age is an unknown co-variable variable. Direct vascular puncture due to foraminal entry cannot be ruled out.</p>
<b>KYPHOPLASTY</b>		
<p>Nogami et al, 2022 (176)</p> <p>Thoracic intradural hematoma</p> <p>Percutaneous kyphoplasty T12 and L1 level</p>	<p>An 80-year-old man underwent percutaneous kyphoplasty after a fall, for osteoporotic vertebral fracture at the T12 and L1 level. On the second day after kyphoplasty, he developed paralysis of the lower limbs, with complete loss of sensation below T11 and complete paralysis of both lower extremities. Thoracolumbar MRI revealed an intradural hematoma on the ventral side of the spinal cord, in the spinal canal from T5 to T12, compressing the spinal cord. An emergency posterior decompression from T11 to L1 was performed and the subarachnoid hematomas were removed.</p>	<p>Despite having a low risk of complications, percutaneous balloon kyphoplasty through the pedicle may cause hematoma and bone cement leakage into the spinal canal. This should be part of the informed consent.</p>
<b>PERCUTANEOUS EPIDURAL NEUROPLASTY</b>		
<p>Kim et al, 2023 (198)</p> <p>Lumbar epidural hematoma</p> <p>Percutaneous epidural neuroplasty</p>	<p>An 81-year-old female patient who was admitted in the nursing hospital due to dementia was transferred to our emergency room with paraplegia. She had no comorbidities other than dementia.</p> <p>Five days prior to transfer, she had undergone percutaneous epidural neuroplasty at another hospital due to persistent radiating pain and numbness in both legs caused by multiple level lumbar spinal stenosis. She walked independently before the procedure and was discharged to the nursing hospital on the same day as the percutaneous epidural neuroplasty. At our ER, her vital signs were stable. On neurological examination, muscle strength of lower extremities below hip flexion was confirmed as grade 0. Urinary incontinence was identified, and anal tone was decreased. All deep tendon reflexes of both lower extremities were absent. The evaluation for sensory change could not be clearly confirmed due to severe dementia.</p>	<p>In this case, the patient presented to the ER five days after the percutaneous epidural neuroplasty procedure. In some cases, the cause of spinal epidural hematoma is not clearly confirmed, and there is a considerable gap between the procedure and the time of symptom identification, so it may be difficult to conclude that percutaneous epidural neuroplasty caused the hematoma in this case. However, considering the pattern of the hematoma identified during surgery and the condition of the patient who had difficulty expressing symptoms, it is assumed that the hematoma that occurred after percutaneous epidural neuroplasty progressed. Although surgery was performed as soon as the diagnosis was made, delays in identifying the symptoms resulted in poor outcomes. This implies that when complications occur, rapid diagnosis and treatment are required. However, there are multiple variables to consider.</p>
<b>SPINAL CORD STIMULATION</b>		
<p>Takawira et al, 2012 (156)</p> <p>Cervical to lumbar (C7 to L3) epidural hematoma</p> <p>Spinal cord stimulation trial</p>	<p>A 52-year-old male patient underwent spinal cord trial stimulation placement from T8 through T10 levels bilaterally with epidural entry at T12 and L1 interspace. 72 hours after the placement with good pain relief, he suddenly noticed relocation of stimulation to his right flank, with an abrupt onset of 10/10 burning lower back pain radiating down both lateral thighs and accompanied by inability to lift his knees. The patient also exhibited neurological deficits and loss of rectal tone. The trial leads were immediately removed, and an MRI was performed. This showed an epidural or subdural fluid collection surrounding and compressing the thecal sac and spinal cord, extending from C7 to L3, which was interpreted as possibly a rapidly developing epidural hematoma. The epidural hematoma was a “thin spread” which was postulated as secondary to dislocation of the lead rather than trauma of the insertion. Epidural hematoma resolved rapidly, and no surgical intervention was required with full recovery.</p>	<p>This is another case of spinal cord trial stimulation causing epidural hematoma with full recovery. The authors noted that based on the retrospective analysis using a MAUDE database, the incidence of epidural hematoma was about 0.19%. Patient education regarding signs of this complication should be added to the preoperative discussion.</p>

Appendix Table 1 cont. *Reports of bleeding complications and epidural hematoma associated without antithrombotic therapy with interventional procedures.*

Study/Year	Case Report	Conclusions
<p>Smith et al, 2010 (158)</p> <p>Thoracic epidural hematoma</p> <p>Spinal cord stimulation trial</p>	<p>The authors reported 2 cases of epidural hematoma out of 4 complications related to spinal cord stimulations admitted to an acute spinal cord rehabilitation hospital over a 4-month period.</p> <ul style="list-style-type: none"> <li>The first patient with hematoma after placement of stimulator trial leads developed acute new mid back pain associated with rapid progressive weakness and motor loss to his bilateral lower extremities on day 5 associated with urinary retention. The pattern of weakness began in the right lower extremity and then progressed to the left lower extremity. A thoracic CT myelogram and CT of the thoracic spine with intrathecal contrast showed an epidural hematoma which extended 2 levels above the area of the spinal cord stimulator placement. The patient was not on any anticoagulants and all the studies were normal. On postoperative day 5, the patient underwent a thoracic T8/9 laminectomy with excision of epidural hematoma and removal of spinal cord stimulator electrodes. The patient developed permanent spinal cord injury.</li> <li>The second patient, a 66-year-old female with a history of chronic low back pain with stimulator leads placed in a patient with moderate to severe canal stenosis at L1/2 and L2/3 with epidural hematoma and air spanning T9- L2/3 and mass effect increasing the canal narrowing of the L1/2 and L2/3 levels. She underwent decompressive thoracic and lumbar laminectomies of T11-L2 levels. After acute inpatient rehabilitation stay, she recovered full motor strength in bilateral lower extremities. However, she was independent with limited community ambulation and had full bladder and bowel function recovery. She was diagnosed with spinal cord injury at T7.</li> </ul>	<ul style="list-style-type: none"> <li>Spinal cord hematoma developing after a trial without any risk factors. Recovery was poor after acute rehabilitation.</li> <li>Spinal cord hematoma developing after trial in a patient with severe spinal stenosis; however, without any antithrombotic therapy with moderate recovery after acute rehabilitation. The patient with spinal stenosis may become symptomatic and progress much faster than someone with a normal spine.</li> </ul>
<p>Roden et al, 2017 (203)</p> <p>Lumbar intrathecal hematoma</p> <p>Spinal cord stimulation lead placement</p>	<p>A 34-year-old man with a primary diagnosis of failed back surgery syndrome underwent percutaneous spinal cord stimulator lead placement. During the trial, the patient experienced paresthesia with initial right-side lead placement at T12-L1. The lead and needle were removed and placed at L1-2 where the patient did not report any problems. The patient reported right calf pain in the post-anesthesia care unit following the trial that improved with intravenous hydromorphone. However, following discharge the patient experienced worsening dysesthesia with edema of the right lower extremity to the calf. MRI of the lumbar spine confirmed the presence of blood products within the intrathecal space.</p>	<p>A few case reports discuss the occurrence of spinal epidural hematoma formation, but none present a case of an intrathecal bleed following percutaneous spinal cord stimulator lead placement. This case report highlights the need to further elucidate the incidence of neurologic sequelae after spinal cord stimulator placement.</p>
<b>ACUPUNCTURE</b>		
<p>Chen et al, 2006 (146)</p> <p>Cervical epidural hematoma</p> <p>Acupuncture</p>	<p>A 30-year-old male patient with upper back pain developed epidural hematoma from C7-T3 one hour after acupuncture. Patient underwent laminectomy with complete recovery.</p>	<p>Acupuncture may produce epidural hematoma.</p>
<p>Chen et al, 2020 (172)</p> <p>Cervical epidural hematoma</p> <p>Acupuncture</p>	<p>A 52-year-old male who denied taking any medication experienced soreness and acute onset of right-side weakness of the limbs, four hours after receiving acupuncture to treat a unilateral weakness of the limbs mimicking a stroke. CT angiography from the aortic arch to the head revealed a spinal epidural hematoma. The patient received conservative treatment and was discharged with subtle residual symptoms of arm soreness 5 days later.</p>	<p>Although rare, spinal epidural hematomas may develop from 1 hour to 1 week following acupuncture.</p>
<p>Domenicucci et al, 2017 (149)</p> <p>Spinal (C2-T12) epidural hematoma</p> <p>Acupuncture</p>	<p>A report of acute spinal epidural hematoma after acupuncture extending from C2 through T12. Due to rapid improvement with the patients' neurological symptoms, conservative treatment was adopted with excellent long-term results.</p>	<p>Acupuncture may produce epidural hematoma. Proper training is critical in this low-risk method.</p>

Appendix Table 1 cont. *Reports of bleeding complications and epidural hematoma associated without antithrombotic therapy with interventional procedures.*

<b>Study/Year</b>	<b>Case Report</b>	<b>Conclusions</b>
Keane et al, 1993 (153) Thoracic epidural hematoma Acupuncture	A case report of a 65-year-old female with development of epidural hematoma at T5-T6 several hours after acupuncture. Conservative management resulted in complete recovery.	Acupuncture may produce epidural hematoma. This case shows that competence in what is seen as low risk is a critical need, since unforeseen complications can arise from poor technique.
Chen et al, 1997 (160) Lumbar epidural hematoma Acupuncture	A case of a 48-year-old female developing epidural hematoma one week after acupuncture at L1-2. Patient was managed conservatively with complete recovery.	Acupuncture may produce epidural hematoma.
Eftekhari et al, 2005 (144) Lumbar epidural hematoma Acupuncture	A 74-year-old male patient developed epidural hematoma 2 days after acupuncture at L2-3. Patient underwent laminectomy with complete recovery.	Acupuncture may produce epidural hematoma.
Nam et al, 2010 (161) Lumbar epidural hematoma Acupuncture	A 60-year-old male patient with back pain developed epidural hematoma 5 days after acupuncture from L4-S1. Patient underwent laminectomy with complete recovery.	Acupuncture may produce epidural hematoma.
<b>CHIROPRACTIC</b>		
Lee et al, 2011 (142) Cervical epidural hematoma Dry needling	A 58-year-old woman presented with quadriplegia and neck pain after dry needling. MRI of the spine revealed a hyperintense mass in the T2 weighted at C2-T2 level, which proved to be an epidural hematoma. The diagnosis was made with an MRI and decompression was carried out. The patient recovered completely. There were no risk factors, and the patient was not on antiplatelet therapy.	The authors concluded the spinal hematoma caused by dry needling in this case was probably the result of unintentional needling of the spinal canal, similar to that caused by central neural blockade. Proper training in these novel methods is critical to reduce risks.
Berrigan et al, 2019 (94) Cervical epidural hematoma Dry needling	Cervical epidural hematoma was reported in a 62-year-old healthy female patient after dry needling in cervical and thoracic musculature. Patient developed neurological dysfunction leading to the diagnosis of cervical and thoracic epidural hematoma confirmed by MRI. Due to stable neurological function, surgical intervention was deferred. She was managed with conservative management without residual dysfunction.	Authors report an epidural hematoma with dry needling, which is considered as extremely unusual in a patient without risk factors or antiplatelet or anticoagulant therapy. This complication shows the importance of adherence to proper technique even in low-risk methods.

MRI: magnetic resonance imaging; CT: computed tomography; MAUDE: Manufacturer and User Facility Device Experience

Appendix Table 2. Reports of bleeding complications and epidural hematoma in patients after discontinuation of antiplatelet/ anticoagulant therapy during interventional procedures.

Study/Report	Antiplatelet / Anticoagulant	Number of Days Stopped Prior to Procedure	Case Report	Conclusion
<b>CERVICAL EPIDURAL</b>				
Reitman & Watters, 2002 (143)  Cervical epidural hematoma  Cervical interlaminar epidural injection	Aspirin (325 mg)	7 days	A 62-year-old woman underwent an uncomplicated cervical epidural steroid injection. She developed acute onset of axial pain followed by progressive quadriparesis within a matter of 8 hours. Emergency CT scan suggested posterior cord displacement consistent with an anterior spinal hematoma from C3 through C5. She was taken to the operating room and appropriate decompression was carried out showing anterior subdural hematoma. Patient continued to be quadriplegic, even though rapidly gained full function in the left upper and lower extremities. She developed acute meningitis and cardiac arrests and finally died.	Epidural hematoma can occur even after appropriate cessation of aspirin. Despite rapid diagnosis and surgical intervention, the outcome was bad in this case.
Benyamin et al, 2016 (88)  Cervical epidural hematoma  Cervical interlaminar epidural	Clopidogrel (Plavix)	12 days	Acute epidural hematoma formation was reported in the cervical spine after interlaminar epidural steroid injection despite discontinuation of clopidogrel for 12 days. Procedure was performed without difficulty between C7 and T1 under fluoroscopic guidance and contrast injection. The patient started complaining of severe pain immediately after transfer to the recovery area. The patient underwent an expedited cervical spine MRI identifying a large epidural hematoma which was surgically decompressed with full recovery. Patient was given 30 mg of ketorolac intramuscularly for pain.	Epidural hematoma occurred in a patient after stopping clopidogrel 12 days prior to the procedure. Ketorolac may contribute to exacerbation of hematoma. However, the patient was already significantly symptomatic prior to administration of ketorolac.
Manchikanti et al, 2017 (68)  Cervical epidural hematoma  Cervical interlaminar epidural injection	Aspirin (81 mg)	9 days	A case of cervical epidural hematoma in a 68-year-old Caucasian female patient was presented. Patient was on 81 mg of aspirin which was discontinued 9 days prior to the procedure. Following an uneventful cervical interlaminar epidural injection she developed symptomology with the diagnosis leading to epidural hematoma confirmed by MRI. She was managed conservatively with improving symptomatology and recovered completely.	Epidural hematoma occurred after the required period to discontinue aspirin. This patient had no other risk factors or other anticoagulant therapy. Patient was also successfully managed conservatively without surgical intervention.
Beasley & Goree, 2019 (179)  Cervical epidural hematoma  Cervical interlaminar epidural	Ibuprofen (400 mg twice daily), omega-3 fatty acids (2000 mg once daily)	24 hours (ibuprofen), however, omega-3 fatty acids taken morning of procedure	A 74-year-old female received a cervical interlaminar epidural steroid injection. 30 minutes later, she returned to the clinic with periscapular pain near the injection site and inability to extend her neck. MRI showed a large epidural hematoma extending from C6-T4 with mass effect at the C7-T1 level. 7 hours later, she received emergent epidural decompression, and was discharged on day 2.	This is the first report of cervical epidural hematoma in which the contralateral oblique technique was used. Also, this is the second report in which the combination of NSAIDs and omega-3 fatty acids may have contributed to increased hematoma risk. The contralateral oblique approach can result in this complication, in addition when physicians use a new view that is unfamiliar, additional views should also be utilized.

Appendix Table 2 cont. *Reports of bleeding complications and epidural hematoma in patients after discontinuation of antiplatelet/anticoagulant therapy during interventional procedures.*

Study/Report	Antiplatelet / Anticoagulant	Number of Days Stopped Prior to Procedure	Case Report	Conclusion
<b>THORACIC EPIDURAL</b>				
Swicegood et al, 2017 (65)  Thoracic epidural hematoma  Thoracic interlaminar epidural	Aspirin (81 mg)	7 days	Authors reported a thoracic epidural hematoma after interlaminar epidural injection in a patient on 81 mg aspirin therapy which was discontinued 7 days prior. Epidural injection was performed at T10-11 leading to symptomatology developing of neurological dysfunction within 2 hours. Surgical decompression was carried out with rapid recovery.	Epidural hematoma developed despite stopping low dose aspirin 81 mg within the required time of 7 days.
<b>LUMBAR EPIDURAL</b>				
Ain & Vance, 2005 (141)  Lumbar epidural hematoma  Lumbar interlaminar epidural injection	warfarin (Coumadin), enoxaparin (Lovenox)	warfarin was stopped for 6 days, and Enoxaparin was stopped for over 24 hours prior to the injection. INR was 1.2	A patient with renal insufficiency received an epidural injection at L3-L4 interspace. Enoxaparin regimen was reinstated 24 hours after the procedure. 48 hours after the procedure she reported 100 times worse back pain in the same location as before the epidural injection. MRI study showed severe central canal stenosis centered at L3-4 from a posterior epidural hematoma. Epidural hematoma extended from L2 through L4. Her anticoagulation regimen was discontinued and managed conservatively. The second day the patient experienced increased numbness and weakness in the lower extremities. Subsequent MRI revealed increasing size of the epidural hematoma extending from L1 to L5. Decompression laminectomies were performed from L2 to L4 and dexamethasone was given for 3 days.	Patient developed epidural hematoma after epidural injection despite strict adherence to the guidelines for neuraxial anesthesia and anticoagulation regarding administration of low molecular weight heparin.
Xu et al, 2009 (140)  Lumbar epidural hematoma  Lumbar interlaminar epidural	warfarin (Coumadin), aspirin, enoxaparin (Lovenox)	6 days and 24 hours before procedure  Warfarin and aspirin stopped 6 days before the procedure with bridging over to enoxaparin twice daily, with the last enoxaparin dose at least 24 hours before the procedure.	A 78-year-old woman underwent lumbar interlaminar epidural injection under fluoroscopic guidance. 30 hours after the 3rd lumbar interlaminar epidural injection, the following morning after the 2nd shot of enoxaparin, the patient developed excruciating radicular leg pain. CT scan of the lumbar spine was inconclusive. Subsequently, MR imaging of the lumbar spine showed a lumbar epidural hematoma that spanned from L2 to L5 causing severe thecal sac compression. She was treated with bilateral lumbar laminectomies, foraminotomies and hematoma evacuation from L2-L5. The patient had an unremarkable postoperative course. The epidural hematoma developed despite cessation of all drugs within the guidelines and restarting of enoxaparin within the guidelines.	Despite strict adherence to anticoagulation guidelines, epidural hematoma developed. This case also suggests that 6 days to stop aspirin may not be an appropriate amount of time.

Appendix Table 2 cont. *Reports of bleeding complications and epidural hematoma in patients after discontinuation of antiplatelet/ anticoagulant therapy during interventional procedures.*

Study/Report	Antiplatelet / Anticoagulant	Number of Days Stopped Prior to Procedure	Case Report	Conclusion
<p>Shanthanna &amp; Park, 2011, (133)</p> <p>Thoracic epidural hematoma</p> <p>Lumbar interlaminar epidural injection</p>	<p>warfarin (Coumadin)</p>	<p>Stopped for 4 days with an INR of 1.2 on the day of epidural injection</p>	<p>A 65-year-old male patient was treated with lumbar epidural injection at L3-4 in the sitting position with a second attempt which was atraumatic. Patient reported severe back pain and inability to stand 20 minutes after the procedure. An MRI scan performed within 3 hours of the patient's symptomatology revealed a localized dorsal/lateral thoracic epidural hematoma at T10 to T12. After neurosurgical referral, conservative management was provided with significant improvement within a day without having sustained any neurological deficit. An MRI done at the follow-up visit, a week later, showed a resolving hematoma.</p>	<p>Epidural hematoma developed after appropriate discontinuation of warfarin and ideal INR of 1.2 within 20 minutes after the epidural injection. Epidural injection was at L3-4 level; however, hematoma was at T10 to T12. Authors concluded that the situation calls for optimization of all the relevant patient factors including anticoagulant therapy, use of appropriate technique, and the appropriate imaging modalities. However, spinal stenosis has been described as a significant risk factor to develop epidural hematoma with epidural injections.</p>
<p>Caputo et al, 2013 (98)</p> <p>Lumbar epidural hematoma</p> <p>Lumbar interlaminar epidural</p>	<p>Dabigatran (Pradaxa)</p>	<p>7 days</p>	<p>A 70-year-old patient underwent lumbar interlaminar epidural injection under CT guidance at L4/5. Dabigatran was started 24 hours after the injection. The patient had complete resolution of the symptoms. 48 hours after the injection, the patient started developing numbness in both lower extremities and had nearly complete paraplegia of the bilateral lower extremities. An emergent MRI showed an acute stenotic lesion, which was not present on the previous MRI. The patient was immediately decompressed. The patient was treated with multiple units of packed red blood cells prior to decompression. On surgical exposure, there was a large hematoma from L3-L5. Surgical evacuation of the hematoma was carried out with full neurological recovery 6 months after surgery.</p>	<p>The authors concluded that there is no reversal protocol for dabigatran. Dabigatran was stopped 7 days prior, which is longer than recommended duration. However, it was started one day after the procedure, which seems to have resulted in hematoma formation.</p>

Appendix Table 2 cont. *Reports of bleeding complications and epidural hematoma in patients after discontinuation of antiplatelet/ anticoagulant therapy during interventional procedures.*

Study/Report	Antiplatelet / Anticoagulant	Number of Days Stopped Prior to Procedure	Case Report	Conclusion
<p>Page et al, 2016 (92)</p> <p>Lumbar epidural hematoma</p> <p>Lumbar interlaminar epidural</p>	<p>warfarin (Coumadin)</p>	<p>Discontinued 7 days earlier with preoperative INR of 1.0</p>	<p>This case report involves a 67-year-old woman undergoing interlaminar epidural injection with significant spinal stenosis at multiple levels undergoing interlaminar epidural injection with an #18-gauge Tuohy needle utilizing a paramedian approach with a single attempt. The patient developed weakness in legs the next day, 18 hours after the procedure. She had minimal relief with pain after the procedure. That evening around 11:30 pm, she was taken to the emergency room with weakness and inability to completely empty the bladder with an emergent MRI, which showed epidural hematoma from L3 to L5 with significant compression of the cauda equina. The patient underwent laminectomy within 4 hours of arrival to the emergency room. Total time from injection to the operating room was approximately 35 hours. She developed a permanent foot drop.</p>	<p>The authors described the presence of spinal stenosis and the interlaminar approach seem to be significant risk factors in this patient. The epidural hematoma developed despite discontinuation of warfarin 7 days before the surgery.</p>
<p>Lam et al, 2017 (71)</p> <p>Lumbar epidural hematoma</p> <p>Lumbar interlaminar epidural injection (T12-L1)</p>	<p>Aspirin 81 mg</p>	<p>Discontinued 14 days</p>	<p>A 76-year-old woman with mild lumbar spinal stenosis (L4-L5, L5-S1) and lumbar dextroscoliosis, previously on 81mg of aspirin daily (discontinued at 14 days prior to procedure) and not on anticoagulation therapy, underwent a lumbar epidural steroid injection (T12-L1). Post-procedurally, she developed bilateral leg paralysis. MRI study revealed a fluid collection concerning hematoma. Neurosurgery was consulted, but at the time of evaluation, she had near resolution of her presenting symptoms and the decision was made to monitor her for 48 hours. Three months after discharge, MRI revealed no persistent symptoms or radiographic evidence of sequelae from epidural hematoma.</p>	<p>The frequency of spinal epidural hematomas after epidural steroid injections is unknown. This patient did not have traditional risk factors of severe spinal stenosis or the use of anticoagulant or antiplatelet agents. A radiographic fluid collection was seen, which may represent blood or persistent injectate. A formal surgical diagnosis was not obtained, as her symptoms spontaneously improved without further need for intervention.</p>
<p>Kim et al, 2018 (69)</p> <p>Lumbar epidural hematoma</p> <p>Lumbar interlaminar epidural injection</p>	<p>Clopidogrel (Plavix), aspirin, and beraprost</p>	<p>7 days</p>	<p>Authors reported a lumbar epidural hematoma with late onset, 3 weeks after the performance of epidural steroid injection in a patient with spinal stenosis at L4-5 interspace. Patient was on clopidogrel, aspirin, and Beraprost following infrarenal abdominal aortic aneurysm repair. Clopidogrel and aspirin were stopped 7 days prior to the epidural injection. Symptomatology developed 3 weeks after the epidural injection with formation of a large hematoma to cause severe thecal compression. Patient was managed conservatively without residual complications.</p>	<p>Epidural hematoma with late onset 3 weeks after the procedure in a patient after withholding appropriately clopidogrel and aspirin for 7 days. The authors also identified spinal stenosis as a contributing risk factor.</p>



Appendix Table 2 cont. *Reports of bleeding complications and epidural hematoma in patients after discontinuation of antiplatelet/ anticoagulant therapy during interventional procedures.*

Study/Report	Antiplatelet / Anticoagulant	Number of Days Stopped Prior to Procedure	Case Report	Conclusion
<p>Kim et al, 2021 (180)</p> <p>CASE #1 Epidural hematoma (T11-L5)</p> <p>Lumbar transforaminal epidural</p>	<p>Aspirin (81 mg)</p>	<p>5 days</p>	<p>The authors reported 2 cases. The first patient, an 89-year-old female was diagnosed with lumbar spinal stenosis with bulging of the L2-L5 intervertebral discs for which she received transforaminal epidural steroid injection. 24 hours after the procedure, she complained of severe lower back pain and subjective weakness in the left leg. A lumbar spine MRI showed a 14-centimeter epidural hematoma extending from the T11 to the L5 level with cord compression at T11-12-L1-4. It was treated with epidural blood aspiration.</p>	<p>Acute, large amounts of epidural hematoma without neurological deficits developed after transforaminal epidural steroid injection, in a patient who discontinued aspirin.</p>
<p>CASE #2 Thoraco-lumbar epidural hematoma</p> <p>Lumbar transforaminal epidural</p>	<p>Ginko</p>	<p>She agreed to stop taking ginko during her visit for treatment”</p>	<p>The second patient, an 86-year-old female with moderate spinal stenosis in the L2-L5 region received a transforaminal epidural steroid injection. She continuously complained of pain, and an MRI performed within 3 hours revealed a large amount of epidural and subdural hematoma at the lower T-L spines and sacrum with cord compression at the T spine. Non-surgical aspiration was performed 3 hours after the procedure.</p>	<p>Acute, large amounts of epidural hematoma without neurological deficits developed after transforaminal epidural steroid injection, in a patient who discontinued ginkgo. The team should be aware of the impacts of nontraditional herbs and medications. Since these agents do not undergo the Food and Drug Administration (FDA) approval process many potential issues may be unknown at the time of use.</p> <p>The guideline author (BJS) reviewed, both of these cases. He comments that these were attempted to be transforaminal epidural steroid injection. However, based on the provided images it is highly unlikely that transforaminal epidural steroid injection was performed properly since both contrast patterns show the needle tip being placed too far medially and the contrast pattern in both cases appears to be intrathecal – complications from incorrectly performed procedures are unique from complications that occur when proper technique is used. Nonetheless the injection itself was likely intrathecal.</p> <p>The only feasible explanation that there was bleeding complication in the epidural space while entering the intrathecal space; however, since the needle entry site may be too small to cause the bleeding to spread to intrathecal space.</p> <p>Overall conclusion is that the transforaminal epidural does not appear to be the culprit in these 2 cases, similar to the other cases described above.</p>

Appendix Table 2 cont. *Reports of bleeding complications and epidural hematoma in patients after discontinuation of antiplatelet/ anticoagulant therapy during interventional procedures.*

Study/Report	Antiplatelet / Anticoagulant	Number of Days Stopped Prior to Procedure	Case Report	Conclusion
<b>SPINAL CORD STIMULATION</b>				
<p>Fan et al, 2022 (195)</p> <p>Thoracic epidural hematoma</p> <p>Spinal cord stimulation lead placement C1-C5</p>	<p>warfarin (Coumadin)</p> <p>Bridging therapy</p>	<p>warfarin was stopped prior to surgery and changed to low molecular weight heparin for 9 days</p>	<p>A 64-year-old male patient with post herpetic neuralgia after cardiovascular surgery, with history of long-term oral administration of warfarin underwent spinal cord stimulation lead placement.</p> <p>Patient was on warfarin, which was stopped prior to surgery and changed to low molecular weight heparin for 9 days. INR was 0.95 and spinal cord stimulator leads were positioned successfully at C1-C5 level in the epidural space. Immediately following the surgery, the patient reported pain in his back and weak lower limb muscle strength. An MRI showed a large epidural hematoma. Even though he improved temporarily, subsequently, he deteriorated. Following this, he underwent hemi-laminectomy at T2-T6 with appropriate recovery.</p>	<p>This case report shows bridging therapy has not helped. In any case, it appears there was acute profuse bleeding immediately.</p> <p>Warfarin therapy with bridging of heparin has been a major issue of controversy. In recent years, all cardiology guidelines recommend bridging therapy.</p>
<p>Chiravuri et al, 2008 (139)</p> <p>Cervical intracranial subdural hematoma</p> <p>Spinal cord stimulation trial</p>	<p>Clopidogrel (Plavix)</p>	<p>10 days</p>	<p>This is a case report in a 49-year-old male for placement of spinal cord stimulation trial leads for chest pain. Leads were attempted to be placed at L1-L2 with Tuohy needle under live fluoroscopic guidance contacting the L2 lamina with loss of resistance technique to the air. Subarachnoid puncture was noted with clear fluid flowing freely from the Tuohy needle. The needle was withdrawn into the epidural space and a spinal lead advanced to mid C7. Postoperatively patient reported a positional headache accompanied by nausea and vomiting. This progressively worsened over the course of the day, changing in character with loss of positional component accompanied by emesis. His CT scan of the head showed a large subdural hematoma. Neurosurgical consultation was carried out and the patient underwent emergency craniotomy. The remaining post-surgical course was uneventful; however, on the postoperative day 3 patient recalled falling at home one day prior to the spinal cord stimulator implant, striking his head without loss of consciousness.</p>	<p>Even though this case presents acute intracranial subdural hematoma secondary to unintentional dural puncture during placement of permanent spinal cord stimulator lead, it also raises questions in reference to the causal relationship of the procedure and development as there was history of a fall. Even then, there is need for careful follow-up of patients with a known post dural tear. Failure to identify uncommon adverse events in patients with complicated spinal cord stimulator implantation may lead to permanent injury.</p>

Appendix Table 2 cont. *Reports of bleeding complications and epidural hematoma in patients after discontinuation of antiplatelet/ anticoagulant therapy during interventional procedures.*

<b>Study/Report</b>	<b>Antiplatelet / Anticoagulant</b>	<b>Number of Days Stopped Prior to Procedure</b>	<b>Case Report</b>	<b>Conclusion</b>
<p>Giberson et al, 2014 (91)</p> <p>Thoracic epidural hematoma</p> <p>spinal cord stimulation trial</p>	<p>Aspirin (81 mg) and other NSAIDs</p>	<p>One week</p>	<p>This is a case report of a 70-year-old patient undergoing spinal cord stimulator trial lead placement. He discontinued low dose aspirin 81 mg and other NSAIDs one week before the trial. After the removal of the trial after 4 days, the patient developed acute onset of burning lower thoracic pain and lower extremity weakness and spasms. An emergent MRI image revealed epidural hematoma extending from T8 to L3 with significant cord compression. The patient underwent an emergent T8 to T11 laminectomy and evacuation of the hematoma. He had complete resolution of his symptoms and was discharged home in good condition.</p>	<p>The authors reported, along with this case, another case where the patient took aspirin the day of the removal of the leads and developed hematoma. Consequently, they concluded aspirin must be discontinued. However, it is puzzling that this patient was on aspirin; however, he discontinued 7 days prior to the procedure. This suggests in some patients the time of effect of the aspirin may be unpredictable.</p>

NSAIDs: non-steroidal anti-inflammatory drugs; MRI: magnetic resonance imaging; INR: international normalized ratio; CT: computed tomography

Appendix Table 3. Reports assessing bleeding complications and epidural hematomas in patients with continuation of antiplatelet therapy or drugs potentially increase bleeding with interventional procedures.

Study/Report	Antiplatelet/ Anticoagulant	Case Report	Conclusions
<b>CERVICAL EPIDURAL</b>			
Williams et al, 1990 (134)  Cervical epidural hematoma  Cervical interlaminar epidural injection	Indomethacin	A diagnosis of cervical epidural hematoma was made and was confirmed by CT scan after a seventh epidural at C7/ T1 in several years in a patient who was taking indomethacin. Immediate surgery revealed an epidural hematoma. During the operation blood results became available showing that INR was 1.0, the clotting time was 41 seconds with a control of 40 seconds, and the platelet count was within normal limits. Bleeding time was not measured. His recovery was complicated with wound breakdown requiring a skin graft and urinary retention which required prostatectomy. Subsequently he made a full recovery.	Authors concluded that repeated epidural steroid injections should preferably be performed in centers equipped to accurately diagnose and promptly treat this rare but serious complication. This conclusion has not been substantiated in prospective work.
Benzon et al, 1999 (152)  Cervical epidural hematoma  Cervical interlaminar epidural injection	Clopidogrel (Plavix), possibly aspirin	This case report describes a patient with acute onset of quadriplegia admitted to a teaching hospital with a large cervical epidural hematoma, developing numbness and weakness of his arms and legs within 30 minutes after the performance of the cervical epidural steroid injection. At the time of injection, he was taking clopidogrel, possibly aspirin, and diclofenac that had been started after a prior coronary angioplasty. He also had a prior uneventful cervical epidural steroid injection 11 days before the incident in question, but it is not clear if he was taking these antiplatelet drugs then. His PT, INR, and PPT were within normal limits. His platelet count was appropriate. The last doses of antiplatelet drugs were unclear. He underwent an emergency C3-T3 laminectomy and evacuation of cervical epidural hematoma. Approximately 14 hours after the epidural injection postoperatively upper extremity strength improved, but his lower extremities remained paralyzed. Three months after the surgery he had regained his strength in his upper extremities, but the paralysis of his lower extremities remained.	The authors of this case report cautioned that these drugs inhibit platelet adhesion to the vascular endothelium and shear stress-induced platelet aggregation and section. After discontinuation of clopidogrel therapy, platelet aggregation and bleeding time returned to baseline within 5 days. Authors stated that there has been no case report of spinal hematoma after neuraxial block in patients receiving clopidogrel; however, there was a case report with ticlopidine. They recommended that neuraxial blocks be postponed for 5 – 7 days in patients who are receiving several antiplatelet drugs.
Chien et al, 2014 (90)  C5-T7 epidural hematoma  Cervical interlaminar epidural injection	Ketorolac (Toradol), fluoxetine (Prozac Sarafem), fish oil, and vitamin E	A 66-year-old woman with chronic renal insufficiency and neck pain due to multi-level neuroforaminal stenosis and degenerative intervertebral discs and on Ketorolac, fluoxetine, fish oil, and vitamin E was treated with cervical interlaminar epidural steroid injection. Utilizing a loss of resistance to saline technique, an 18-gauge Tuohy-type needle entered the epidural space at C6-7. After negative aspiration, 4 mL of saline with 80 mg of methylprednisolone was injected. Immediately thereafter, the patient reported significant spasmodic-type localized neck pain without any neurologic status changes, and it was treated with 30mg ketorolac injection. Later, she developed a sudden onset of acute tetraplegia. An emergent MRI in ED demonstrated an epidural hematoma extending from C5 to T7 and coagulation studies were normal. She underwent a bilateral C5-T6 laminectomy with epidural hematoma evacuation and was discharged to an acute inpatient rehabilitation hospital. She had permanent lower extremity paralysis with bladder dysfunction.	Combined antiplatelet effects of ketorolac, fluoxetine, fish oil, and vitamin E may have played a role in compromised hemostasis in this patient. Using a smaller blunt needle may also decrease the incidence of epidural hematoma, in theory, although this has never been proven in prospective evidence. In addition, the role of high dose fish oil in bleeding should be considered in the perioperative period.
Swicegood et al, 2017 (66)  Cervical epidural hematoma  Cervical interlaminar epidural injection	Aspirin	Author reported a case of cervical epidural hematoma in a 76-year-old Caucasian male patient receiving low dose aspirin, 81 mg, and Vitamin D3. Aspirin continued. Patient also had multiple arthritic changes in the cervical spine with moderate canal stenosis and bilateral foraminal narrowing. Patient developed symptomatology leading to the diagnosis of epidural hematoma which required surgical decompression. Patient recovered without residual dysfunction; however, the patient was also administered with 30 mg of intravenous ketorolac which may have contributed to the epidural hematoma.	Authors describe that epidural hematoma may occur with low dose aspirin therapy; however, authors also emphasized on the importance of risk factors related to the anatomical factors.

Appendix Table 3 cont. *Reports assessing bleeding complications and epidural hematomas in patients with continuation of antiplatelet therapy or drugs potentially increase bleeding with interventional procedures.*

Study/Report	Antiplatelet/ Anticoagulant	Case Report	Conclusions
<p>Jenkie et al, 2017 (67)</p> <p>Cervical epidural hematoma</p> <p>Cervical interlaminar epidural injection</p>	<p>Fish oil</p>	<p>A 49-year-old woman with a history of moderate spinal stenosis in the cervical area underwent cervical epidural injection. Two years prior, she had an anterior cervical disc fusion at C5-C6 for significant C6 radiculopathy and had subsequently developed disc herniations above and below the level of fusion. After the procedure and the development of symptoms, a cervical MRI showed a 7 mm epidural hemorrhage extending superiorly to the C2-C3 level and inferiorly to the T4 level. The majority of the hemorrhage was at the C6-C7 level associated with moderate cervical stenosis due to a cervical disc herniation at that same level. She underwent emergent surgical decompression and evacuation of the hematoma through multiple laminectomies at C6, C7, and T1. The patient had immediate relief of her symptoms and regained her wrist strength.</p>	<p>The authors concluded the need to evaluate fish oil as a predisposition to patients with bleeding complications when used in higher doses. In addition, the dose of fish oil may have an impact on bleeding.</p>
<p>Petro et al, 2018 (191)</p> <p>Cervical epidural hematoma</p> <p>Cervical interlaminar epidural</p>	<p>Aspirin 81 mg</p>	<p>A 65-year-old male with a history of chronic neck pain with radiculopathy secondary to multilevel cervical spondylosis and associated foraminal stenosis. He had been taking prophylactic aspirin 81 mg with no other anticoagulant or anti-inflammatory therapy. He had undergone multiple cervical interlaminar epidural injections over the past 2 years. The procedure was with loss of resistance. However, contrast spread was restricted to the dorsal epidural space. There were no issues with bleeding or ecchymosis.</p> <p>The day after the procedure, the patient complained of increased neck pain and presented it to the emergency department for evaluation. They found a 2 cm ecchymosis at the site of the injection without erythema or induration. His motor exam demonstrated 4x5 strength on the right side and 5x5 strength on the left side. MRI showed C6/7 and T1/2 epidural fluid collections.</p> <p>He was admitted to the intensive care unit and was monitored. He started improving. Hematoma was confirmed; however, because of the improvement, no surgery was performed.</p>	<p>This shows a patient on 81 mg of aspirin, which was continued throughout the procedure, resulted in epidural hematoma, which resolved spontaneously.</p>
<p>Mehta, 2019 (183)</p> <p>Subarachnoid hemorrhage, subdural hemorrhage, and intraventricular hemorrhage</p> <p>Cervical interlaminar epidural injection</p>	<p>Aspirin (81 mg) daily</p>	<p>An 88-year-old female presented with a headache following cervical epidural steroid injections. CT scan of her brain showed pneumocephaly, subdural hemorrhage, subarachnoid hemorrhage, and intraventricular hemorrhage. She was treated with nimodipine. 4 days after the procedure, a repeat brain CT showed resolution of pneumocephaly and intracranial hemorrhage.</p>	<p>The authors describe a case of subarachnoid hemorrhage, subdural hemorrhage, and pneumocephaly following cervical epidural injection, in a patient taking aspirin.</p>
<p>Beasley &amp; Goree, 2019 (179)</p> <p>Cervical epidural hematoma</p> <p>Cervical interlaminar epidural</p>	<p>Omega-3 fatty acids continued. However, 400 mg Ibuprofen, bid, was discontinued 24 hours prior to the procedure.</p>	<p>A 74-year-old woman returned to the pain clinic, within 15 min of discharge, after an apparent uncomplicated cervical ILESJ using the contralateral oblique technique with severe periscapular pain and muscle spasms. Cervical MRI showed a large epidural hematoma which was subsequently emergently evacuated.</p>	<p>To the authors' knowledge, this is the first reported case of cervical epidural hematoma in which the contralateral oblique technique was used. Also, this is the second case in which the combination of non-steroidal anti-inflammatory medications and omega-3 fatty acids has been considered as a contributor to increased hematoma risk. This case underscores the risk of epidural hematoma using a novel fluoroscopic technique and the need for potential discontinuation of supplements like omega-3 fatty acids.</p>

Appendix Table 3 cont. *Reports assessing bleeding complications and epidural hematomas in patients with continuation of antiplatelet therapy or drugs potentially increase bleeding with interventional procedures.*

Study/Report	Antiplatelet/ Anticoagulant	Case Report	Conclusions
Cho et al, 2021 (181)  Cervical epidural hematoma  Cervical transforaminal epidural	Aspirin, clopidogrel	A 55-year-old male presented with right-sided weakness and contralateral loss of pain and temperature sensation after a cervical epidural injection for shoulder pain. Cervical spine MRI showed an epidural hematoma from C4 to C6. After admission, his right hemiparesis and contralateral sensory loss improved within 8 days, and surgical decompression was not required.	In this patient taking aspirin and clopidogrel, a potential spinal lesion following cervical epidural injection may have caused the epidural hematoma with Brown-Sequard syndrome.
<b>LUMBAR EPIDURAL</b>			
Sanders et al, 2018 (93)  Lumbar epidural hematoma  Lumbar interlaminar epidural	Aspirin	A 79-year-old man developed an epidural hematoma requiring surgical treatment following an uncomplicated interlaminar epidural steroid injection performed for neurogenic claudication. In the periprocedural period, he continued aspirin for secondary prophylaxis following a myocardial infarction.	Both ASIPP and ASRA guidelines recommend holding aspirin at least 5 days. Thus, cases such as this serve to highlight the importance of giving careful consideration to medical optimization of a patient even when a low- or intermediate-risk procedure is planned.
Karri et al, 2020 (190)  Lumbar epidural hematoma  Lumbar interlaminar epidural	Aspirin, Duloxetine (Cymbalta)	A 70-year-old female with numerous cardiovascular comorbidities (on aspirin 81 mg daily for primary prevention of coronary artery disease) and fibromyalgia (on duloxetine 60 mg daily) underwent a fluoroscopically guided L3-L4 level interlaminar epidural steroid injection for lumbar radiculopathy. Starting 6 hours post-procedure, the patient started to manifest severe back pain, bowel and bladder incontinence, and paraplegia. MRI of the thoracic and lumbar revealed a large epidural fluid collection compressing the spinal cord and cauda equina. Unfortunately, a delay in care prevented the patient from receiving neurosurgical decompression.	Serotonin reuptake inhibitors associated with coagulopathy may predispose to epidural hematoma formation by diminishing platelet aggregation. Therefore, weaning these medications, as dictated by the latest guidelines, should be highly considered, if possible and reasonable, to ensure favorable safety profiles for epidural steroid injection procedures, especially in persons with multiple risk factors. Regardless of appropriate strategies to mitigate epidural steroid injection associated bleeding risks, proceduralists should always maintain a healthy index of suspicion for epidural hematoma formation in the post-procedural phase as early diagnosis and intervention may prevent devastating neurological outcomes.
<b>CAUDAL EPIDURAL</b>			
Choi et al, 2017 (154)  Lumbar epidural hematoma  Caudal epidural injection	Cilostazol (Pletal)	This is a case report of a patient undergoing caudal epidural injection for spinal stenosis on cilostazol. Three days after the caudal injection, the patient developed severe burning pain radiating into both hips and difficulty standing. The patient's symptoms started 6 hours after the caudal injection and worsened with time. An MRI showed epidural hematoma with acute cord compression at L2 through S1 with concomitant central canal compromise, severe at L2/3 and L3/4 levels. Emergency decompressive laminectomy and evacuation of the hematoma was performed uneventfully over 4 hours. Patient made a full recovery.	This is probably the first case report of epidural hematoma following a caudal epidural injection. Multiple guidelines have recommended that Cilostazol need not be stopped prior to the spinal procedures. Spinal stenosis has been reported as a major risk factor; however, this procedure was performed caudally avoiding such risk. Cilostazol, combined with aspirin, did not prolong bleeding time above significant increase of bleeding time caused by aspirin alone or clopidogrel.

Appendix Table 3 cont. *Reports assessing bleeding complications and epidural hematomas in patients with continuation of antiplatelet therapy or drugs potentially increase bleeding with interventional procedures.*

Study/Report	Antiplatelet/ Anticoagulant	Case Report	Conclusions
<b>SACROILIAC JOINT INJECTION</b>			
Menezes et al, 2021 (204)  Hematoma over right gluteus  Right sacroiliac joint injection	warfarin (Coumadin) 5 mg daily, aspirin 81 mg daily	A 61-year-old woman with sacroiliac joint arthropathy was treated with bilateral sacroiliac joint injections. She had extensive medical history with significant atrial fibrillation, stroke, coronary artery disease, diabetes mellitus, rheumatoid artery disease, fibromyalgia, and post laminectomy syndrome. She was on 5 mg of warfarin daily and 81 mg of aspirin daily.  Bilateral sacroiliac joint injections were performed under fluoroscopic guidance.  One day after the procedure, she presented to the clinic with a large 7.8 x 5.4 cm intramuscular hematoma in the gluteus maximus muscle, following which she underwent surgery, and the hematoma was drained.	Even though this is not an epidural hematoma, it has led to surgical intervention and drainage. Consequently, large extra-epidural hematomas can be problematic in some patients.
<b>SPINAL CORD STIMULATION</b>			
Giberson et al, 2014 (91)  T5-L2 epidural hematoma  Spinal cord stimulation trial	Excedrin (acetaminophen, aspirin, and caffeine) taken on the morning of removal of the trial	This is a case report of a 53-year-old man with trial leads placed with good pain relief. The patient had a successful trial and removal of trial leads without any problems except for there was some bleeding at the exit site, which stopped with local pressure. At this time, the patient reported that he took Excedrin the morning before the removal of the trial leads. The patient reported immediate difficulty, which was diagnosed as epidural hematoma from T5-L2 with spinal cord compression. The patient was treated with surgical intervention 2 days after admission with development of permanent weakness in his left leg. It appears the patient has taken aspirin that morning. The patient took aspirin on the same day when the leads were removed. Time to peak effect of aspirin is less than 1 hour with plasma half-life of 30 minutes.	The authors concluded that aspirin taken on the day of insertion of the leads or removal of the leads can be dangerous. Avoiding any factors that could impact bleeding until the trial leads are removed is recommended.
Buvanendran & Young, 2014 (89)  Thoracic epidural hematoma  Spinal cord stimulation trial	Aspirin	71-year-old woman with post-laminectomy syndrome presented for spinal cord stimulation trial. Patient had multiple medical problems and was taking Aspirin 81mg daily until the procedure day. Two 14-gauge introducer needles were placed with a single atraumatic pass via a paramedian approach toward the T12 to L1 interspace. 2 cylindrical octet electrodes were advanced into the dorsal epidural space with the aid of fluoroscopy. The next morning, the patient experienced severe bilateral lower extremity pain, so the leads were removed, and she subsequently developed lower extremity weakness. Emergent MRI showed T2-T10 epidural hematoma, and she underwent surgery within 7 hours of symptoms onset. Patient did well post-operatively and regained her baseline functions.	The decision to consider discontinuing baby aspirin should be weighed against the risk of vascular events. In the setting of continuing baby aspirin, the patient and medical team should be aware of the increased risks of bleeding.
<b>KYPHOPLASTY</b>			
Zou et al, 2020 (184)  T12-L1 epidural hematoma  L1 percutaneous kyphoplasty	Aspirin - 100 mg/daily, clopidogrel (Plavix) - 75 mg/daily	A 64-year-old female with long-term oral antiplatelet drug use, though normal PT and activated PTT, underwent the L1 percutaneous kyphoplasty for severe back pain due to L1 and L2 compression fracture. 12 hours later, she developed progressive weakness of the bilateral lower limbs. An emergency MRI spinal cord compression from T12 to L1. The spinal epidural hematoma was verified and removed during the laminectomy from T12-L1. Following the decompression surgery, the neurological deficit improved.	For a patient with long-term oral antiplatelet drugs or coagulation malfunction, the transpedicle approach or that via the costovertebral joint with a smaller abduction angle is recommended to reduce the risk of injury to the inner wall of the pedicle.

ASIPP: American Society of Interventional Pain Physicians; ASRA: American Society of Regional Anesthesia; MRI: magnetic resonance imaging; CT: computed tomography; INR: international normalized ratio; PT: prothrombin time; PPT: partial thromboplastin time; ED: emergency department; ILES: interlaminar epidural steroid injection